

AOASM 20206 Snap Decisions in The Athletic Training Room

Billy Thompson MD
Samaritan Health Care



1

Disclosures


2



3



4



5

Building Your Training Room Team



6



7



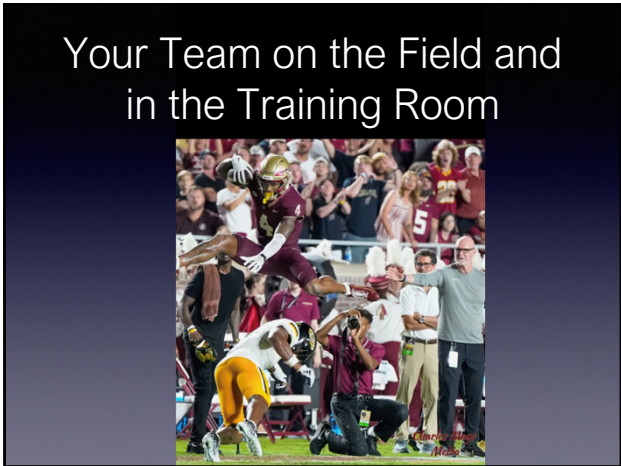8



9




10



11



12



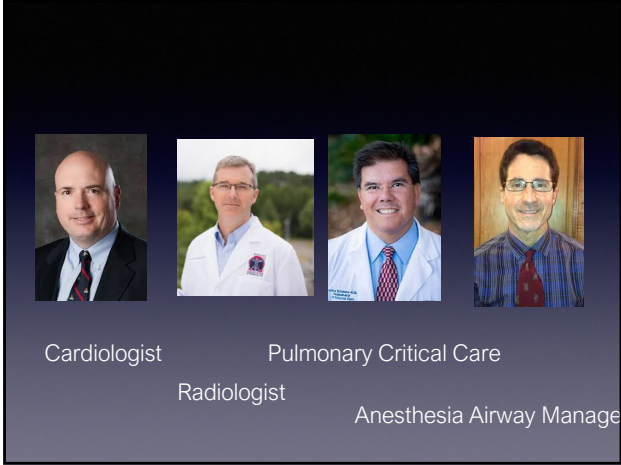
13



14



15



16



17




18

Trust and Confidence



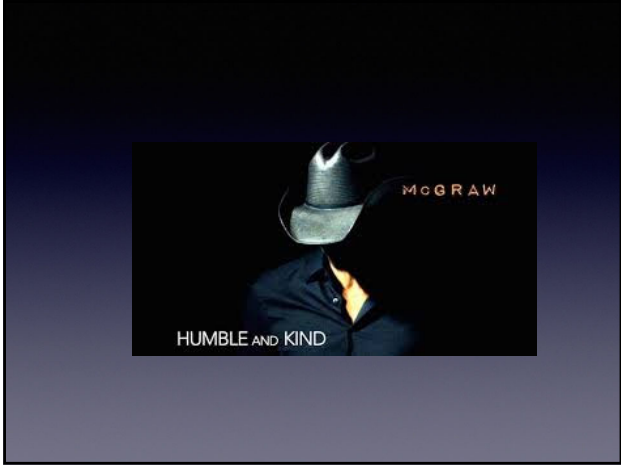
19



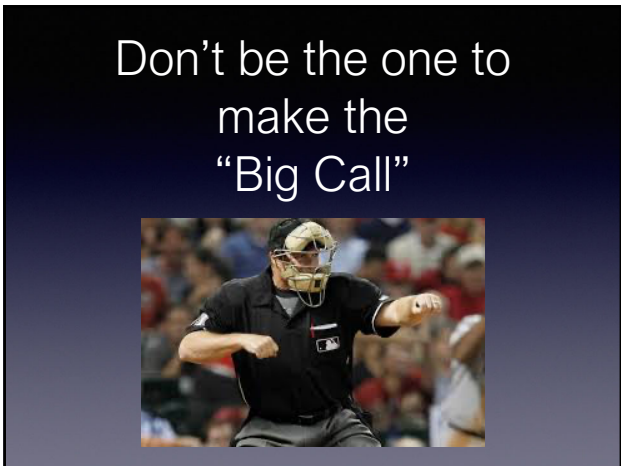20

Training Room Rules

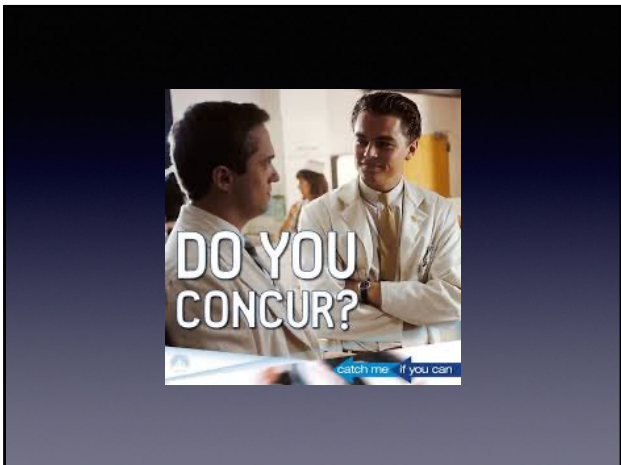
21




22



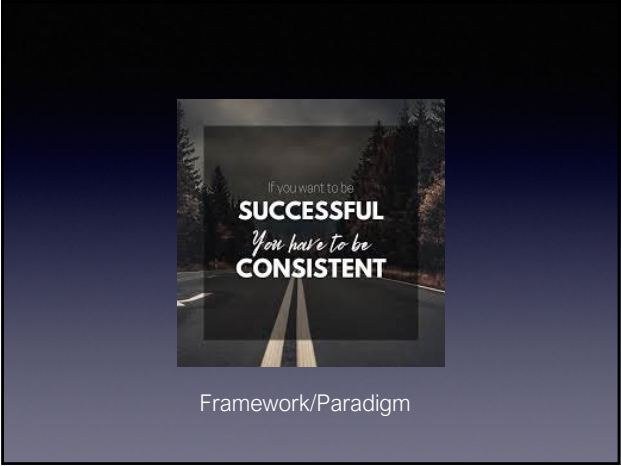23



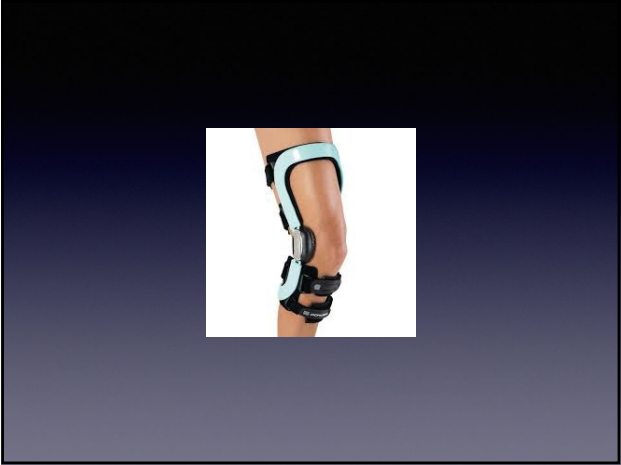24



25

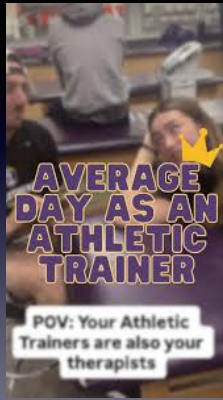

26



27

Gossip



28

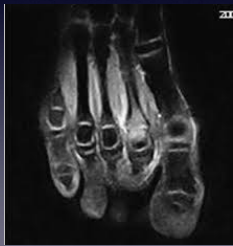Gather as much info as you can before seeing Athlete

29

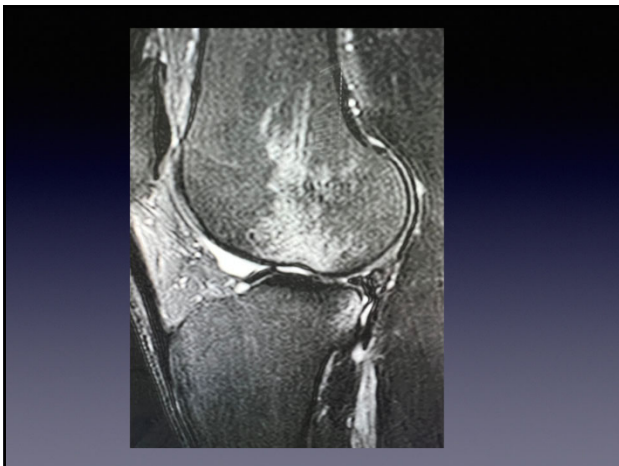

30

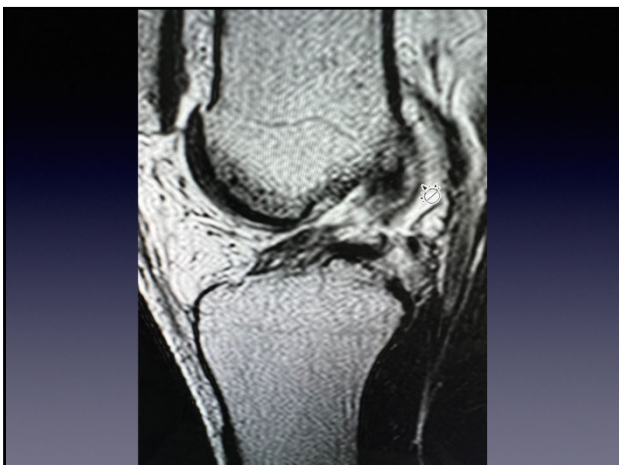MRI STIR Images



31



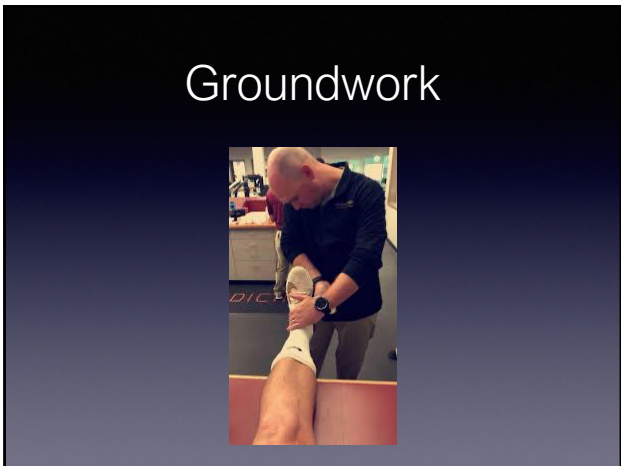32



33



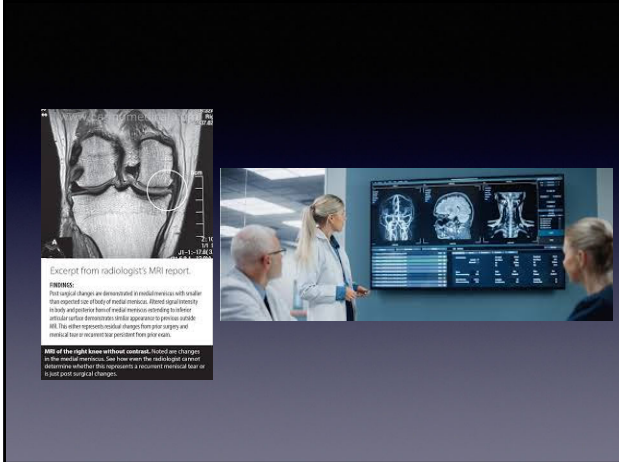
34




35



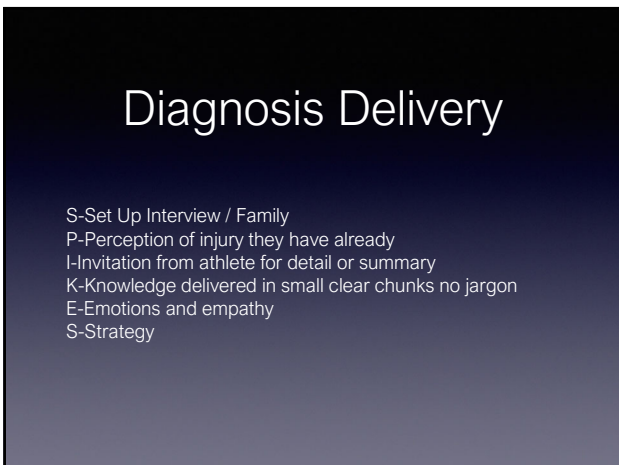
36



37



38



39

Cases



40

Catastrophic



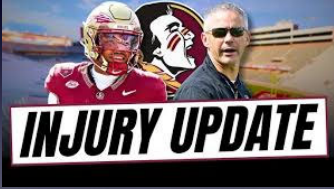41

Binary Decisions



42

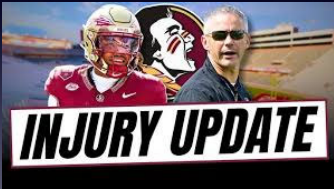Binary Decisions



Play or Not ?

43

Binary Decisions



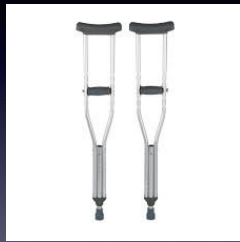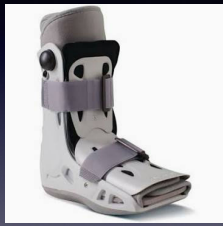When can they return ?

44




Lower Extremity

45



Unweight to no pain

46



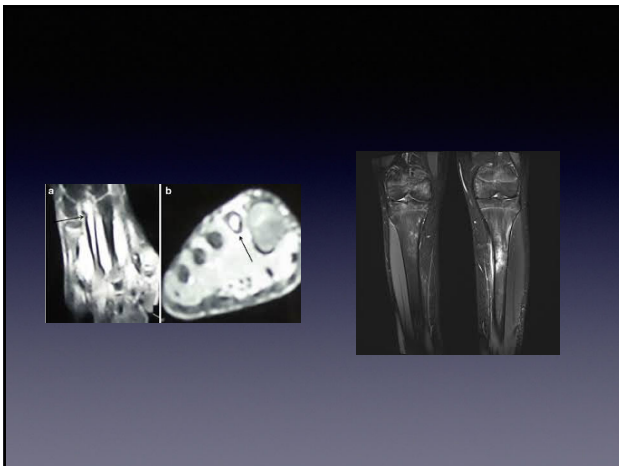
47



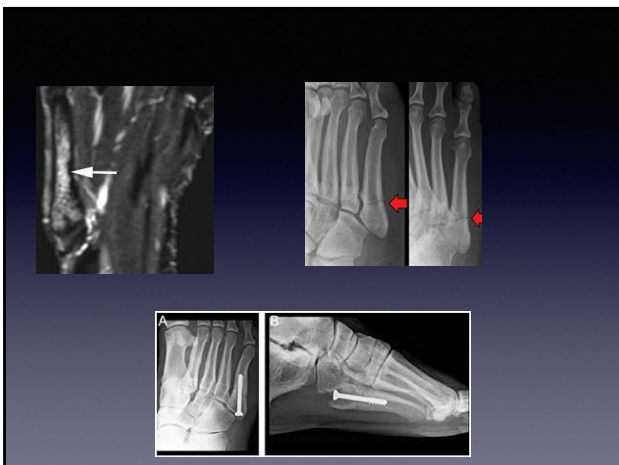48

Rapid Fire Cases

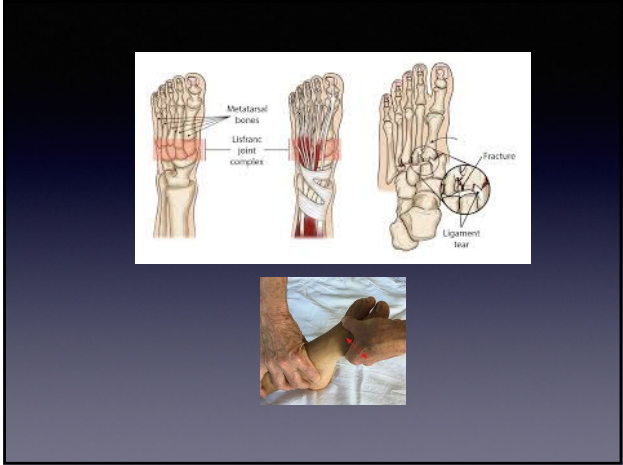
49



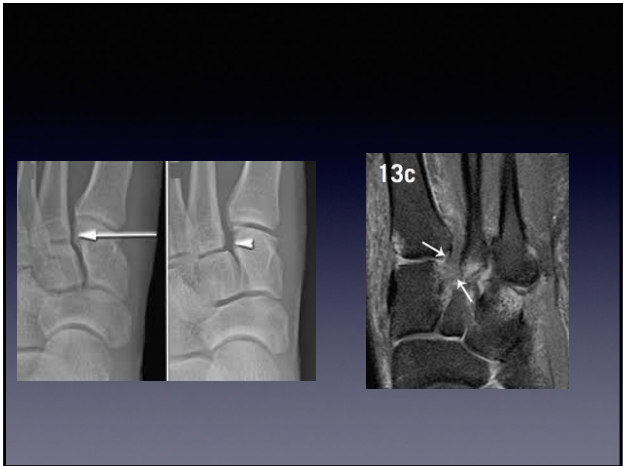
50



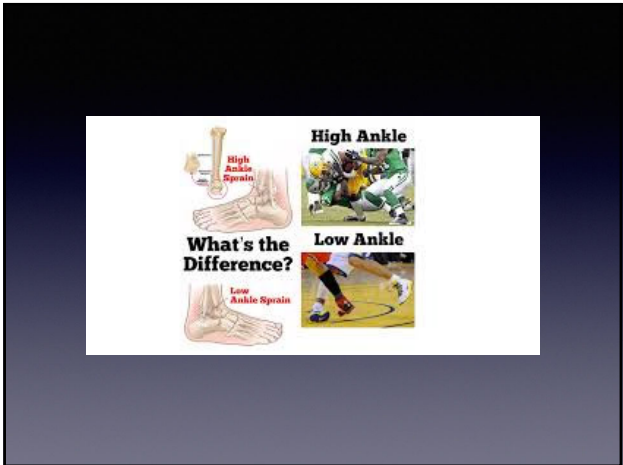
51



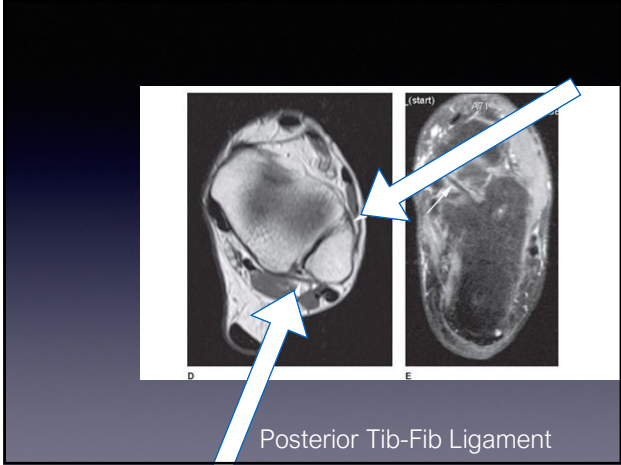
52



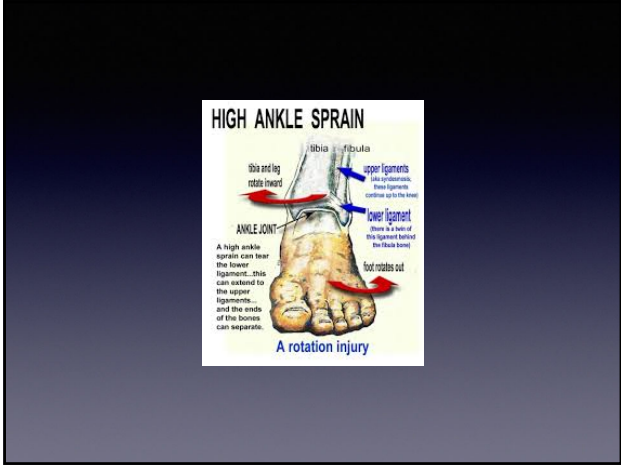
53



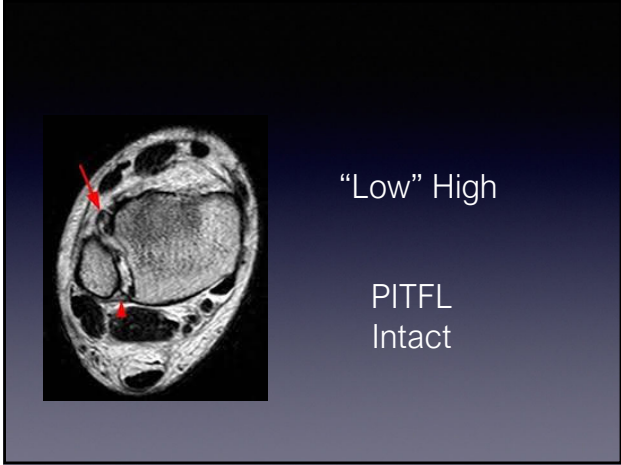
54



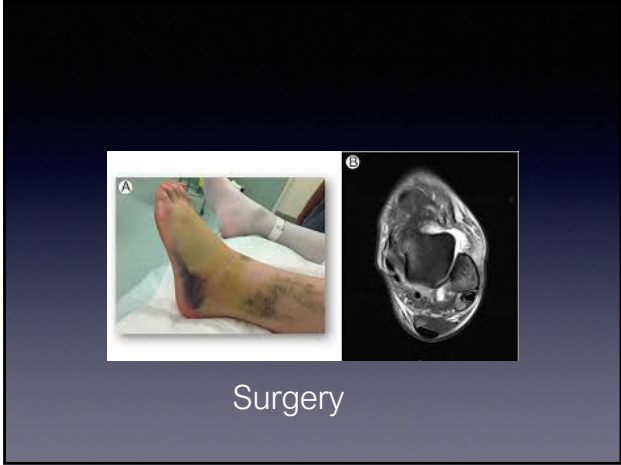55



56



57



Surgery

58

Hamstring

Ahmad et al
 "Evaluation and management of hamstring injuries."
 The American journal of sports medicine.
 2013 Dec; 41(12):2933-47

59

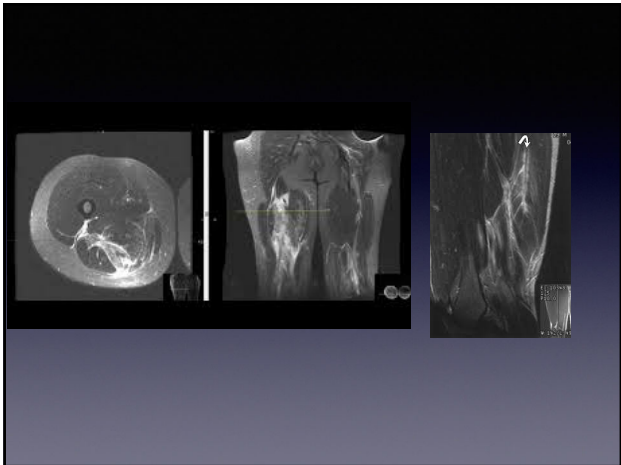
Table 2. MRI scoring system.

Points	Age, y	Muscles Involved, n	Location	Insertion	Muscle Injury, %	Retraction, cm	Long Axis T2 Signal Length, cm
0				No	0	None	0
1	≤ 25	1	Proximal		25	< 2	1-5
2	26-31	2	Middle	Yes	50	≥ 2	6-10
3	≥ 32	3	Distal		≥ 75		> 10

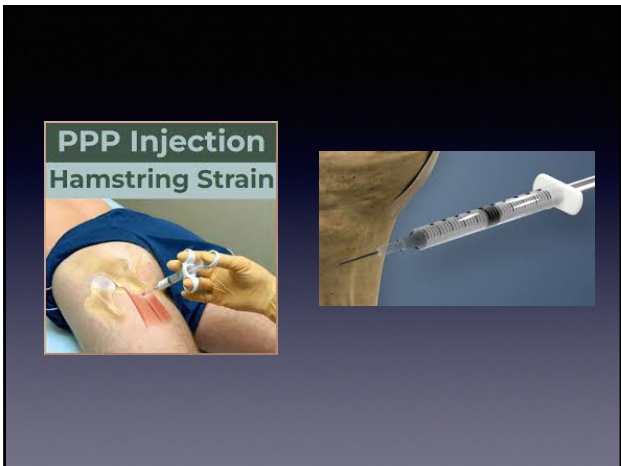the cross-sectional percentage of involvement for each based on fluid signal on T2-weighted signal (0%, 25%, 50%, 75%, 100%); the tendon or muscle retraction in centimeters.

Table 3. Positions of injured players.

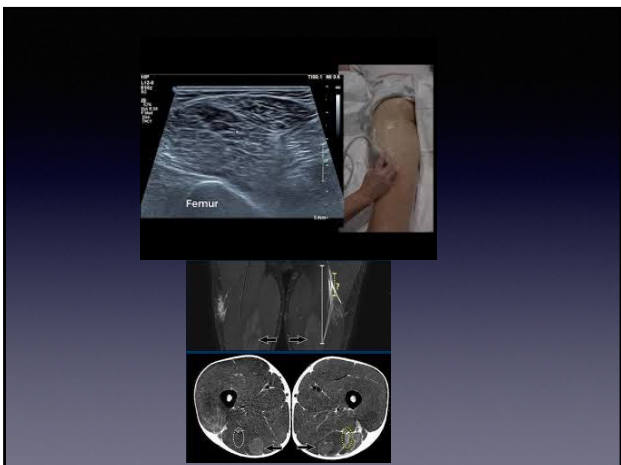
60



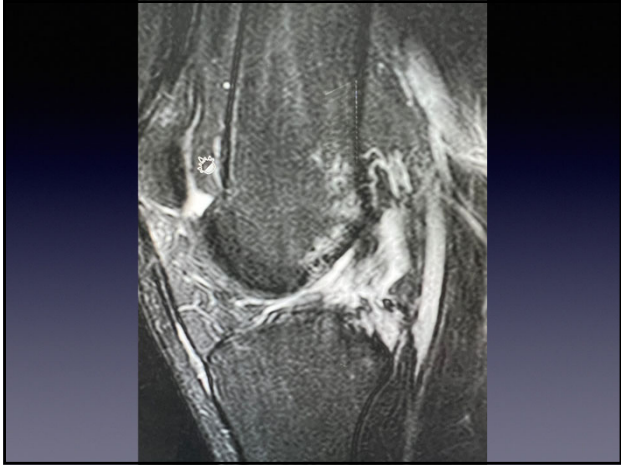
61



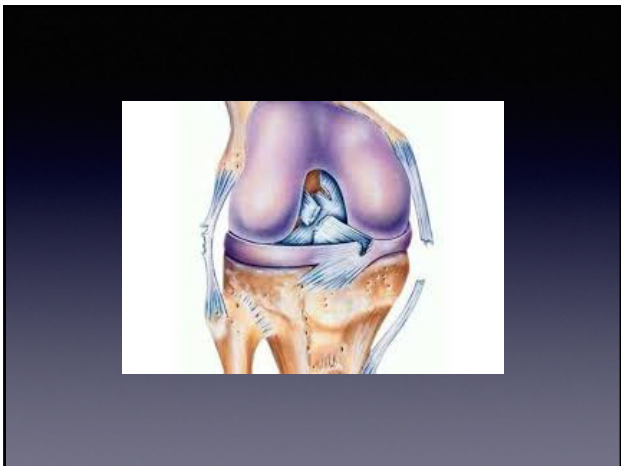
62



63



64



65

Don't Miss

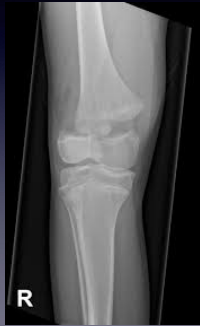The diagram shows two views of a knee joint: Anterior-Posterior (AP) and Lateral. The AP view shows the femoral condyles and the tibial plateau. The Lateral view shows the femur, tibia, and patella. A large black arrow points to the tibial tunnel location in the lateral view.

- AP View Labels:**
 - Inadequate or tilted fixation (Divergent screw or tilted cortical button)
 - Vertical femoral tunnel
 - ALL or lateral ligament insufficiency
 - Tunnel Diameter (osteolysis)
- Lateral View Labels:**
 - Malalignment
 - Graft choice (all non graft or Allgraft)
 - Missed PCL injury
 - Missed MCL injury
 - Missed not too PCL
 - Anterior femoral tunnel
 - Excessive posterior tibial slope
 - Tibial tunnel location (to posterior)

Miller MD and Thompson SR Review of Orthopaedics 8, 2020

66

Don't Miss



67

Snap Decisions in the ATR

- Gain Trust
- Follow the rules
- Develop Consistent Paradigms


68



69



70



71
