

My Shoulder Hurts

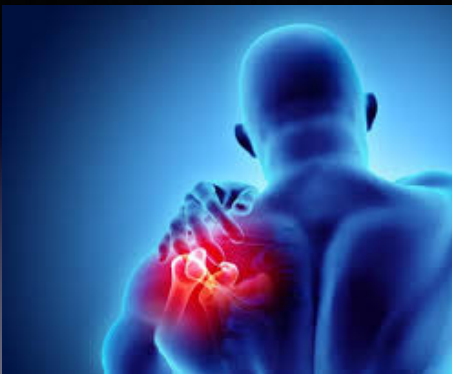Billy Thompson MD
Samaritan Health Care



1

Disclosures

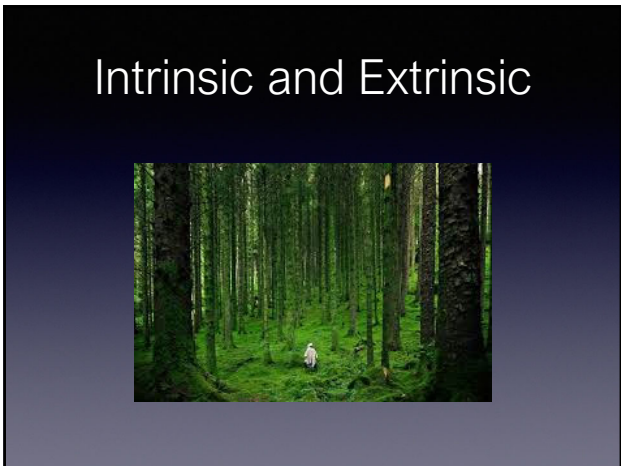
2



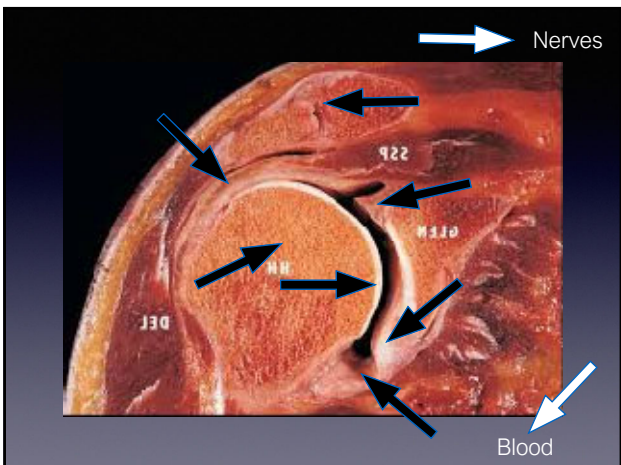
3



4



5

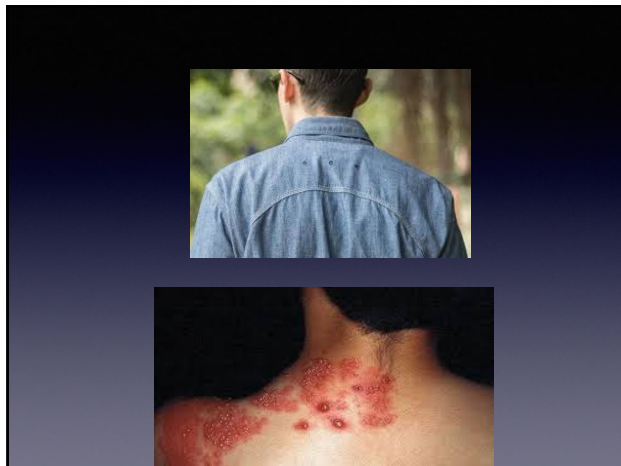

6

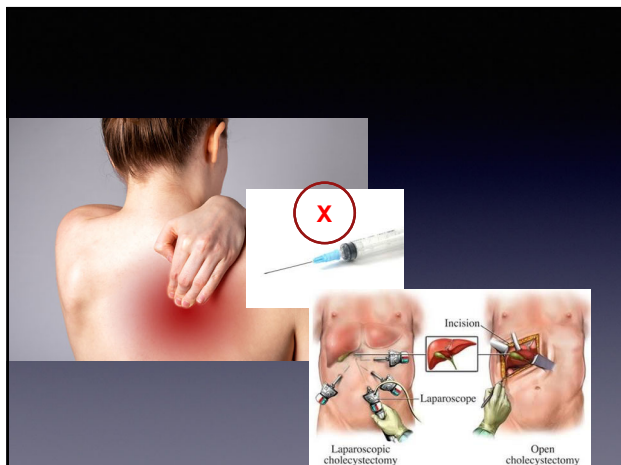
Neurogenic

- Cervical radiculopathy
- Parsonage turner syndrome
- Traumatic brachioplexopathy/stinger/burner
- Suprascapular neuropathy
- Axillary neuropathy
 - Traumatic
 - Chronic quadrilateral space syndrome
- Thoracic Outlet Neurogenic
- Shingles
- Referred Visceral

7



8




9

Blood

- Cancer
- Clots
- Occlusion
 - Subclavian Steel
 - Axillary Artery Compression
 - Thoracic Outlet
 - Arterial or Venous
- Vasculitis
- Infarcts from Sickle Cell
- Osteonecrosis
- Vascular Trauma
- Referred Cardiac

10



11

Mnemonics

- CintmatV
- Vitamin CDE
- Vitamins ABCDEK
- Vindicate
- SCARED OF

12

Listen



13

Exam

14

Neck

15

Shoulder Range of Motion

- Differences in Active and Passive ROM
- Pay Attention to External Rotation

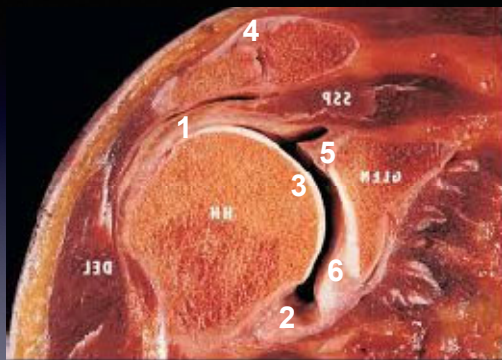
16

Strength can be deceptive



17

7 Nerves



8 Blood

18

Rapid Fire Cases

19

39 year old, female with acute severe shoulder and arm pain with night pain

- No trauma
- Shoulder pain "in the past"
- Unremitting
- MRI a few weeks ago with rotator cuff tear
- Wants to cut her arm off
 - Rubor, tumor, calor, dolor
 - Immunocompromised
 - Ill-appearing
 - Severe pain on any shoulder range of motion

20



21

39 year old, female with acute severe shoulder and arm pain with night pain

- No trauma
- No previous symptoms
- Unremitting
- Wants to cut her arm off
- No infection

22

Differential Diagnosis

- Neurogenic
 - Acute Cervical Radiculopathy
- Parsonage Turner
 - Diffuse plexus
 - Mostly C5/C6
 - Look for winging
- Steroids
- Referral EMG/Neurology
- Shingles
- Dermatome

23

Neurogenic

- Spurling's +, No Neuro Deficit
- Unable to turn head driving
 - Steroids
 - Ansaids
 - Therapy
- Close Follow-up
- +/- MRI

24

Neurogenic

- Spurling's +, Positive Neuro Deficit
 - Steroids
 - Ansaids
 - MRI
 - Refer

25

39 year old, female with acute severe shoulder and arm pain with night pain

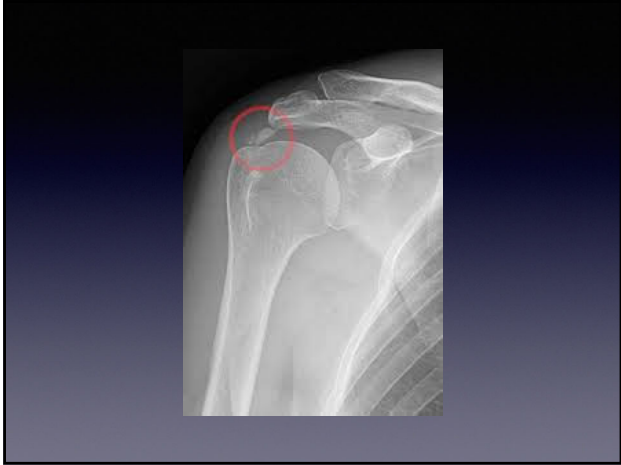- No trauma
- No previous symptoms
- Unremitting
- Wants to cut her arm off
- No infection
- Ruled out Neuro and "other"

26

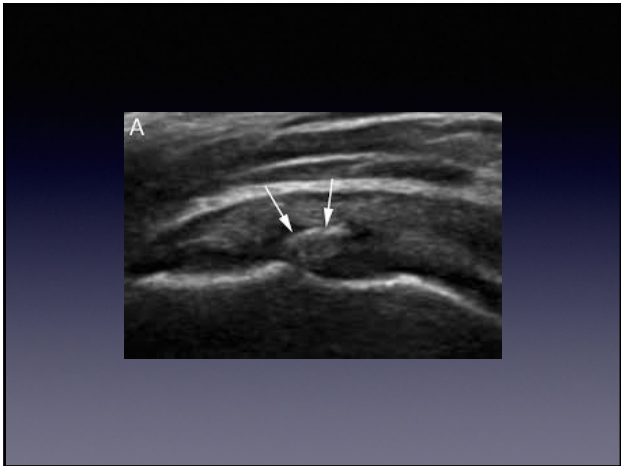
Differential Diagnosis

- ?
- ?

27



28



29

Calcific Tendinitis

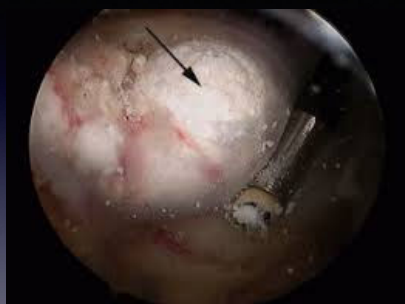- Corticosteroid Injection
- NSAIDS
- +/- Steroid
- Activity modification
- Self-limited with Time
- Rare Surgery

30

Calcific Tendinitis

- Chronic Formative Phases
- Saline hydro systems

31



No !

32

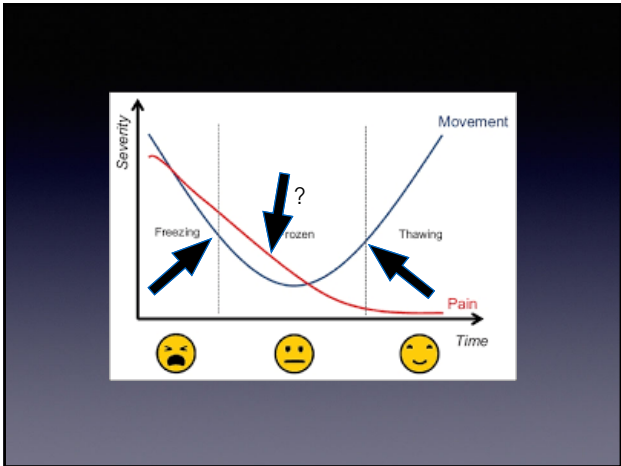39 y/o female with insidious onset
dull achey arm with night pain

- Neck exam normal
- Neuro / vascular exams normal
- FF Equal
- ER Decreased
- IR Decreased
- Strength Equivocal
- Neer Positive
- Hawkins Positive
- Xray Normal


33



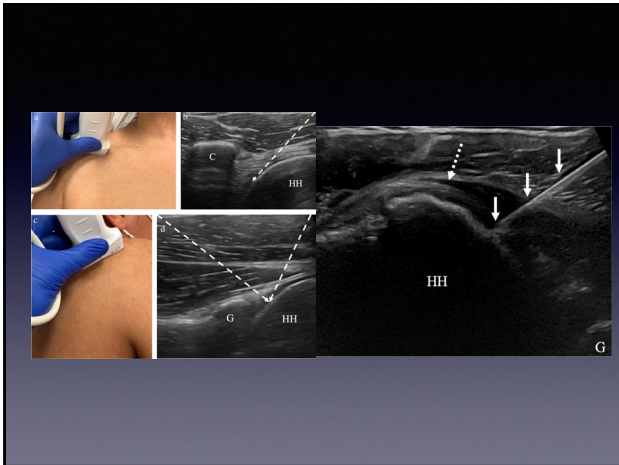
34



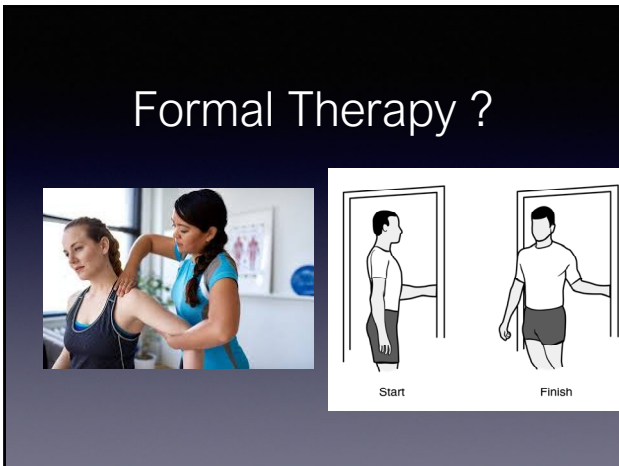35



36



37

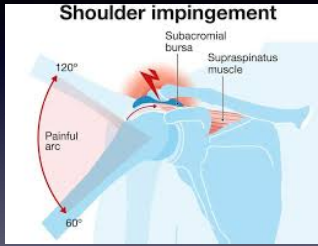


38

39 y/o female with insidious onset dull achey arm pain, sharp in the impingement zones
 No significant night pain

- Neck exam normal
- Neurovascular exams normal
- FF Equal
- ER Equal
- IR Equal
- Strength 5/5
- Neer Positive
- Hawkins Positive
- Xray Normal
- No MRI

39



40

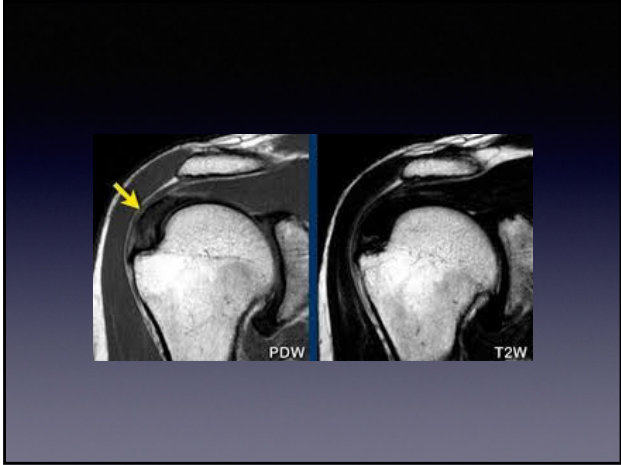
- Subacromial injection
- Activity modification
- +/- Formal Therapy = ask patient
- Formal Therapy
 - Arm at side
 - Scapular Focus
 - No "Supraspinatus Strengthening"

41

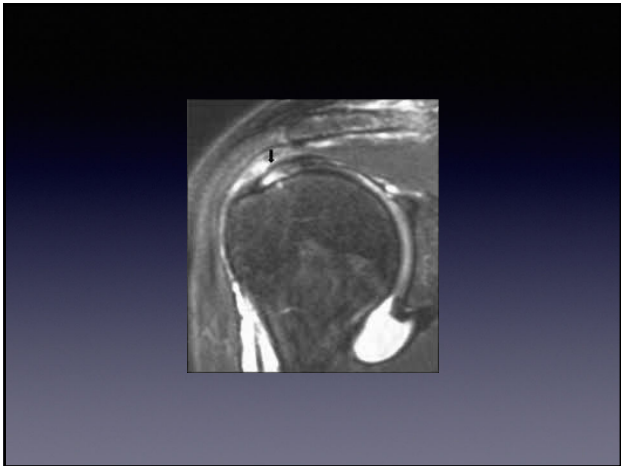
39 y/o female with insidious onset dull achey arm pain sharp in the impingement
No significant night pain

- "Complete Relief"
- "Can I have another shot?"
- "How many shots can I have?"

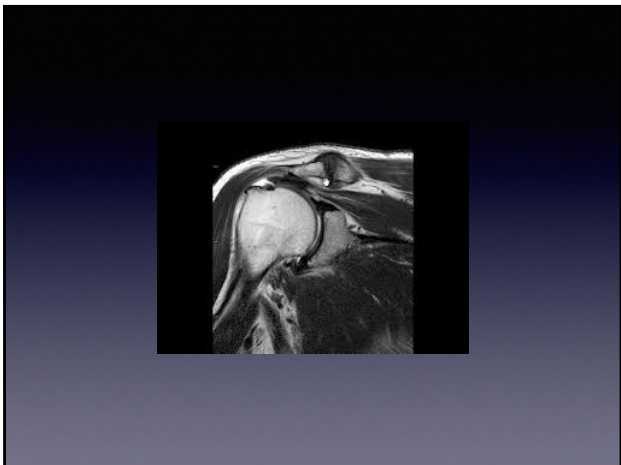
42



43

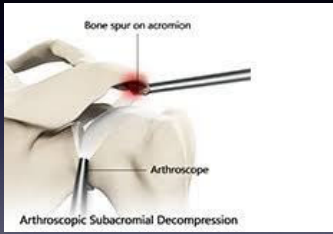


44



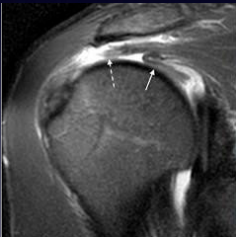
45

20 % of cases
Refer +/-1 year
Advanced Imaging



46

39 y/o female with insidious onset dull achey arm
pain sharp in the impingement with night pain

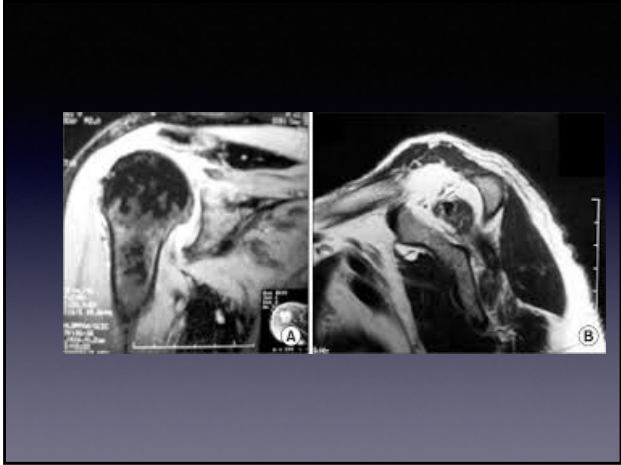


47

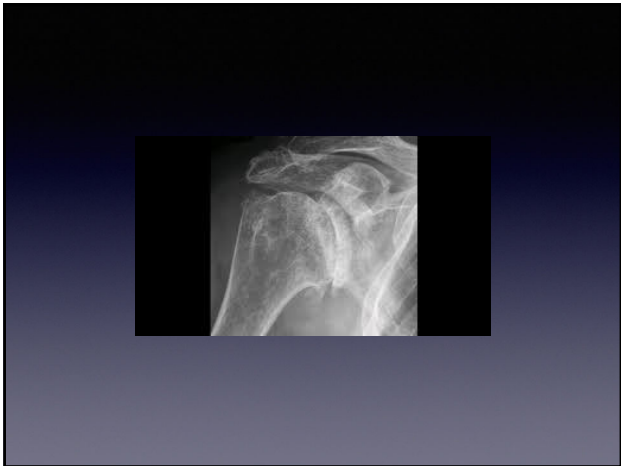39 y/o female with shoulder pain

- "Not Better and your shot didn't work"
- Wrong Diagnosis
- Bad Shot
- Double check exam especially External Rotation
- Consider diagnostic lidocaine and ultrasound guidance

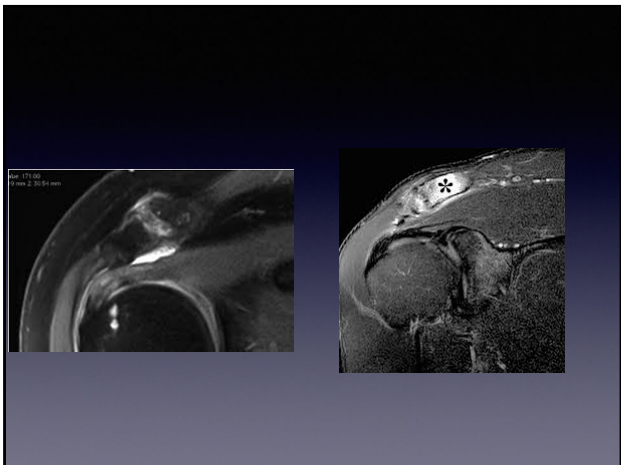
48



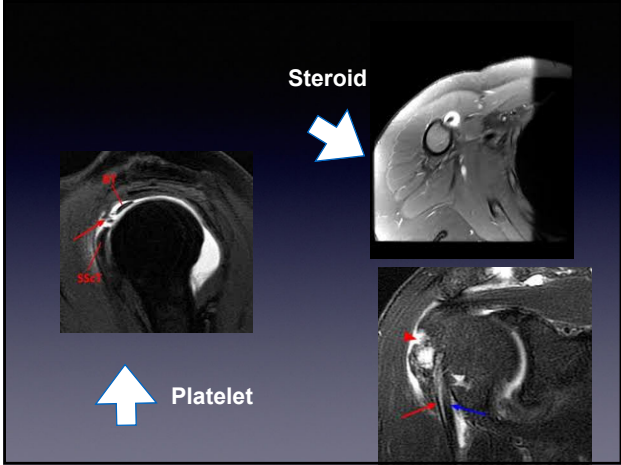
49



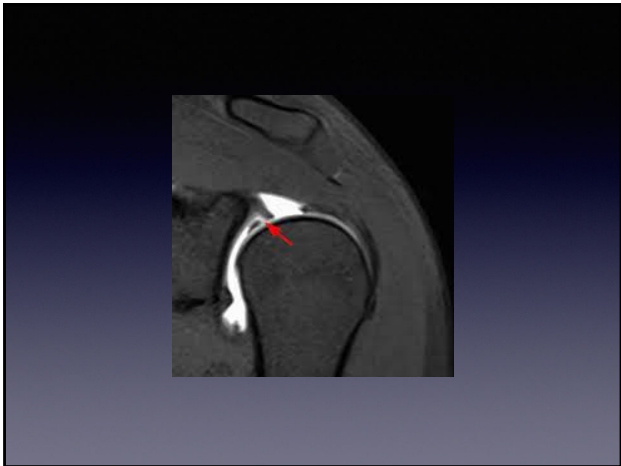
50



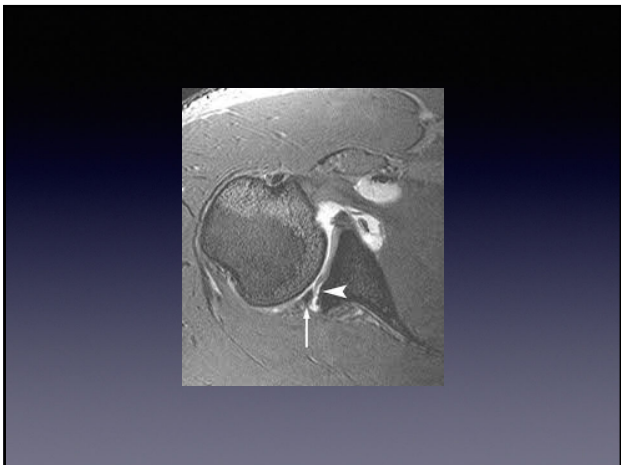
51



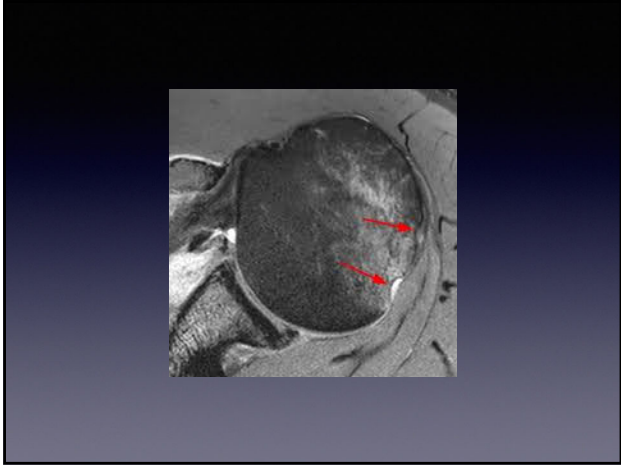
52



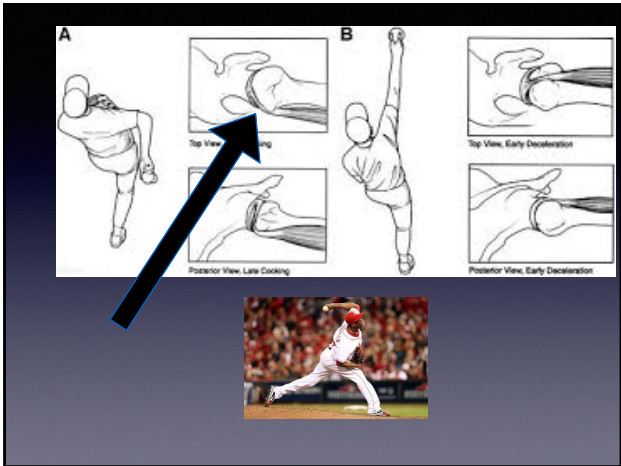
53



54



55



56

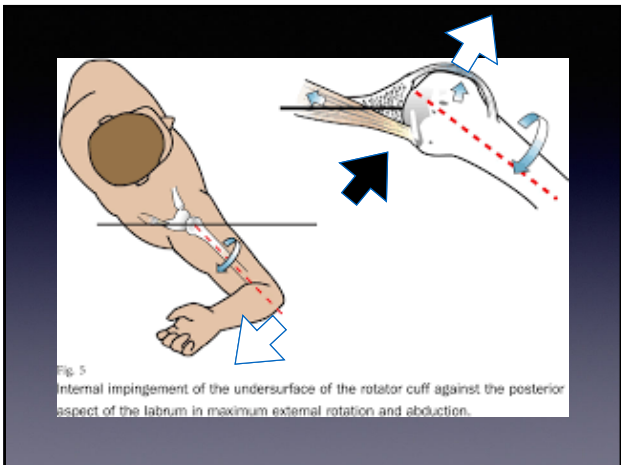
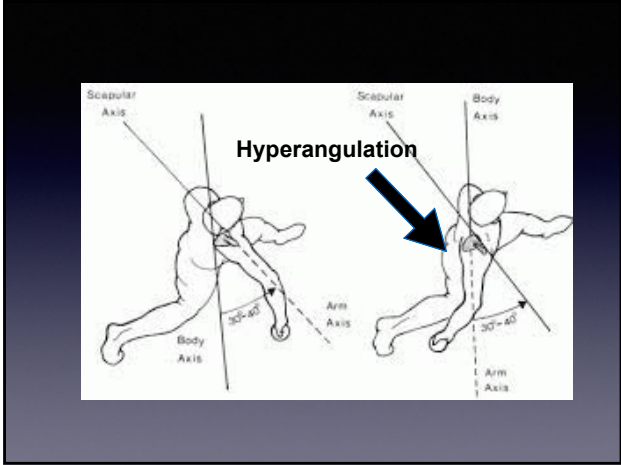
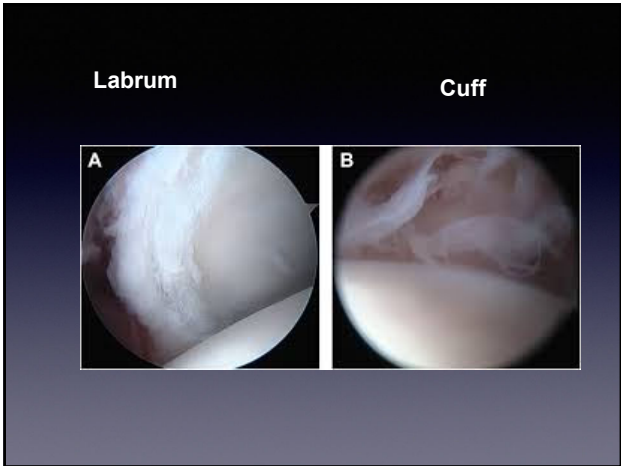


Fig. 5
Internal impingement of the undersurface of the rotator cuff against the posterior aspect of the labrum in maximum external rotation and abduction.


57



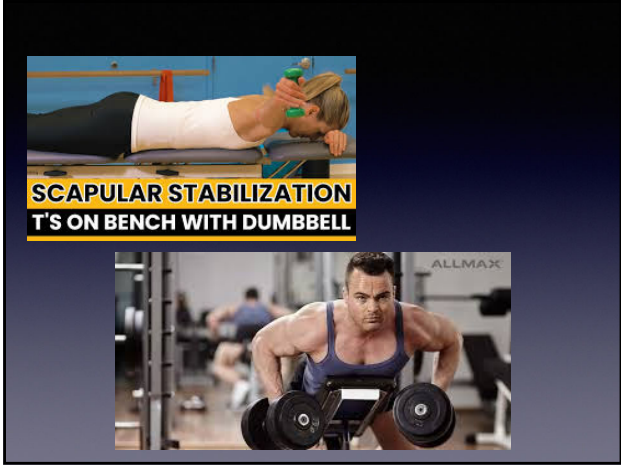58




59



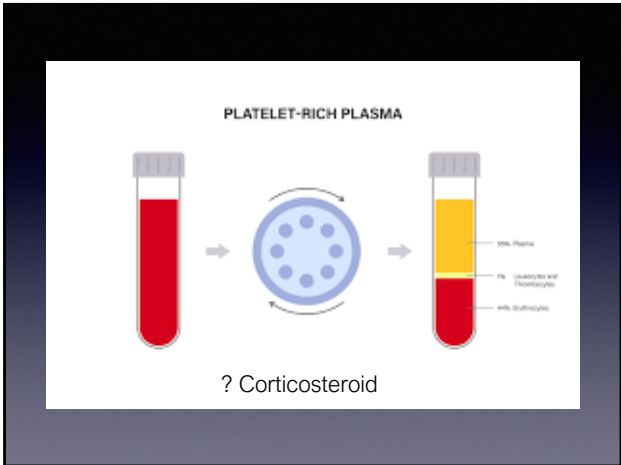
60



61

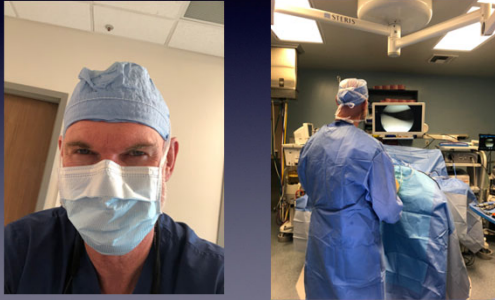

62



63

“Just Say No”



64

Thank You Q and A



65
