

ECG Interpretation in Athletes: Introducing IC25



UW Medicine



Jonathan Drezner, MD

Editor-in-Chief, *BJSM*

Professor, Department of Family Medicine

Director, UW Medicine Center for Sports Cardiology

Team Physician, Seattle Seahawks, Reign FC, & UW Huskies

University of Washington

jdrezner@uw.edu

Disclosure Information

Financial / Industry

- Ainthoven
- Cardiac Insight

Editor-in-Chief

- British Journal of Sports Medicine

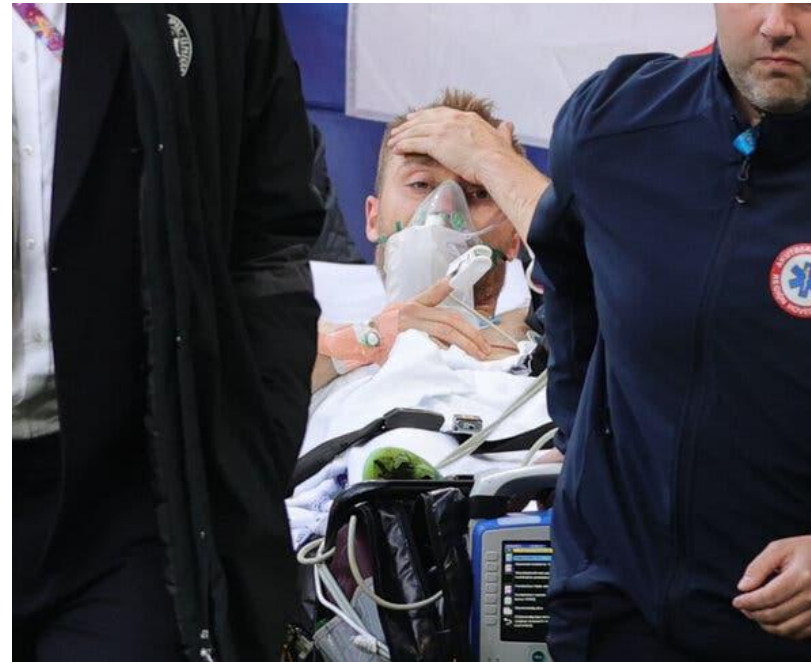Volunteer Medical Advisory

- Nick of Time Foundation
- Parent Heart Watch
- Who We Play For


Research Funding

- NCCSIR – Division of Cardiac Injury
- AHA – ORCCA Study





Christian Eriksen – June 12, 2021



Bronny James, older son of LeBron James, suffers cardiac arrest at USC basketball practice



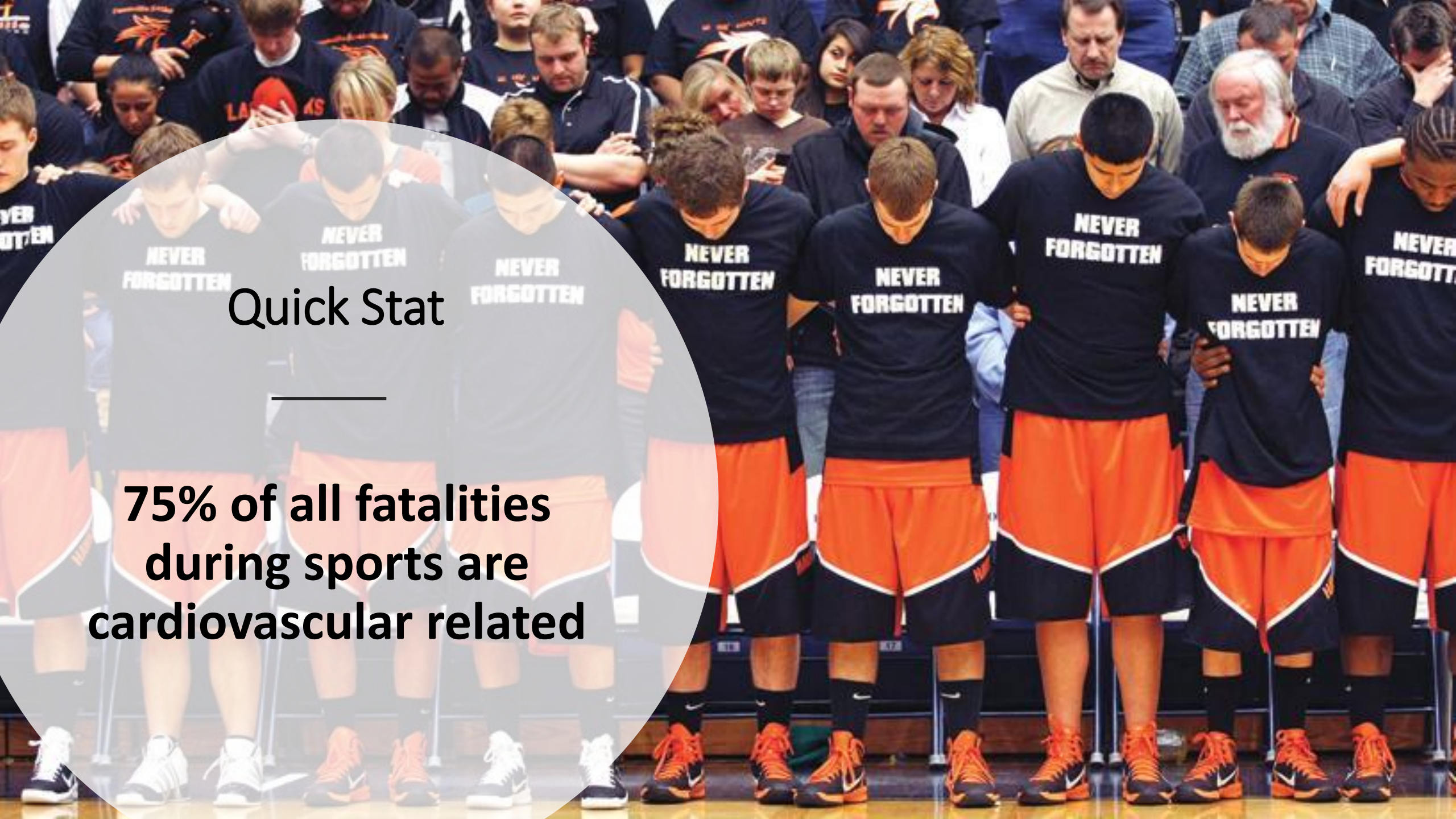By [Eric Levenson](#) and [David Close](#), CNN
Updated 4:39 AM EDT, Wed July 26, 2023



Sudden Cardiac Arrest in Young Athletes

- **Leading cause of death** in young athletes during sport
- **Exercise is trigger** for SCA in athletes with underlying cardiac disorder






Quick Stat

75% of all fatalities during sports are cardiovascular related


Sudden Cardiac Death in Athletes




Flo Hyman
January 24, 1986



Len Bias
June 19, 1986



Hank Gathers
March 4, 1990



Reggie Lewis
July 27, 1993

Lessons Learned

SCA/D is not so rare!

History & physical is not enough

Precision ECG interpretation is possible

AEDs should be everywhere

SCA goes unrecognized

OBJECTIVES



Distinguish normal physiologic ECG findings from ECG abnormalities requiring more investigation



Define the latest updates to ECG interpretation in athletes based on the 2025 International Criteria (IC25)



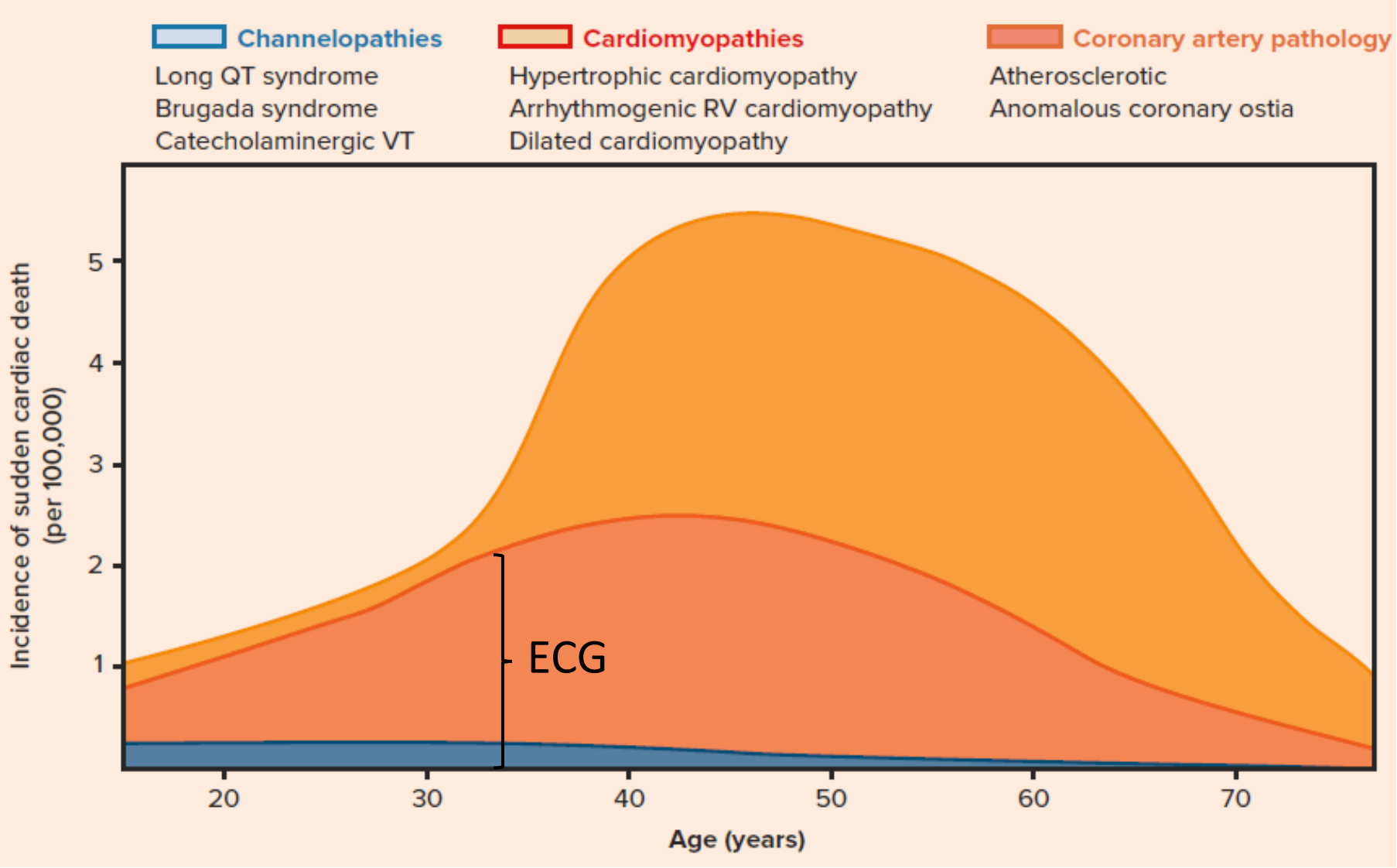
Outline the recommended secondary evaluation of specific ECG abnormalities



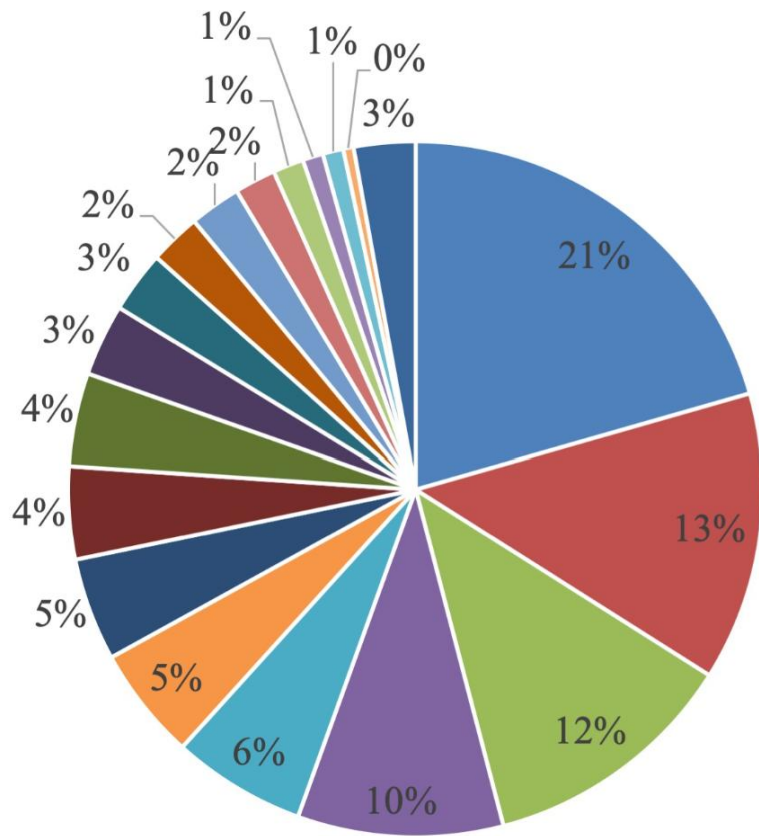
Outline

- Epidemiology of SCA/D
- Cardiovascular screening
- Evolution of ECG interpretation criteria
- **New and emerging science**
- **Key changes IC17 → IC25**
- **5-steps to accurate ECG interpretation**

Age Dependent Incidence & Causes of SCD



La Gerche et al. *JACC Cardiovasc Imaging* 2013



BJSM 2020

- Hypertrophic cardiomyopathy (43, 20.6%)
- Idiopathic left ventricular hypertrophy (28, 13.4%)
- Coronary artery anomalies (25, 12.0%)
- Autopsy negative sudden unexplained death (20, 9.6%)
- Arrhythmogenic cardiomyopathy (13, 6.2%)
- Long QT syndrome (11, 5.3%)
- Commotio cordis (10, 4.8%)
- Wolff-Parkinson-White (9, 4.3%)
- Myocarditis (9, 4.3%)
- Aortic dissection/rupture (7, 3.3%)
- Dilated cardiomyopathy (6, 2.9%)
- Valve disorder (5, 2.4%)
- Coronary atherosclerosis (5, 2.4%)
- Complications of a congenital heart defect (4, 1.9%)
- Catecholaminergic polymorphic ventricular tachycardia (3, 1.4%)
- Hypertensive heart disease (2, 1.0%)
- Left ventricular noncompaction (2, 1.0%)
- Restrictive cardiomyopathy (1, 0.5%)
- Other (6, 2.9%)

Original research

OPEN ACCESS

Aetiology and incidence of sudden cardiac arrest and death in young competitive athletes in the USA: a 4-year prospective study

Danielle F Peterson,¹ Kristen Kucera,² Leah Cox Thomas,³ Joseph Maleszewski,⁴ David Siebert,⁵ Martha Lopez-Anderson,⁶ Monica Zigman,⁵ Jared Schattenkerk,⁷ Kimberly G Harmon,⁵ Jonathan A Drezner,⁸

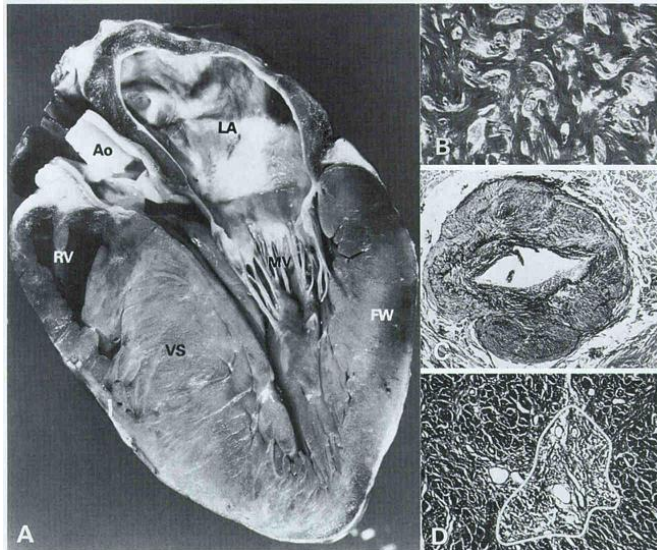
Prospective surveillance
July 2014 – June 2018
331 cases of confirmed SCA/D



Most Common Causes of SCA/D

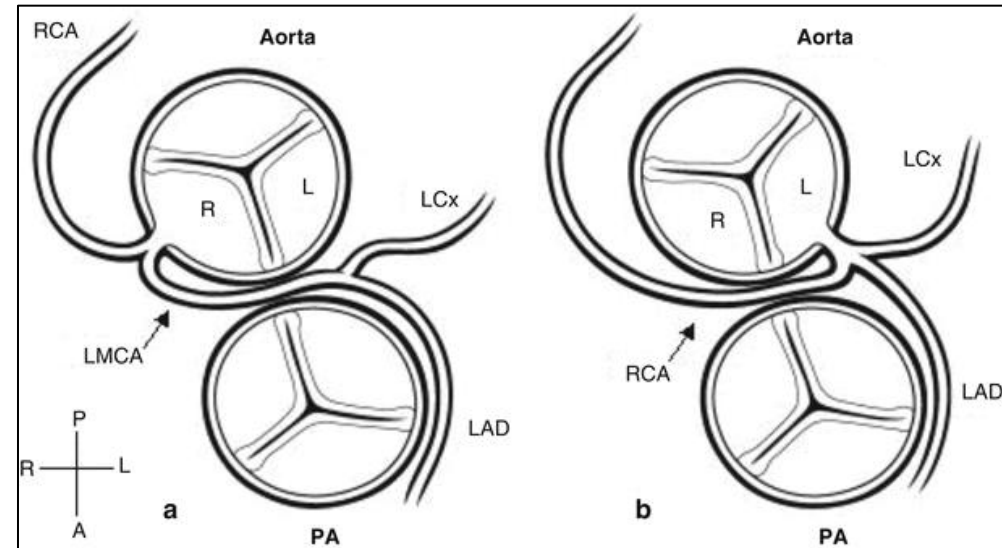
Cardiomyopathies

- 20% overall
- 20% high school
- **47% college and professional athletes**



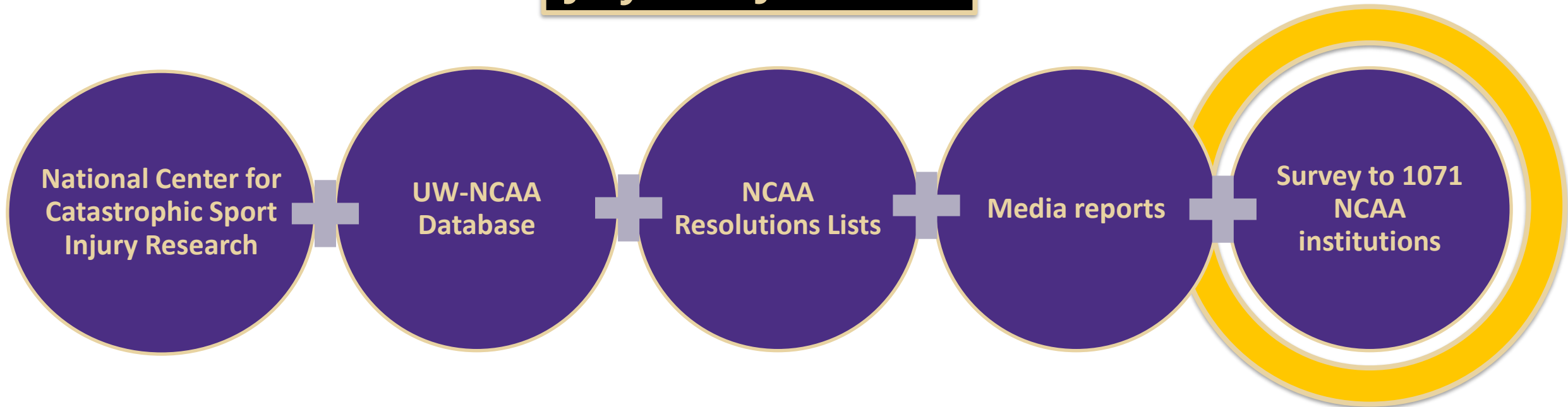Anomalous Coronary Artery

- 12% overall
- 12% high school
- **28% middle school athletes**



Incidence of Sudden Cardiac Arrest and Death in NCAA Athletes: A 9-year Surveillance Study

July 2014-June 2023

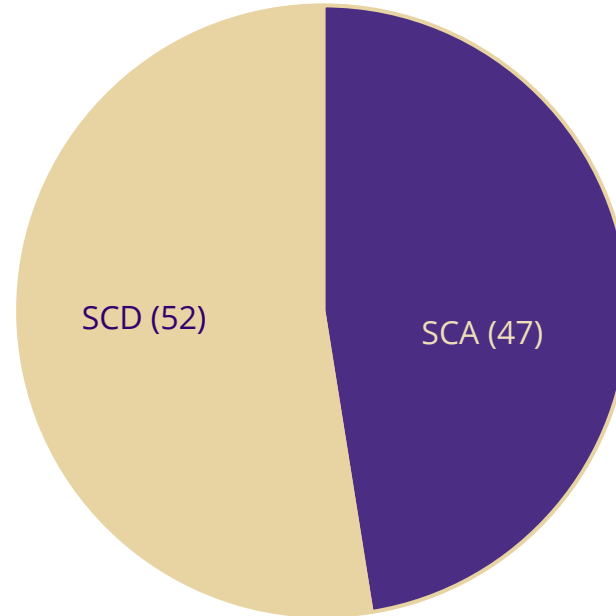


An expert panel adjudicated etiologies of SCA/D with available info.

RESULTS

SCA/D

1 in 45,814 AY
(95%CI 1 in 37,361 AY to 1 in 56,369 AY)



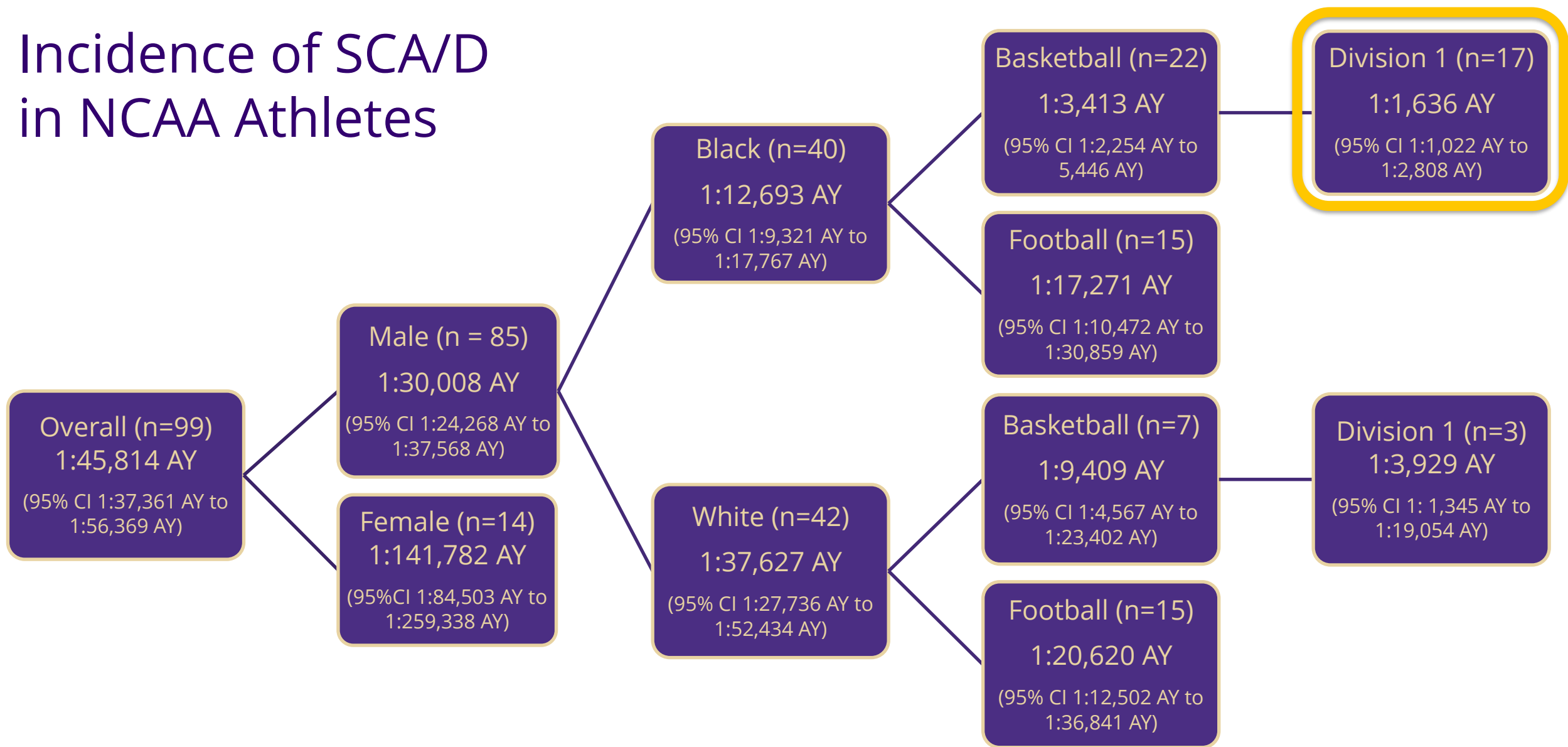
SCD

1 in 87,223 AY
(95%CI 1 in 66,513 AY to 1 in 116,789 AY)

SCA

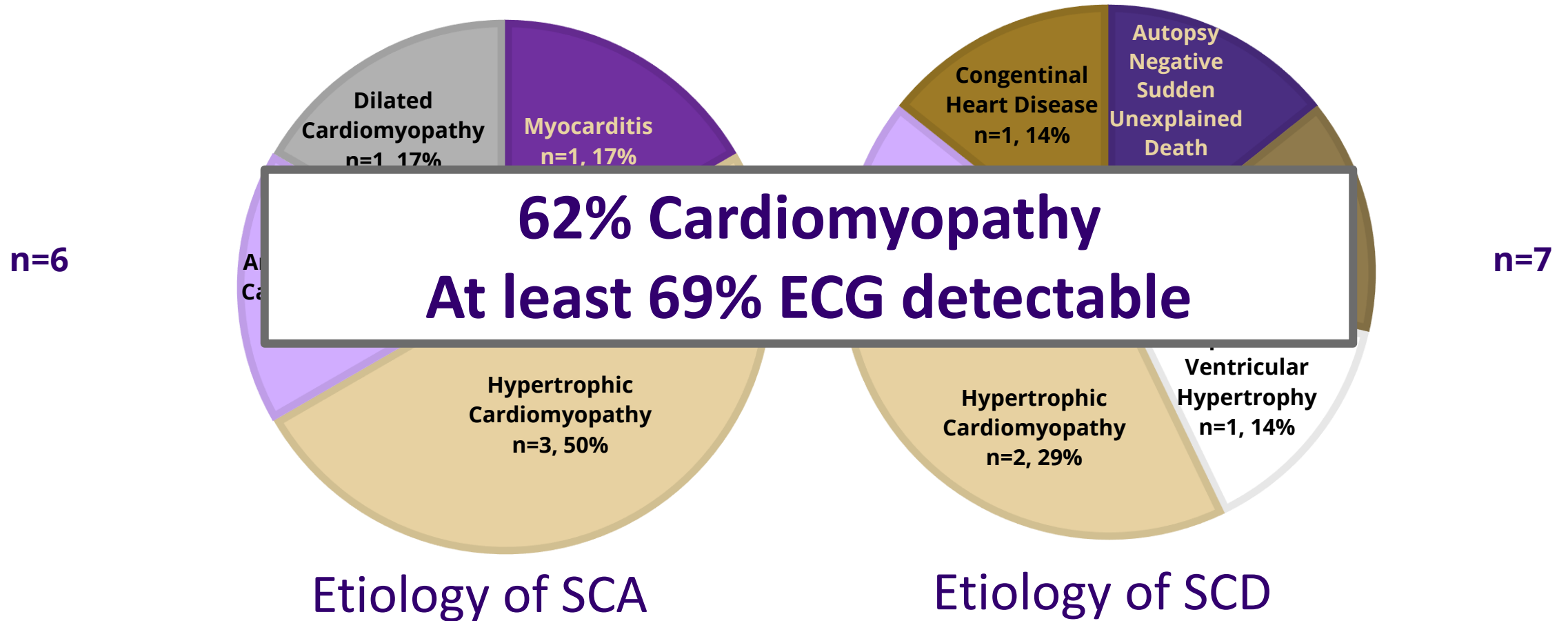
1 in 96,503 AY
(95%CI 1 in 72,570 AY to 1 in 131,338 AY)

Incidence of SCA/D in NCAA Athletes



Etiology of Men's Basketball Cases


An adjudicated cause was determined in 45% of cases.



Cardiovascular Screening in Athletes

Unravelling the Puzzle

- Widespread agreement that screening is **important**
- **Early detection** of conditions at risk of SCD
- **Evidence-based** approach



Cardiovascular Screening in Athletes

Bridging the Gap



*Best
Practice*

History & Physical

- Model is inadequate to fulfill the primary objective of screening
- Limited effectiveness
- Lacks scientific validation

**Education
Training
Infrastructure**



















ECG

- Accomplishes the same goal with greater effectiveness
- Requires competence in ECG interpretation
- Cardiology resources to conduct proper secondary investigations and management of identified disorders

FIFA consensus: “best practice” recommendations for cardiac screening in youth football players

Consensus statement

Recommendations for cardiac screening and emergency action planning in youth football: a FIFA consensus statement

Aaron L Baggish ^{1,2}, Mats Borjesson ³, Guido E Pieles ^{4,5},
Christian Schmied ⁶, Clea Simone Sabino de Souza Colombo ⁷,
Cecilia Gonzales Corcia ⁸, Jonathan A Drezner ⁹, Katharina Grimm ¹⁰,
Gary Mak,¹¹ André La Gerche ¹², Ben Levine ¹³, Sabiha Gati ¹⁴,
Andrew Massey ¹⁰, Prince Pambo,^{15,16} Antonio Pelliccia ¹⁷,
Margot Putukian ¹⁸, Yasser Abdelrahman ¹⁹, Sanjay Sharma ²⁰,
Mathew G Wilson ²¹, Andreas Serner ²², FIFA Youth Cardiac Screening Review
Panel

BJSM 2025



FIFA RECOMMENDATIONS FOR CARDIAC SCREENING IN YOUTH FOOTBALL PLAYERS



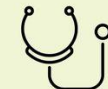(Screening should be initiated at 12 years and repeated every 2-4 years)

Key components of routine screening



Personal & Family Medical History

+



Focused Physical Examination

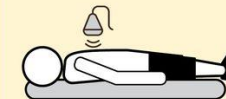+



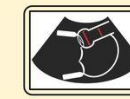Resting 12-Lead Electrocardiogram

Not recommended for routine screening

(may be considered to enhance detection of specific anomalies/disease, if adequate resources and expertise available)

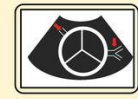

Transthoracic Echocardiography



Aortic Dimensions

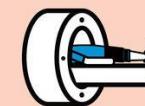+



Coronary Origins

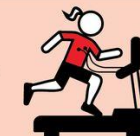Not recommended for routine screening

(should be available for assessment of abnormalities detected during the screening)



Cardiac MRI

+



Exercise Testing

+



Rhythm Monitoring

AHA/ACC SCIENTIFIC STATEMENT

Clinical Considerations for Competitive Sports Participation for Athletes With Cardiovascular Abnormalities: A Scientific Statement From the American Heart Association and American College of Cardiology

Jonathan H. Kim, MD, MSc, FACC, Aaron L. Baggish, MD, FACC, Benjamin D. Levine, MD, FAHA, FACC, Michael J. Ackerman, MD, PhD, FACC, Sharlene M. Day, MD, FAHA, Elizabeth H. Dineen, DO, FACC, J. Sawalla Guseh II, MD, Andre La Gerche, MBBS, PhD, Rachel Lampert, MD, FHRS, FACC, Matthew W. Martinez, MD, FACC, Michael Papadakis, MBBS, MD, FRCP, Dermot M. Phelan, MD, PhD, FACC, and Keri M. Shafer, MD, FACC on behalf of the American Heart Association Leadership Committee of the Council on Clinical Cardiology; Council on Basic Cardiovascular Sciences; Council on Cardiovascular and Stroke Nursing; Council on Cardiovascular Surgery and Anesthesia; Council on Peripheral Vascular Disease; and American College of Cardiology

- “12-lead ECG screening is reasonable as long as **equitable access to expertise and a downstream process with appropriate resources are available.**”
- “Although the **H&P has relatively low sensitivity (10%–20%)** in detecting silent cardiac conditions, symptomatic athletes with previously unrecognized disease and individuals with family history suggestive of inherited cardiovascular disorders can be identified.”
- “An **ECG enhances detection** of ion channelopathies, accessory pathways, and many cardiomyopathies, increasing the sensitivity of the PPE for detection of potentially fatal cardiac conditions **to 94%.**”

Table 4. Clinical Considerations for the Preparticipation Cardiac Evaluation of Competitive Athletes

Specific clinical considerations

Cardiac screening should be considered 1 component of SCA prevention that aims to identify competitive athletes with unrecognized cardiovascular disease to allow individualized and disease-specific management to prevent an adverse event.

A cardiac screening program should ensure access to high-quality primary screening and secondary evaluation, including the financial and logistical resources to ensure a systematic process for downstream clinical evaluation.

As a component of preparticipation screening, the cardiovascular medical history and physical examination should be performed as it can detect symptomatic competitive athletes with previously unrecognized disease and those with a family history suggestive of an inherited cardiovascular disorder.

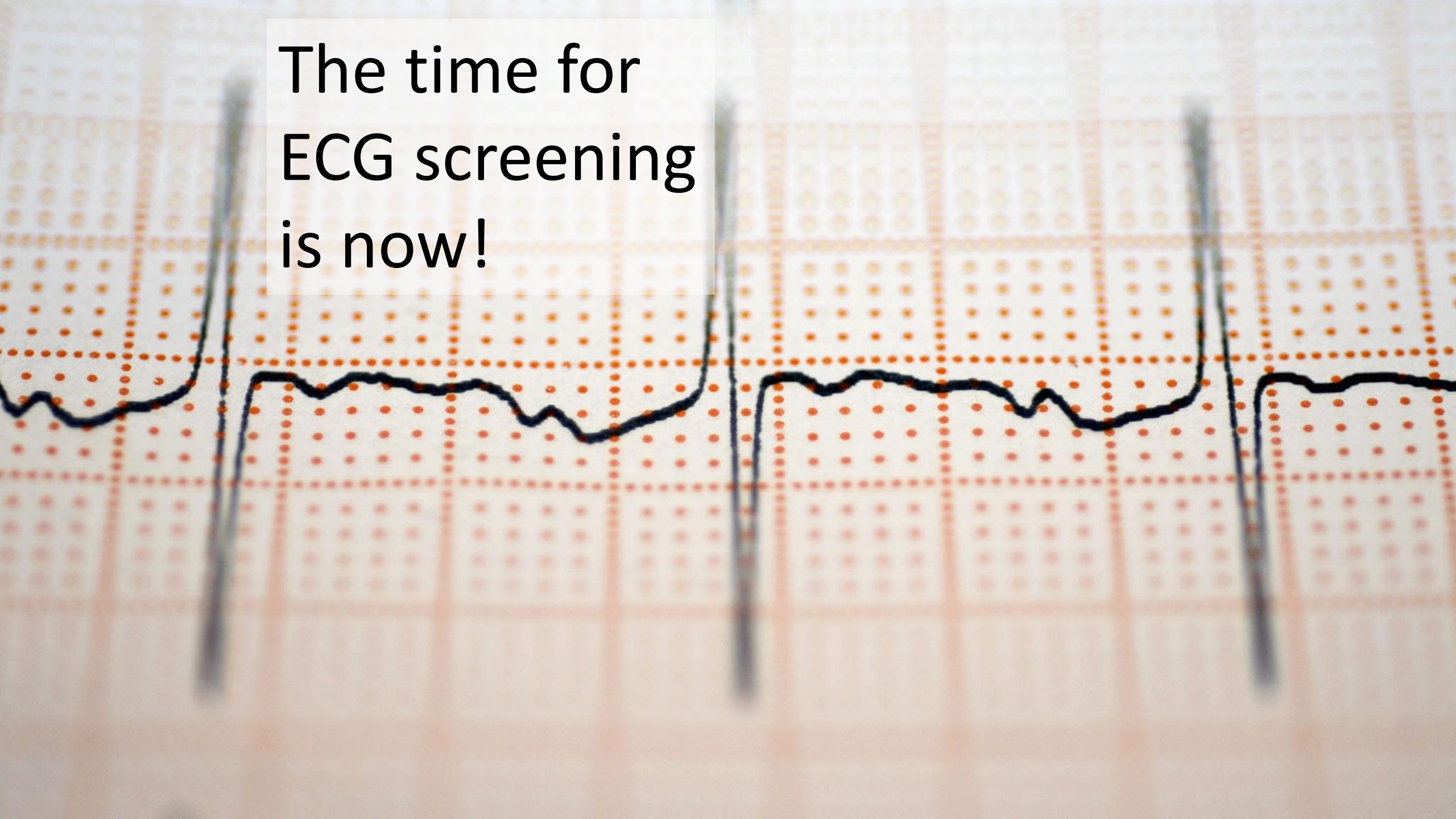The inclusion of a resting 12-lead ECG is reasonable as it improves detection of underlying cardiac conditions in asymptomatic competitive athletes compared with medical history and physical examination alone.

Effective ECG-inclusive preparticipation screening requires the involvement of clinicians with adequate training in the use of contemporary athlete-specific ECG interpretation criteria to minimize potential harm.

Cardiac imaging, exercise stress testing, and ambulatory rhythm monitoring have insufficient data to suggest incremental value for use in the primary screening of asymptomatic competitive athletes.

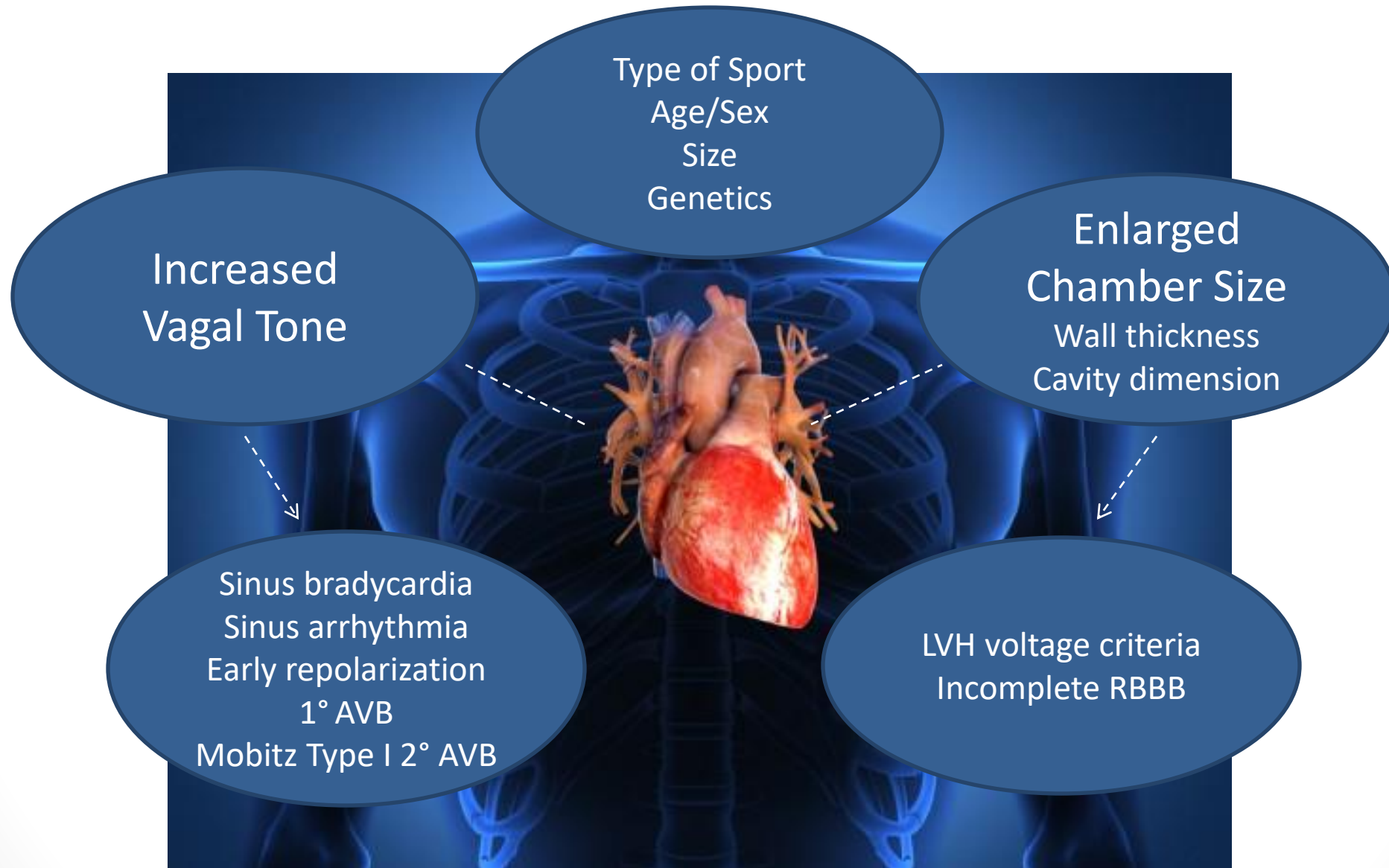
No approach to cardiac preparticipation screening provides absolute protection against SCA. Thus, an emergency action plan that includes training in high-quality CPR, prompt access to an AED, and a coordinated medical transport system should be developed, practiced, and used for all environments in which competitive athletes train and compete.

The time for
ECG screening
is now!



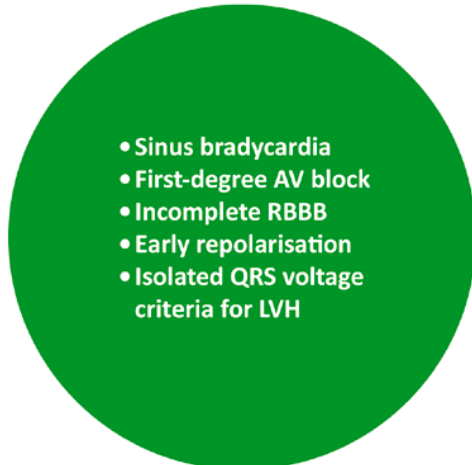
ECG Interpretation in Athletes

Physiologic Cardiac Adaptation: 'Athlete's Heart'

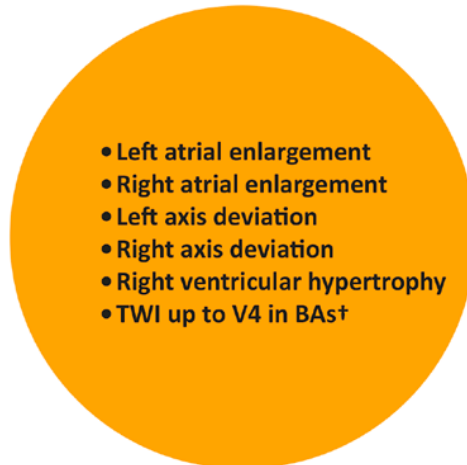

Evolution of ECG Interpretation in Athletes

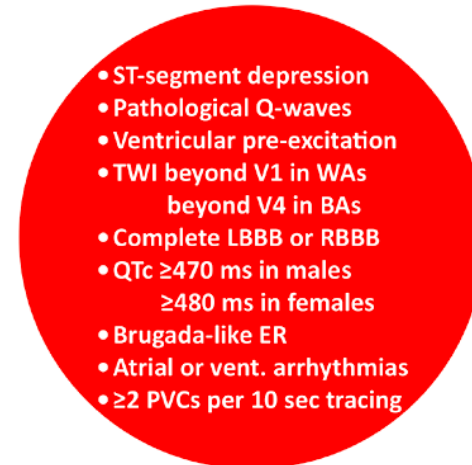
Refined Criteria Training Related Normal Variants *Not Warranting Further Investigation**



Refined Criteria Borderline Variants *Potentially Warranting Further Investigation*



Refined Criteria Training Unrelated Changes *Warranting Further Investigation*



*If present in ISOLATION**

If TWO OR MORE present

Epidemiology and Prevention

Comparison of Electrocardiographic Criteria for the Detection of Cardiac Abnormalities in Elite Black and White Athletes

Nabeel Sheikh, MRCP; Michael Papadakis, MRCP; Saqib Ghani, MRCP; Abbas Zaidi, MRCP; Sabiha Gati, MRCP; Paolo Emilio Adami, MD; François Carré, PhD; Frédéric Schnell, PhD; Mathew Wilson, PhD; Paloma Avila, MD; William McKenna, MD, DSc, FESC; Sanjay Sharma, MD, FRCP, FESC (UK)

2014

2nd International Summit on ECG Interpretation in Athletes

February 26-27, 2015 – Seattle, WA



International recommendations for electrocardiographic interpretation in athletes

Sanjay Sharma^{1,*†}, Jonathan A. Drezner^{2†}, Aaron Baggish³, Michael Papadakis¹,
Mathew G. Wilson⁴, Jordan M. Prutkin⁵, Andre La Gerche⁶, Michael J. Ackerman⁷,
Mats Borjesson⁸, Jack C. Salerno⁹, Irfan M. Asif¹⁰, David S. Owens¹¹, Eugene H. Chung¹²,
Michael S. Emery¹³, Victor F. Froelicher¹⁴, Hein Heidbuchel¹⁵, Carmen Adamuz¹⁶,
Chad A. Asplund¹⁷, Gordon Cohen¹⁸, Kimberly G. Harmon¹⁹, Joseph C. Marek²⁰,
Silvana Molossi²¹, Josef Niebauer²², Hank F. Pelto²³, Marco V. Perez²⁴,
Nathan R. Riding²⁵, Tess Saarel²⁶, Christian M. Schmied²⁷, David M. Shipon²⁸,
Ricardo Stein²⁹, Victoria L. Vetter³⁰, Antonio Pelliccia³¹, Domenico Corrado³²

2017

International Recommendations for Electrocardiographic Interpretation in Athletes



Sanjay Sharma, MD,^{a,*} Jonathan A. Drezner, MD,^{b,*} Aaron Baggish, MD,^c Michael Papadakis, MD,^a
Mathew G. Wilson, PhD,^d Jordan M. Prutkin, MD, MHS,^e Andre La Gerche, MD, PhD,^f Michael J. Ackerman, MD, PhD,^g
Mats Borjesson, MD,^h Jack C. Salerno, MD,ⁱ Irfan M. Asif, MD,^j David S. Owens, MD, MS,^e
Eugene H. Chung, MD,^k Michael S. Emery, MD,^l Victor F. Froelicher, MD,^m Hein Heidbuchel, MD, PhD,^{n,o}
Carmen Adamuz, MD,^p Chad A. Asplund, MD,^q Gordon Cohen, MD,^q Kimberly G. Harmon, MD,^b
Joseph C. Marek, MD, PhD,^t Hank F. Pelto, MD,^b Marco V. Perez, MD,^u
David M. Shipon, MD,^w Ricardo Stein, MD,^x Victoria L. Vetter, MD,^y Antonio Pelliccia, MD,^{aa} Domenico Corrado, MD, PhD^{bb}

International criteria for electrocardiographic interpretation in athletes

Jonathan A Drezner,¹ Sanjay Sharma,² Aaron Baggish,³ Michael Papadakis,²
Mathew G Wilson,⁴ Jordan M Prutkin,⁵ Andre La Gerche,⁶ Michael J Ackerman,^{7,8,9,10,11}
Mats Borjesson,^{12,13} Jack C Salerno,¹⁴ Irfan M Asif,¹⁵ David S Owens,⁵
Eugene H Chung,¹⁶ Michael S Emery,¹⁷ Victor F Froelicher,¹⁸ Hein Heidbuchel,¹⁹
Carmen Adamuz,⁴ Chad A Asplund,²⁰ Gordon Cohen,^{21,22} Kimberly G Harmon,¹
Joseph C Marek,²³ Silvana Molossi,^{24,25} Josef Niebauer,²⁶ Hank F Pelto,¹
Marco V Perez,²⁷ Nathan R Riding,⁴ Tess Saarel,^{28,29} Christian M Schmied,³⁰
David M Shipon,³¹ Ricardo Stein,³² Victoria L Vetter,³³ Antonio Pelliccia,³⁴
Domenico Corrado^{35,36,37}

This statement has been endorsed by the following societies: American Medical Society for Sports Medicine (AMSSM), Austrian Society of Sports Medicine and Prevention, Brazilian Society of Cardiology – Department of Exercise and Rehabilitation (SBC – DERC), British Association for Sports and Exercise Medicine (BASEM), Canadian Academy of Sport and Exercise Medicine (CASEM), European College of Sports and Exercise Physicians (ECOSEP), European Society of Cardiology (ESC) Section of Sports Cardiology, Fédération Internationale de Football Association (FIFA), German Society of Sports Medicine and Prevention, International Olympic Committee (IOC), Norwegian Association of Sports Medicine and Physical Activity (NIMF), South African Sports Medicine Association (SASMA), Spanish Society of Cardiology (SEC) Sports Cardiology Group, Sports Doctors Australia, and the Swedish Society of Exercise and Sports Medicine (SFAIM). The American College of Cardiology (ACC) affirms the value of this document. ACC supports the general principles in the document and believes it is of general benefit to its membership.

International Criteria for ECG Interpretation in Athletes

Normal ECG Findings

- Increased QRS voltage for LVH or RVH
- Incomplete RBBB
- Early repolarization/ST segment elevation
- ST elevation followed by T wave inversion V1-V4 in black athletes
- T wave inversion V1-V3 \leq age 16 years old
- Sinus bradycardia or arrhythmia
- Ectopic atrial or junctional rhythm
- 1° AV block
- Mobitz Type I 2° AV block

Borderline ECG Findings

- Left axis deviation
- Left atrial enlargement
- Right axis deviation
- Right atrial enlargement
- Complete RBBB

Abnormal ECG Findings

- T wave inversion
- ST segment depression
- Pathologic Q waves
- Complete LBBB
- QRS \geq 140 ms duration
- Epsilon wave
- Ventricular pre-excitation
- Prolonged QT interval
- Brugada Type 1 pattern
- Profound sinus bradycardia $<$ 30 bpm
- PR interval \geq 400 ms
- Mobitz Type II 2° AV block
- 3° AV block
- \geq 2 PVCs
- Atrial tachyarrhythmias
- Ventricular arrhythmias

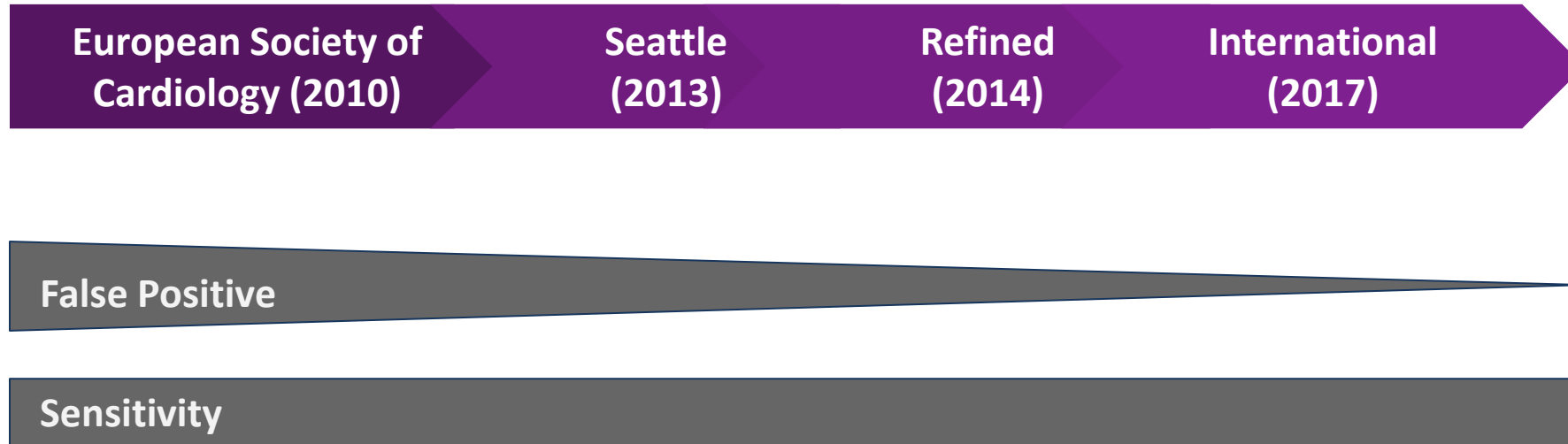
No further evaluation required
in asymptomatic athletes with no family history of inherited cardiac disease or SCD

In isolation

2 or more

Further evaluation required
to investigate for pathologic cardiovascular disorders associated with SCD in athletes

Evolution of ECG Interpretation Standards





International Summit on ECG Interpretation in Athletes

September 25-26, 2025

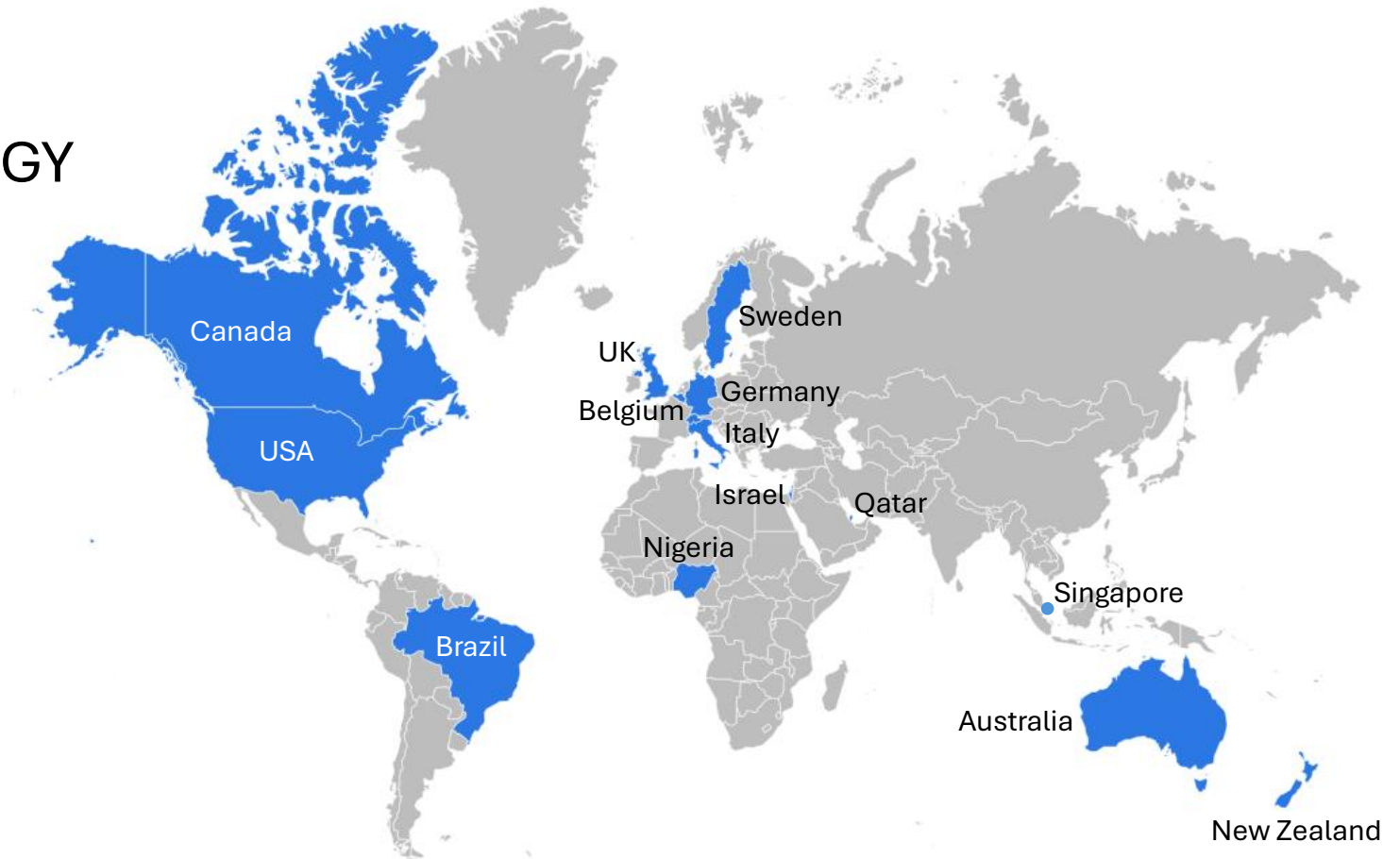




ECG Summit




- 54 PANELISTS
- 14 COUNTRIES
- ADULT & PEDIATRIC CARDIOLOGY
- CARDIOMYOPATHY
- ELECTROPHYSIOLOGY
- EXERCISE PHYSIOLOGY
- GENETICS
- SPORTS MEDICINE





ECGsummit.org



The primary purpose of cardiac screening in athletes is the identification of conditions at risk for SCD.

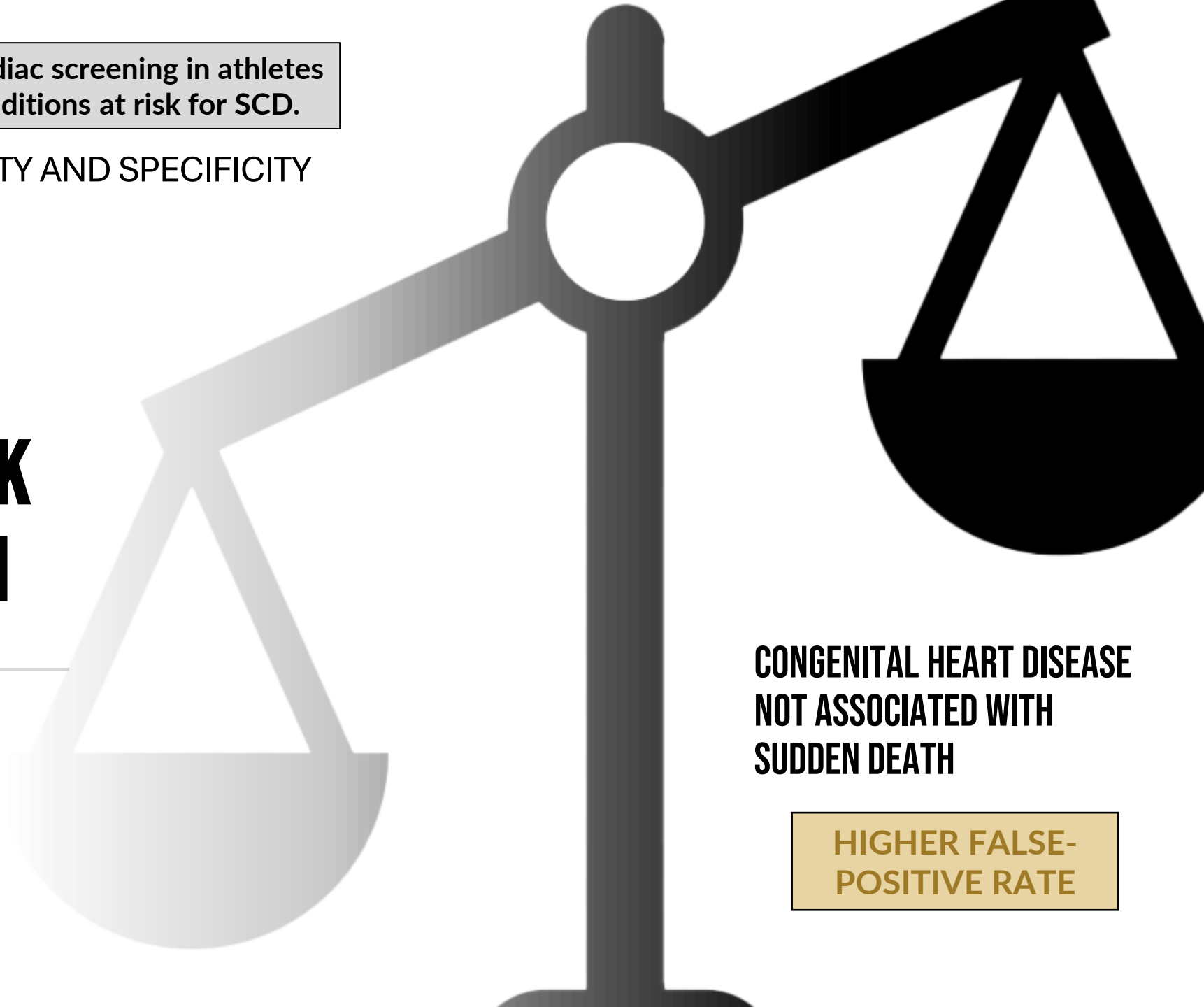
BALANCING SENSITIVITY AND SPECIFICITY

CONDITIONS AT RISK FOR SUDDEN DEATH

“RED BOX” ECG ABNORMALITIES

CONGENITAL HEART DISEASE NOT ASSOCIATED WITH SUDDEN DEATH

HIGHER FALSE-POSITIVE RATE



2005

ESC Report

Cardiovascular pre-participation screening of young competitive athletes for prevention of sudden death: proposal for a common European protocol

Consensus of the European Society of Cardiology

Domenico Alessandrini, Asterios Deodato, Hein Heidbuchel, Cristina M. Williams

“The main purposes of the consensus document are (i) to reinforce the principle... of the need for pre participation medical clearance of all young competitive athletes involved in organized sports programmes... to identify hypertrophic cardiomyopathy (HCM) and to prevent sudden death;...”

2020

ESC European Heart Journal (2021) 42, 17–96
European Society of Cardiology doi:10.1093/eurheartj/ehaa605

ESC GUIDELINES

2020 ESC Guidelines on sports cardiology and exercise in patients with cardiovascular disease

The Task Force on sports cardiology and exercise in patients with cardiovascular disease of the European Society of Cardiology (ESC)

Authors/Task Force Members: Antonio Pelliccia* (Chairperson) (Italy), Sanjay Sharma* (Chairperson) (United Kingdom), Sabiha Gati (United Kingdom), Maria Bäck (Sweden), Mats Börjesson (Sweden), Stefano Caselli (Switzerland), Jean-Philippe Collet (France), Hein Heidbuchel (Belgium), Josef Niebauer (Austria), Massimo Francesco Piepoli (Italy), Jolien W. Roos-Hesselink (Netherlands), Rod S. Taylor (United Kingdom), Monica Tiberi (Italy), Lucretia Vanhees (Belgium),

“Pre-participation CV screening aimed at the detection of disorders associated with SCD is universally supported by major medical societies.”

2014

AHA/ACC Scientific Statement

Assessment of the 12-Lead ECG as a Screening Test for Detection of Cardiovascular Disease in Healthy General Populations of Young People (12–25 Years of Age)

A Scientific Statement From the American Heart Association and the American College of Cardiology

G. Arthur ... of the Council on Cardiovascular and Stroke Nursing, Council on Clinical Cardiology, and Council on Population and Prevention

“The present discussion defines cardiovascular screening as an initiative intended to prospectively identify or raise suspicion of previously unrecognized and largely genetic or congenital cardiovascular diseases known to cause sudden cardiac arrest and SD in young people.”

2025

AHA/ACC SCIENTIFIC STATEMENT

Clinical Considerations for Competitive Sports Participation for Athletes With Cardiovascular Abnormalities: A Scientific Statement From the American Heart Association and American College of Cardiology

Jonathan H. Kim, MD, MSc, FACC, Chair; Aaron L. Baggish, MD, FACC; Michael J. Ackerman, MD, PhD, FACC; Sharlene M. Day, MD, FAHA; J. Sawalla Guseh II, MD; Andre La Gerche, MBBS, PhD; Rachel L. Michael Papadakis, MBBS, MD, FRCP; Dermot M. Phelan, MD, PhD; Heart Association Leadership Committee of the Council on Clinical Cardiology; Council on Cardiovascular and Stroke Nursing; Council on Population and Prevention

“Preparticipation cardiac screening aims to detect cardiovascular conditions that increase the risk of SCA or SCD during competitive sports participation.”

2016

AMSSM Position Statement on Cardiovascular Preparticipation Screening in Athletes: current evidence, knowledge gaps, recommendations and future directions

Jonathan A Drezner,¹ Francis G O'Connor,² Kimberly G Harmon,¹ Karl B Fields,³ Chad A Asplund,⁴ Irfan M Asif,⁵ David E Price,⁶ Robert J Dimeff,⁷

“The primary goal of cardiovascular screening in competitive athletes is to identify underlying cardiac disorders predisposing to sudden cardiac arrest and death (SCA/D) with the intent to reduce morbidity and mortality by mitigating risk through individualised, patient-centred and disease-specific medical management.”

2005

ESC Report

Cardiovascular pre-participation screening of young competitive athletes for prevention of sudden death: proposal for a common European protocol

Consensus of the European Society of Cardiology

Domenico Alessandri, Asterios Deodato, Hein Heidbuchel, Cristina Williams

“The main purposes of the consensus document are (i) to reinforce the principle... of the need for pre participation medical clearance of all young competitive athletes involved in organized sports programmes... to identify hypertrophic cardiomyopathy (HCM) and **to prevent sudden death;...**”

2014

AHA/ACC Scientific Statement

Assessment of the 12-Lead ECG as a Screening Test for Detection of Cardiovascular Disease in Healthy General Populations of Young People (12–25 Years of Age)

A Scientific Statement From the American Heart Association and the American College of Cardiology

G. Arthur of the Council

“The present discussion defines cardiovascular screening as an initiative intended to prospectively identify or raise suspicion of previously unrecognized and largely genetic or congenital cardiovascular diseases known to **cause sudden cardiac arrest and SD** in young people.”

2016

AMSSM Position Statement on Cardiovascular Preparticipation Screening in Athletes: current evidence, knowledge gaps, recommendations and future directions

Jonathan A Drezner,¹ Francis G O'Connor,² Kimberly G Harmon,¹ Karl B Fields,³ Chad A Asplund,⁴ Irfan M Asif,⁵ David E Price,⁶ Robert J Dimeff,⁷

“The primary goal of cardiovascular screening in competitive athletes is to identify underlying **cardiac disorders predisposing to sudden cardiac arrest and death (SCA/D)** with the intent to reduce morbidity and mortality by mitigating risk through individualised, patient-centred and disease-specific medical management.”

2020

ESC European Society of Cardiology

European Heart Journal (2021) 42, 17–96

doi:10.1093/eurheartj/ehaa605

ESC GUIDELINES

2020 ESC Guidelines on sports cardiology and exercise in patients with cardiovascular disease

The Task Force on sports cardiology and exercise in patients with cardiovascular disease of the European Society of Cardiology (ESC)

Authors/Task Force Members: Antonio Pelliccia* (Chairperson) (Italy), Sanjay Sharma* (Chairperson) (United Kingdom), Sabiha Gati (United Kingdom), Maria Bäck (Sweden), Mats Börjesson (Sweden), Stefano Caselli (Switzerland), Jean-Philippe Collet (France), Hein Heidbuchel (Belgium), Josef Niebauer (Austria), Massimo Francesco Piepoli (Italy), Jolien W. Roos-Hesselink (Netherlands), Rod S. Taylor (United Kingdom), Monica Tiberi (Italy), Lucretia

“Pre-participation CV screening aimed **at the detection of disorders associated with SCD** is universally supported by major medical societies.”

2025

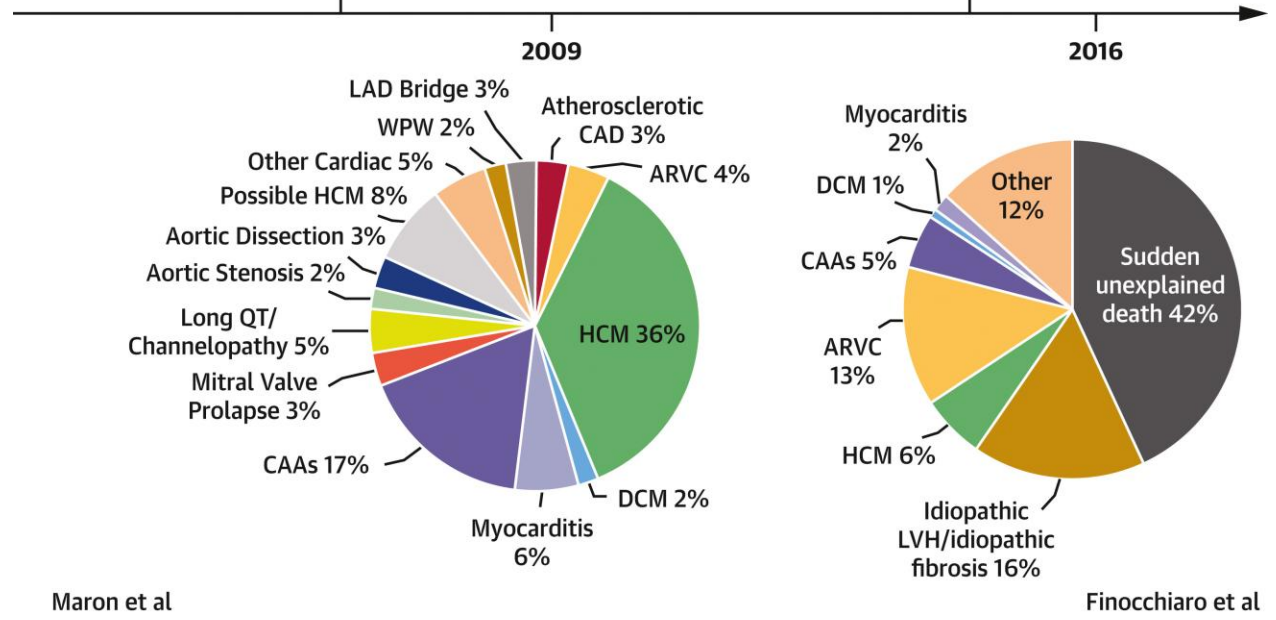
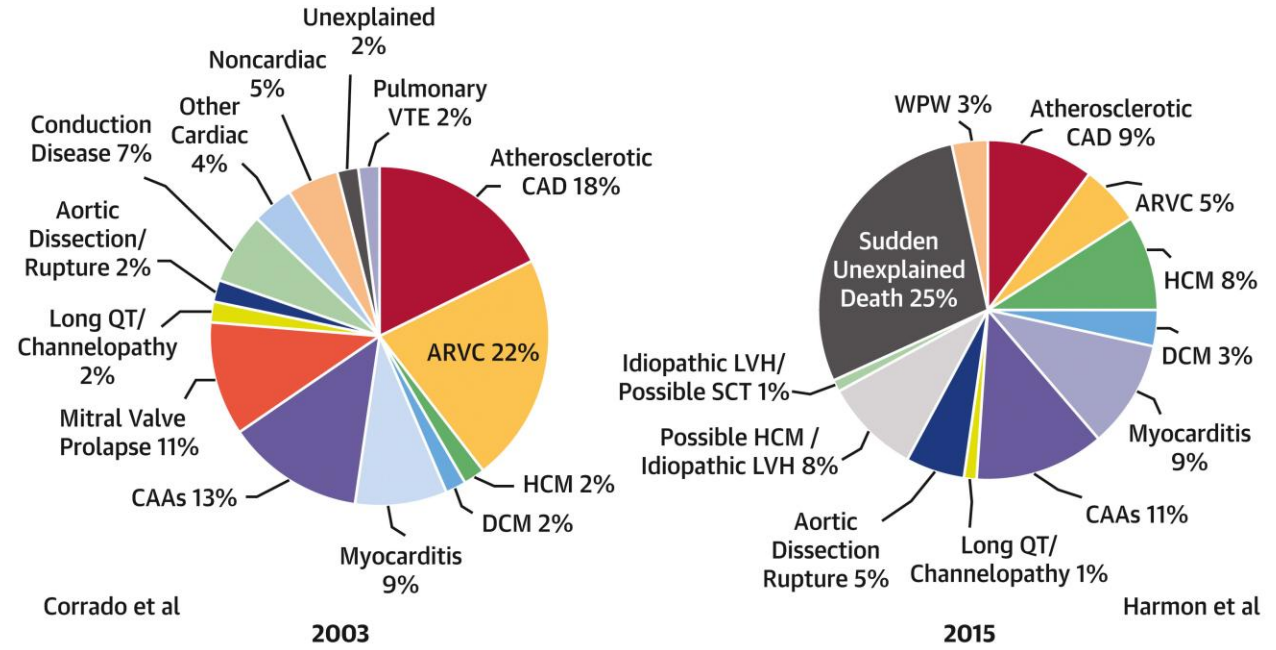
AHA/ACC SCIENTIFIC STATEMENT

Clinical Considerations for Competitive Sports Participation for Athletes With Cardiovascular Abnormalities: A Scientific Statement From the American Heart Association and American College of Cardiology

Jonathan H. Kim, MD, MSc, FACC, Chair; Aaron L. Baggish, MD, FACC; Michael J. Ackerman, MD, PhD, FACC; Sharlene M. Day, MD, FAHA; J. Sawalla Guseh II, MD; Andre La Gerche, MBBS, PhD; Rachel L. Michael Papadakis, MBBS, MD, FRCP; Dermot M. Phelan, MD, PhD; Heart Association Leadership Committee of the Council on Clinical Cardiology; Council on Cardiovascular and Stroke Nursing; Council on Cardiovascular and Stroke Policy

“Preparticipation cardiac screening aims **to detect cardiovascular conditions that increase the risk of SCA or SCD** during competitive sports participation.”

Etiology of SCD in Athletes



JACC STATE-OF-THE-ART REVIEW

Sudden Cardiac Death in Young Athletes

JACC State-of-the-Art Review

Gherardo Finocchiaro, MD, PhD, Joseph Westaby, PhD, MBBS, Mary N. Sheppard, MD, MBBCH, BAO, BSc, Michael Papadakis, MD, MBBS, Sanjay Sharma, MD, BSc(HONS)

Diagnostic Accuracy of the International Criteria for ECG Interpretation in Young Athletes: A Systematic Review and Meta-Analysis

Studies Screened
(n=4215)

Studies Meeting
Inclusion Criteria
(n=33)

Non-Overlapping
(n=29)

- 1) Young athletes 12-35
- 2) IC17 used for interpretation
- 3) Advanced testing for abnormal ECGs

**35,031 Athletes with
PPCS ECG Interpreted
Utilizing International
Criteria**

81% male
60% White; 14.5% Black

Nate
Moulson

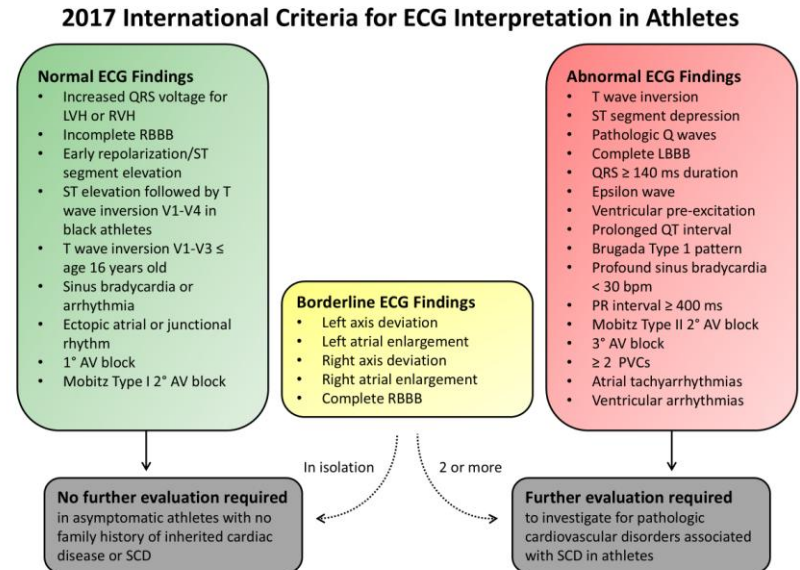


SPORTSCARDIOLOGYBC

RESULTS

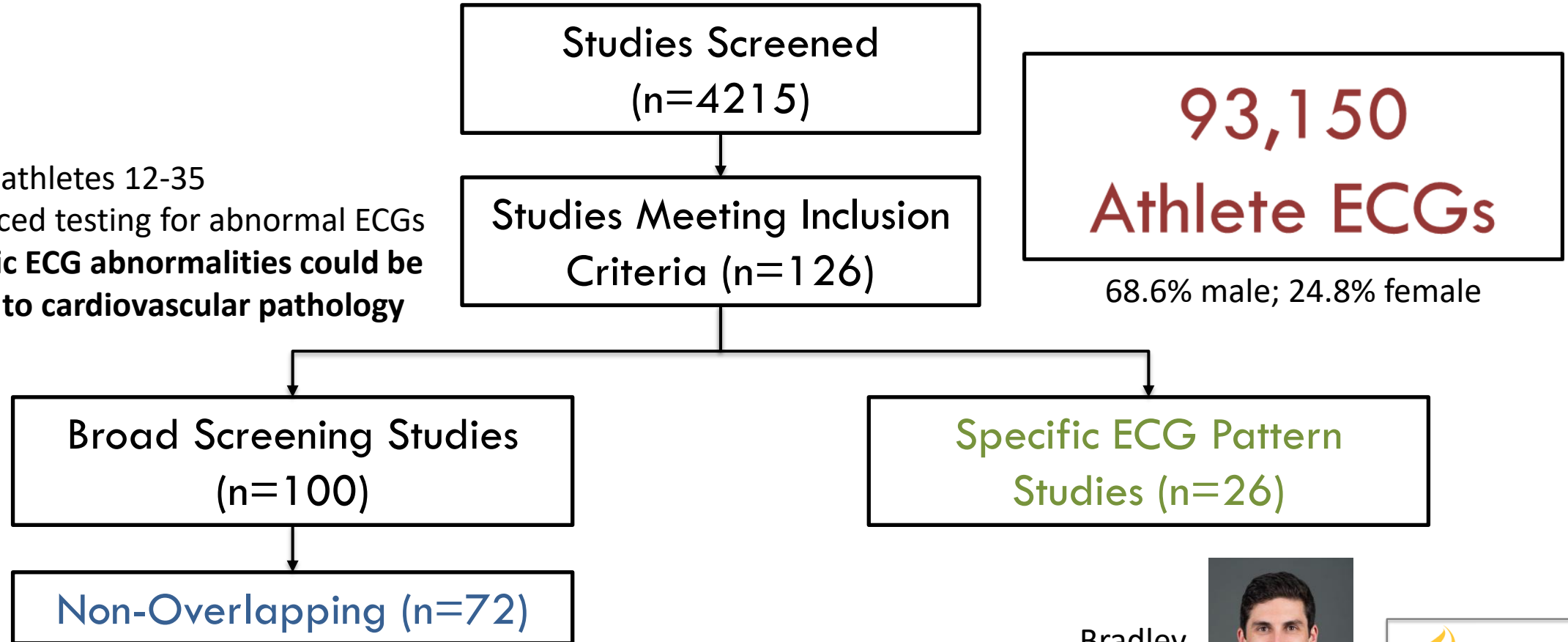
IC17 applied in 35,031 athletes for the detection of cardiovascular conditions associated with SCA/D demonstrates:

1. **Low Total Abnormal ECG rate (2.6%)**
2. **Low False Positive Rate (2.3%)**
3. **High Specificity (97%)**
4. **High Negative Predictive Value (99.9%)**
5. **Moderate Sensitivity (84%)**



Association of Specific ECG Patterns with SCA/D Conditions in Young Athletes: A Systematic Review

- 1) Young athletes 12-35
- 2) Advanced testing for abnormal ECGs
- 3) **Specific ECG abnormalities could be linked to cardiovascular pathology**



Bradley Petek



SCA/D Conditions

Cardiomyopathies/Myocardial/Infiltrative

Hypertrophic cardiomyopathy (HCM)
Arrhythmogenic cardiomyopathy (ACM)
Dilated cardiomyopathy (DCM)
Cardiomyopathy not otherwise specified
Cardiac sarcoidosis
Glycogen storage disease with active myocardial involvement (e.g. Danon disease)
Non-ischemic left ventricular scar*
Other cardiomyopathy/myocardial disease/infiltrative

Arrhythmic Syndromes

Wolff-Parkinson-White (WPW)*
Long QT Syndrome
Brugada Syndrome
Catecholaminergic Polymorphic Ventricular Tachycardia (CPVT)
Idiopathic VT or VF
High degree AV block
Other arrhythmic syndrome

Valvular Heart Disease

Any severe valvular regurgitation
Any \geq moderate valvular stenosis
Mitral valve prolapse with high-risk features*
Bicuspid aortic valve with aortopathy

Coronary Artery Disease

Anomalous coronary arteries with high-risk course
 \geq Moderate coronary artery aneurysm
Coronary vasculitis with active involvement
Atherosclerotic CAD with $\geq 70\%$ stenosis

Aortopathies

Idiopathic dilated aortic root, ascending aorta, aortic arch, descending aorta
Marfan's syndrome
Loeys-Dietz syndrome
Vascular Ehlers-Danlos syndrome
Other Hereditary Aortopathy

Congenital Heart Disease

Any \geq moderate outflow tract obstruction
Great complexity congenital heart disease

Borderline Criteria

No Conditions Associated with SCA/D without Other Abnormal Findings

Definitions	Complete RBBB	Right Atrial Enlargement	Left Atrial Enlargement	Right Axis Deviation	Left Axis Deviation	≥ 2 Borderline
Total (n)	249/50,750 (0.50%)	217/33,554 (0.65%)	399/40,718 (0.98%)	405/43,928 (0.92%)	378/49,629 (0.76%)	43/16,430 (0.26%)
Total SCA/D Conditions (n)	0/190 (0%)	0/190 (0%)	0/362 (0%)	2/211 (0.95%)	1/186 (0.54%)	0/43 (0%)
Total SCA/D Condition Details	N/A	N/A	N/A	2 HCM (Q waves + RAD)	1 HCM (TWI + LAD)	N/A
Incidental SCA/D Conditions	N/A	N/A	1 Dilated Aortic Root (Isolated LAE)	N/A	1 BAV w/ severe AR (isolated LAD) 1 BAV w/ aorta (isolated LAD)	N/A

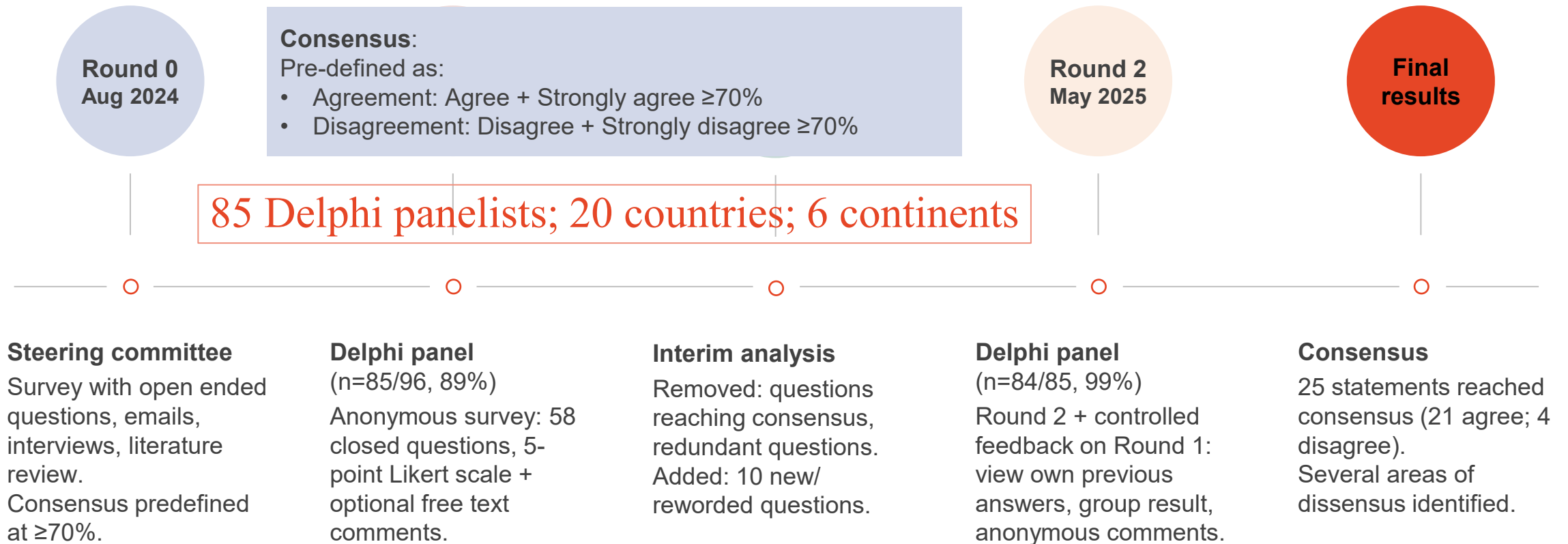
Definitions	Abnormal TWI	Abnormal STD	Pathologic Q waves	Complete LBBB	Non-specific IVCD	Epsilon Wave
Total (n)	1203/63,867 (1.88%)	82/37,412 (0.22%)	222/54,133 (0.41%)	17/51,430 (0.03%)	25/46,381 (0.05%)	3/36,817 (0.008%)
Total SCA/D Conditions (n)	41/1133 (3.62%)	4/81 (4.94%)	7/214 (3.27%)	1/17 (5.88%)	0/25 (0%)	1/3 (33.3%)
Total SCA/D Condition Details	<u>Isolated TWI</u> 17 HCM 5 ACM 5 Myocarditis 2 LVNC 2 NILVS 1 DCM <u>TWI + STD</u> 5 HCM 1 DCM <u>TWI + Q waves</u> 2 HCM 1 LVNC	<u>Isolated STD</u> 1 HCM <u>TWI+STD</u> 2 HCM <u>STD+Long QTc</u> 1 HCM	<u>Isolated Q</u> 4 HCM <u>TWI + Q waves</u> 2 HCM 1 LVNC	1 Myocarditis	N/A	1 ACM
Incidental SCA/D Conditions	1 Severe AR	N/A	1 Dilated Aorta	N/A	N/A	N/A

Improving the International Criteria: An International Modified Delphi Study

Jessica
Orchard



Aim: To inform the 2025 update to the International Criteria



Summary of Delphi results

Informing IC25

Areas of dissensus



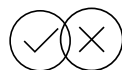TWI (V1-V3) in female / female endurance athletes: normal



“Black athlete repolarisation variant”: rename, normal in all



QTc: use of Fridericia correction as an alternative to Bazett



Borderline (Yellow Box): remove, simplify to normal/abnormal



Recommendation for inclusion of cMRI in evaluation of inferior TWI, deep TWI, ST-depression

Consensus	
Abnormal findings	<ul style="list-style-type: none"> • Single PVC with ≥ 140ms duration OR ≥ 2 PVCs of any morphology • LQRSV, defined as QRS amplitude of < 5mm in all limb leads. Interpret cautiously if $BMI \geq 30$ • Inferior TWI • Complete RBBB with (a) QRS fragmentation in ≥ 2 precordial leads, (b) left axis deviation, OR (c) QRS duration ≥ 140ms • QRS fragmentation with IVCD ≥ 140ms
Normal findings	<ul style="list-style-type: none"> • Left and right atrial enlargement
International criteria age range	<ul style="list-style-type: none"> • Can be applied for athletes > 35 years with additional considerations for ischaemic heart disease • Cannot be applied for athletes < 12 years
Further evaluation	<ul style="list-style-type: none"> • LQRSV: echocardiogram, stress ECG, consider cMRI • WPW: echocardiogram, referral to electrophysiologist to consider EP study • An athlete with abnormal ECG should be temporarily restricted under limited circumstances depending on abnormality/context



INTERNATIONAL SUMMIT

ECG INTERPRETATION IN ATHLETES

IC25

2017 International Criteria for ECG Interpretation in Athletes

Normal ECG Findings

- Increased QRS voltage for LVH or RVH
- Incomplete RBBB
- Early repolarization/ST segment elevation
- ST elevation followed by T wave inversion V1-V4 in black athletes
- T wave inversion V1-V3 \leq age 16 years old
- Sinus bradycardia or arrhythmia
- Ectopic atrial or junctional rhythm
- 1° AV block
- Mobitz Type I 2° AV block

Borderline ECG Findings

- Left axis deviation
- Left atrial enlargement
- Right axis deviation
- Right atrial enlargement
- Complete RBBB

Abnormal ECG Findings

- T wave inversion
- ST segment depression
- Pathologic Q waves
- Complete LBBB
- QRS \geq 140 ms duration
- Epsilon wave
- Ventricular pre-excitation
- Prolonged QT interval
- Brugada Type 1 pattern
- Profound sinus bradycardia $<$ 30 bpm
- PR interval \geq 400 ms
- Mobitz Type II 2° AV block
- 3° AV block
- \geq 2 PVCs
- Atrial tachyarrhythmias
- Ventricular arrhythmias

No further evaluation required
in asymptomatic athletes with no family history of inherited cardiac disease or SCD

In isolation

2 or more

Further evaluation required
to investigate for pathologic cardiovascular disorders associated with SCD in athletes

2017 International Criteria for ECG Interpretation in Athletes

Normal ECG Findings

- Increased QRS voltage for LVH or RVH
- Incomplete RBBB
- Early repolarization/ST segment elevation
- ST elevation followed by T wave inversion V1-V4 in **black** athletes
- T wave inversion V1-V3 \leq age 16 years old
- Sinus bradycardia or arrhythmia
- Ectopic atrial or junctional rhythm
- 1° AV block
- Mobitz Type I 2° AV block

Borderline ECG Findings

- Left axis deviation
- **Left atrial enlargement**
- Right axis deviation
- **Right atrial enlargement**
- **Complete RBBB**

Abnormal ECG Findings

- T wave inversion
- ST segment depression
- Pathologic Q waves
- Complete LBBB
- QRS \geq 140 ms duration
- **Epsilon wave**
- Ventricular pre-excitation
- Prolonged QT interval
- Brugada Type 1 pattern
- **Profound sinus bradycardia < 30 bpm**
- PR interval \geq 400 ms
- Mobitz Type II 2° AV block
- 3° AV block
- \geq 2 PVCs
- Atrial tachyarrhythmias
- Ventricular arrhythmias

No further evaluation required
in asymptomatic athletes with no family history of inherited cardiac disease or SCD

In isolation

2 or more

Further evaluation required
to investigate for pathologic cardiovascular disorders associated with SCD in athletes

2025 International Criteria for ECG Interpretation in Athletes

DRAFT

NO FURTHER EVALUATION

ECG findings that are training-related or variants not generally associated with conditions at risk for SCD

- Increased QRS voltage for LVH or RVH
- Sinus bradycardia ≥ 30 bpm
- Sinus arrhythmia
- 1° AV block PR interval < 400 ms
- Mobitz Type I 2° AV block
- Ectopic atrial or junctional rhythm
- Premature atrial contractions
- Incomplete or complete RBBB < 140 ms
- Non-specific IVCD < 140 ms
- Left or right atrial enlargement
- Early repolarization/ST segment elevation
- Juvenile TWI V1-V3 (< 16 years)
- Male athlete repolarization variant (J-point and convex ST elevation followed by TWI confined to V1-V4)

MAY REQUIRE EVALUATION

ECG findings have an unclear relationship with conditions at risk for SCD

- Female athlete TWI V1-V3 (≥ 16 years)
- Inferior TWI
- Low QRS voltage
- 1 PVC with inferior axis
- Axis deviation

FURTHER EVALUATION

ECG findings that are associated with conditions at risk for SCD

- Lateral, inferolateral, or anterolateral TWI
- Anterior TWI (excluding green and yellow box patterns)
- ST segment depression
- Pathologic Q waves
- Complete LBBB
- Complete RBBB or IVCD ≥ 140 ms
- ≥ 2 PVCs of any morphology
- 1 PVC with non-inferior axis or short-coupling
- Ventricular pre-excitation
- Prolonged QTc interval
- Brugada Type 1 pattern
- PR interval ≥ 400 ms
- Mobitz Type II 2° AV block
- 3° AV block
- Atrial or ventricular tachyarrhythmias

Are there ≥ 2 'yellow box' findings or concerning personal or family history?

No

Yes

No further evaluation required

in asymptomatic athletes with no family history of inherited cardiac disease or SCD

Further evaluation required

to investigate for pathologic cardiovascular disorders associated with SCD in athletes

2025 International Criteria for ECG Interpretation in Athletes

DRAFT

NO FURTHER EVALUATION

ECG findings that are training-related or variants not generally associated with conditions at risk for SCD

- Increased QRS voltage for LVH or RVH
- Sinus bradycardia ≥ 30 bpm
- Sinus arrhythmia
- 1° AV block PR interval < 400 ms
- Mobitz Type I 2° AV block
- Ectopic atrial or junctional rhythm
- Premature atrial contractions
- Incomplete or complete RBBB < 140 ms
- Non-specific IVCD < 140 ms
- Left or right atrial enlargement
- Early repolarization/ST segment elevation
- Juvenile TWI V1-V3 (< 16 years)
- Male athlete repolarization variant (J-point and convex ST elevation followed by TWI confined to V1-V4)

MAY REQUIRE EVALUATION

ECG findings have an unclear relationship with conditions at risk for SCD

- Female athlete TWI V1-V3 (≥ 16 years)
- Inferior TWI
- Low QRS voltage
- 1 PVC with inferior axis
- Axis deviation

FURTHER EVALUATION

ECG findings that are associated with conditions at risk for SCD

- Lateral, inferolateral, or anterolateral TWI
- Anterior TWI (excluding green and yellow box patterns)
- ST segment depression
- Pathologic Q waves
- Complete LBBB
- Complete RBBB or IVCD ≥ 140 ms
- ≥ 2 PVCs of any morphology
- 1 PVC with non-inferior axis or short-coupling
- Ventricular pre-excitation
- Prolonged QTc interval
- Brugada Type 1 pattern
- PR interval ≥ 400 ms
- Mobitz Type II 2° AV block
- 3° AV block
- Atrial or ventricular tachyarrhythmias

Are there ≥ 2 'yellow box' findings or concerning personal or family history?

No

Yes

No further evaluation required

in asymptomatic athletes with no family history of inherited cardiac disease or SCD

Further evaluation required

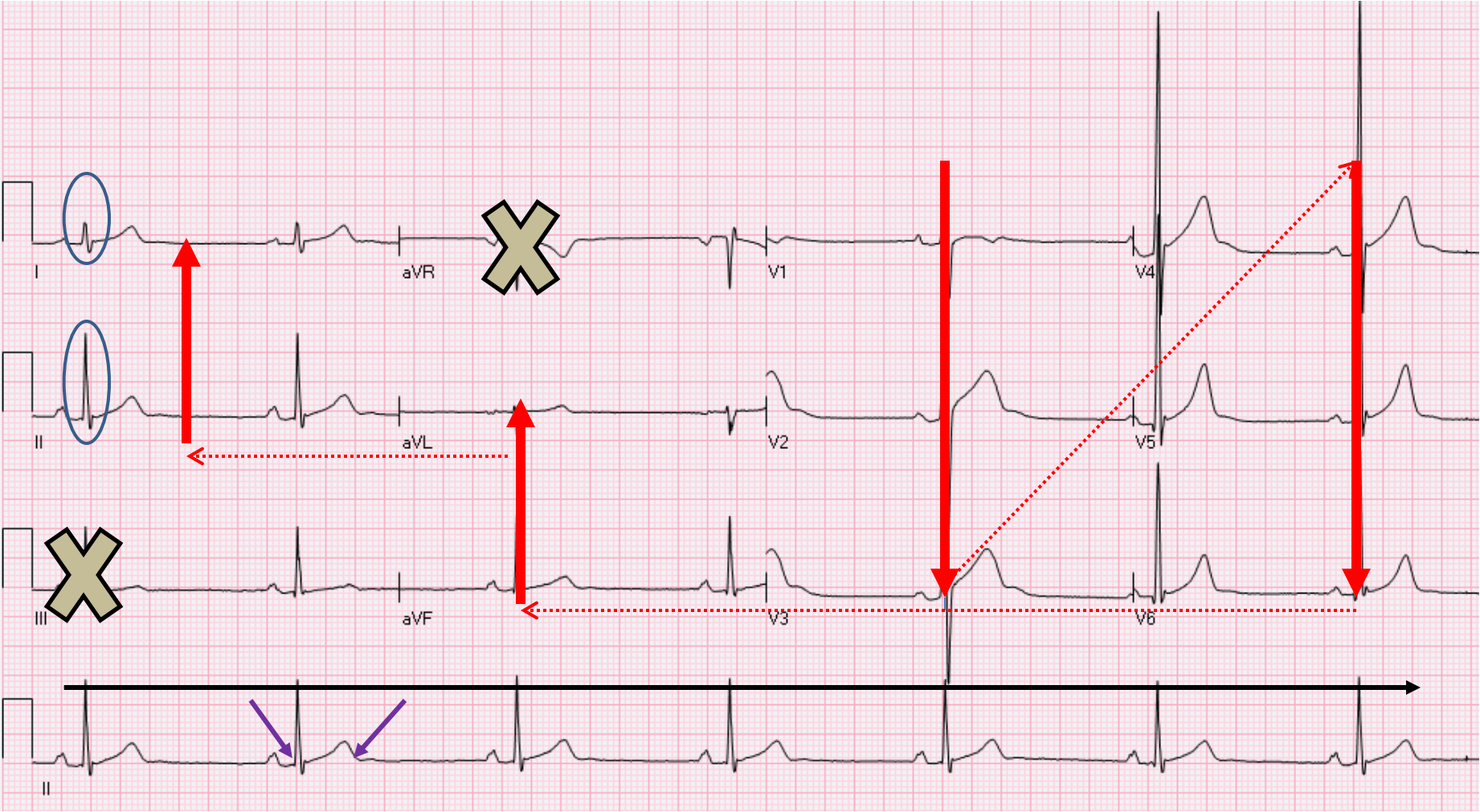
to investigate for pathologic cardiovascular disorders associated with SCD in athletes

5-Steps to Accurate
ECG Interpretation in
Athletes

5-Steps to ECG Interpretation in Athletes

Where to look?	What to look for?
1. Precordial (V1-V6) then limb leads (aVF, aVL, II, I)	Q waves, ST depression, T wave inversion
2. Precordial (V1-V6) then limb leads (aVF, aVL, II, I)	QRS morphology: <ul style="list-style-type: none">• Pre-excitation (delta wave; short PR)• Left bundle branch block• Conduction delay (QRS ≥ 140 ms)• Brugada type 1• Low QRS voltage (≤ 5 mm in all 6 limb leads)
3. Axis – limb leads I and II	QRS pos in I and II (leftward to -30°) QRS neg in I and aVR, pos in II (rightward to 120°) LAD, RAD, or Northwest axis
4. Rhythm strip – lead II or V5	QRS after every P wave PVCs (non-inferior axis or short-coupling)
5. QT interval – lead II or V5	QTc ≥ 470 ms males or ≥ 480 ms females

5-Steps to ECG Interpretation in Athletes

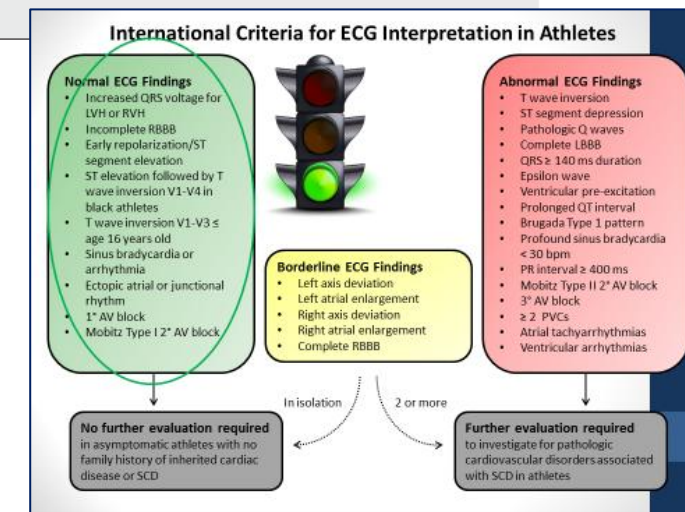


Definitions: Normal ECG Findings

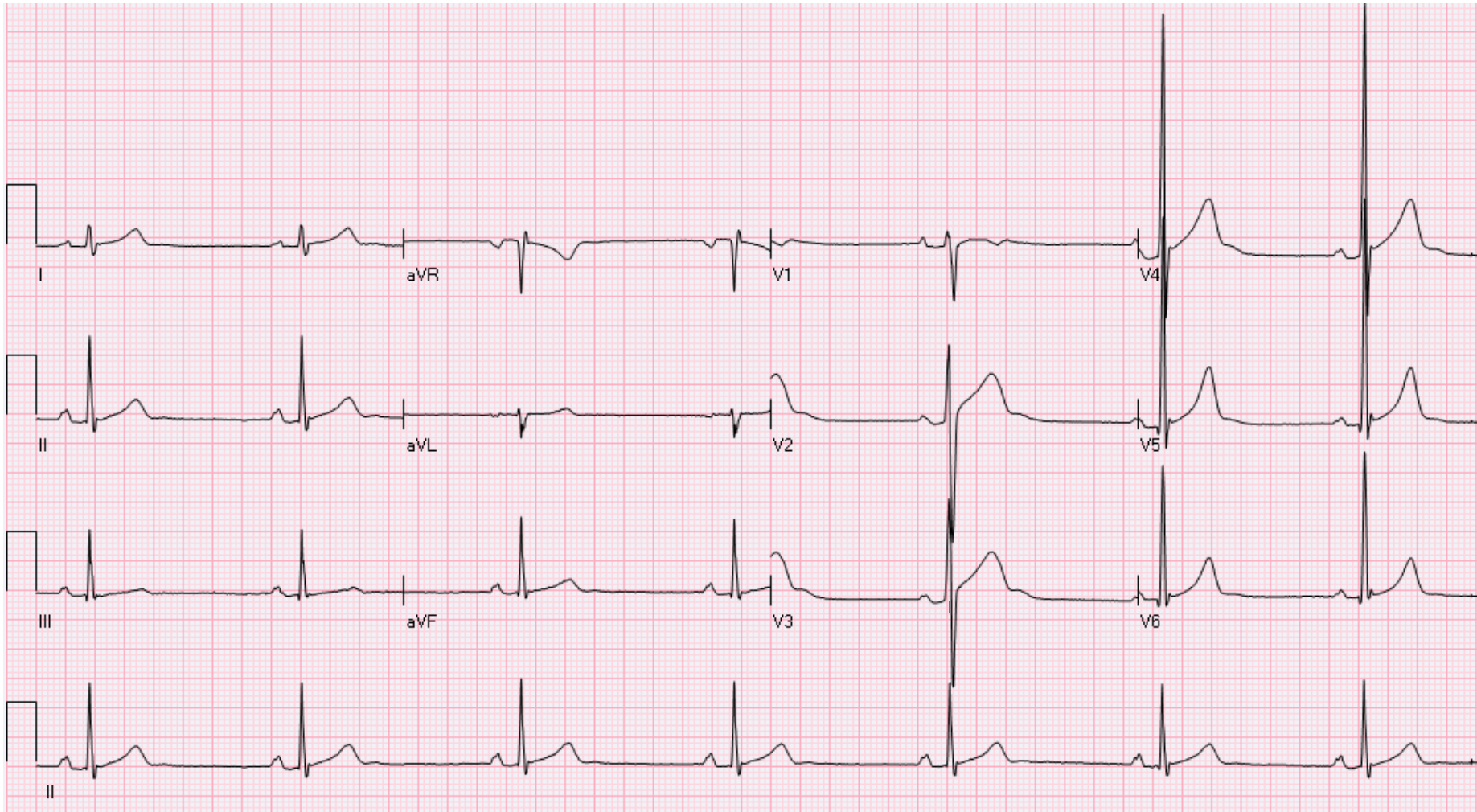
Normal ECG findings in athletes

These training-related ECG alterations are physiological adaptations to regular exercise, considered normal variants in athletes and do not require further evaluation in asymptomatic athletes with no significant family history.

Normal ECG finding	Definition
Increased QRS voltage	Isolated QRS voltage criteria for left (SV1 + RV5 or RV6 >3.5 mV) or right ventricular hypertrophy (RV1 + SV5 or SV6 >1.1 mV)
Incomplete right bundle branch block	rSR' pattern in lead V1 and a qRS pattern in lead V6 with QRS duration <120 ms
Early repolarisation	J point elevation, ST elevation, J waves or terminal QRS slurring in the inferior and/or lateral leads
Black athlete repolarisation variant	J-point elevation and convex ('domed') ST segment elevation followed by T wave inversion in leads V1-V4 in black athletes
Juvenile T wave pattern	T wave inversion V1-V3 in athletes less than age less than 16
Sinus bradycardia	≥30 bpm
Sinus arrhythmia	Heart rate variation with respiration: rate increases during inspiration and decreases during expiration
Ectopic atrial rhythm	P waves are a different morphology compared with the sinus P wave, such as negative P waves in the inferior leads ('low atrial rhythm')
Junctional escape rhythm	QRS rate is faster than the resting P wave or sinus rate and typically less than 100 beats/min with narrow QRS complex unless the baseline QRS is conducted with aberrancy
1° atrioventricular block	PR interval 200–400 ms
Mobitz type I (Wenckebach) 2° atrioventricular block	PR interval progressively lengthens until there is a non-conducted P wave with no QRS complex; the first PR interval after the dropped beat is shorter than the last conducted PR interval



Step-1: ECG Interpretation in Athletes



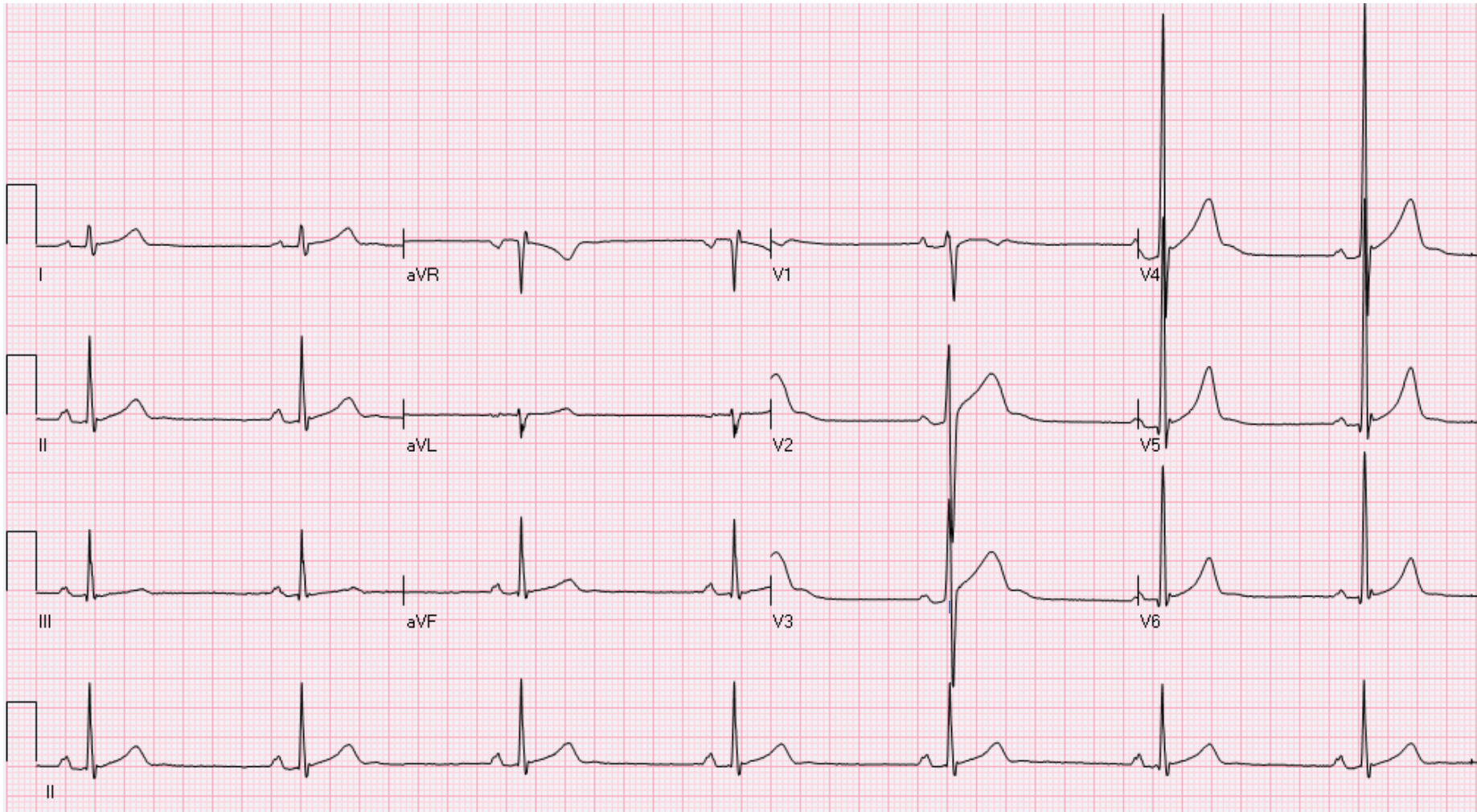
Where to look?

1. Precordial (V1-V6) then limb leads (aVF, aVL, II, I)

What to look for?

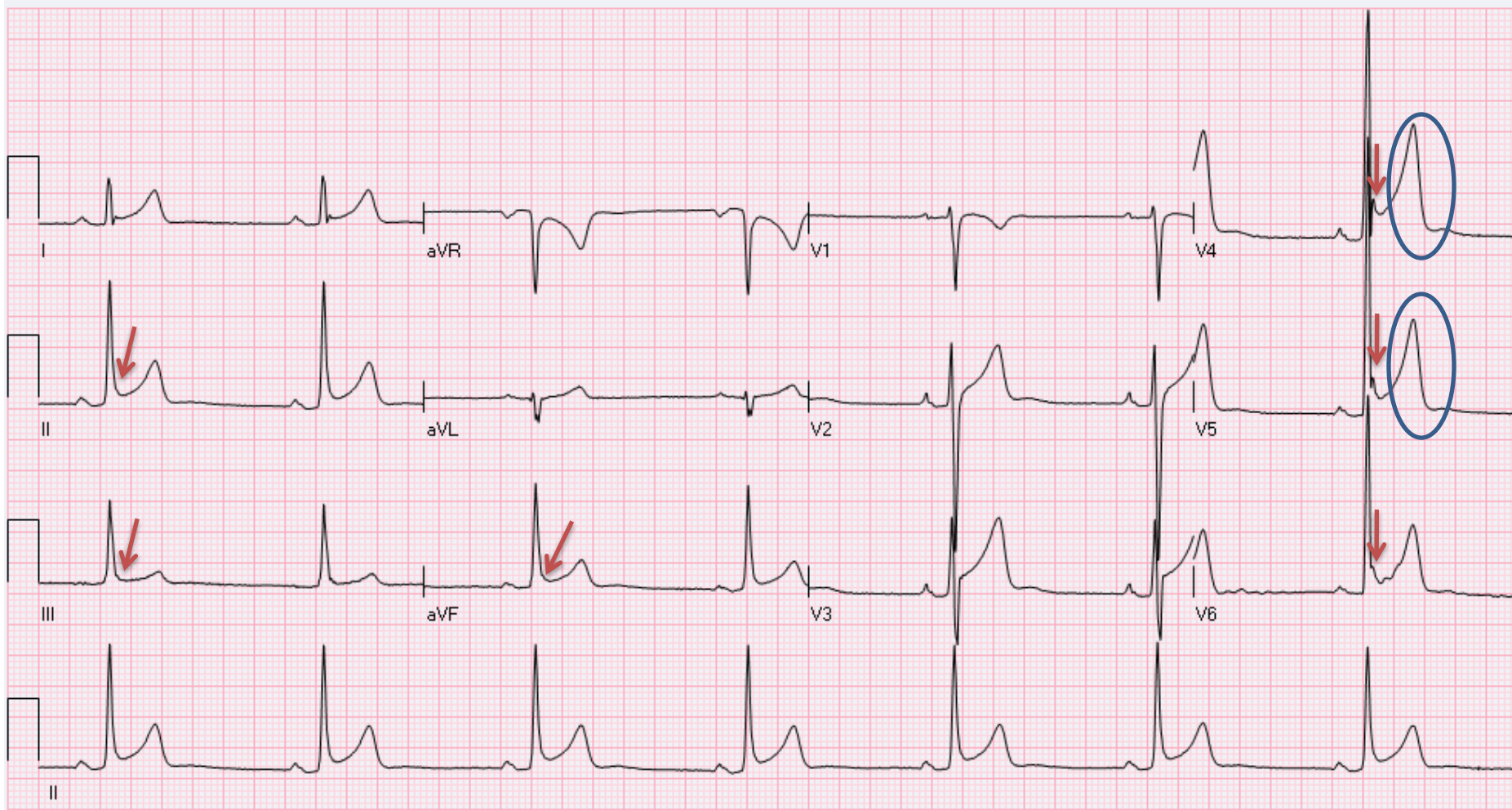
Q waves, ST depression, T wave inversion

Isolated Increased QRS Voltage



ECG from a 19 year old asymptomatic soccer player demonstrating voltage criteria for LVH ($S-V1 + R-V5 > 35$ mm). Note the absence of ST depression, T wave inversion, or pathologic Q waves. Increased QRS amplitude without other ECG abnormalities is a common finding in trained athletes and does not require additional testing.

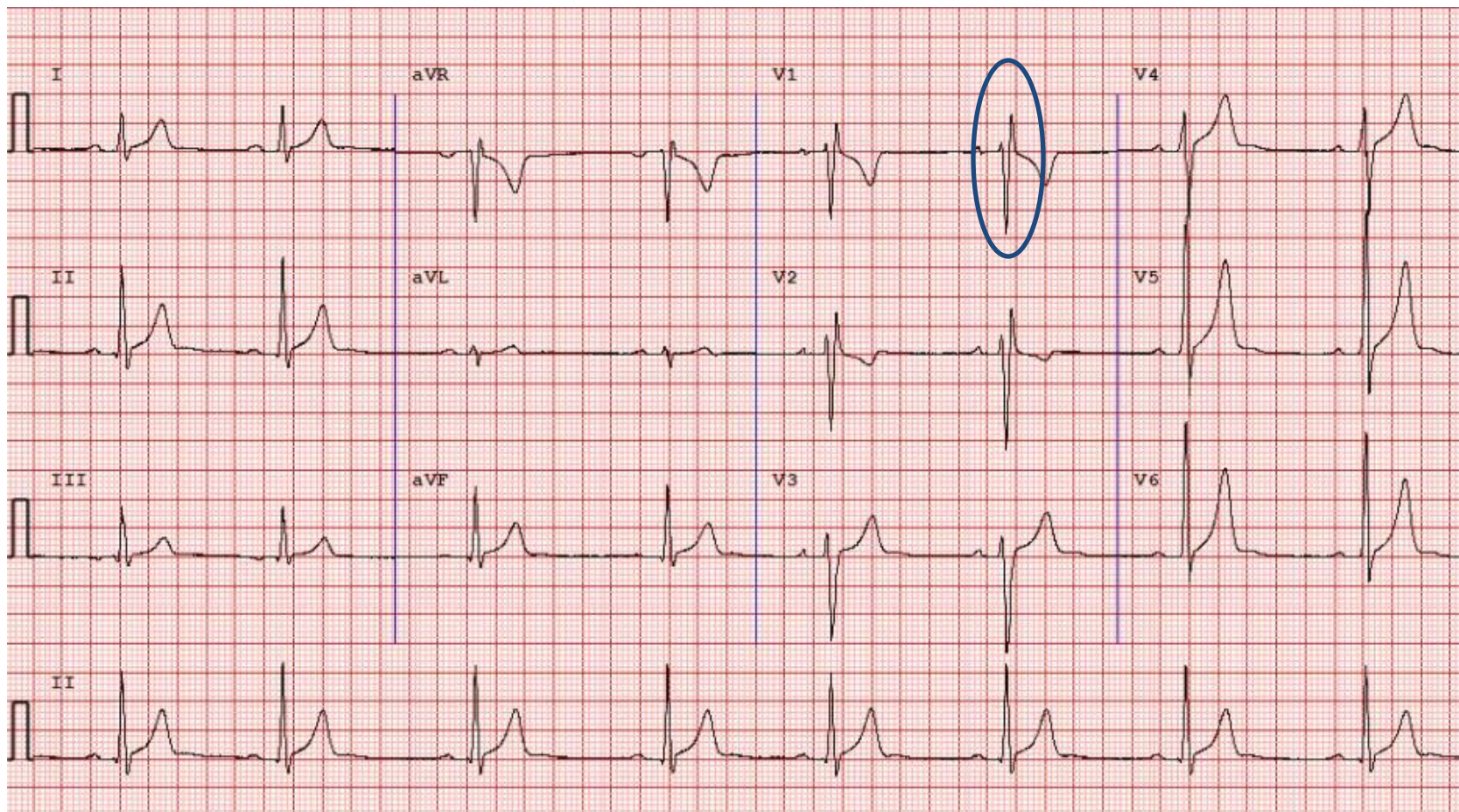
Early Repolarization



ECG from a 29 year old asymptomatic soccer player demonstrating early repolarization (J-point and ST elevation) in II, III, aVF, V4-V6 (arrows) and tall, peaked T-waves (circles). These are common, training related findings in athletes and do not require more evaluation.

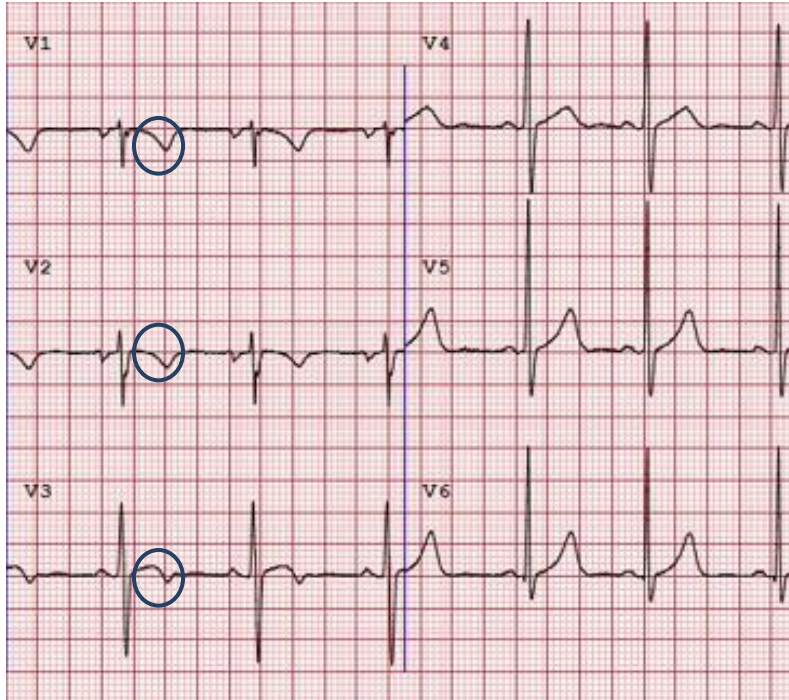
Incomplete Right Bundle Branch Block

- rSR' pattern in lead V1
- QRS duration <120 ms

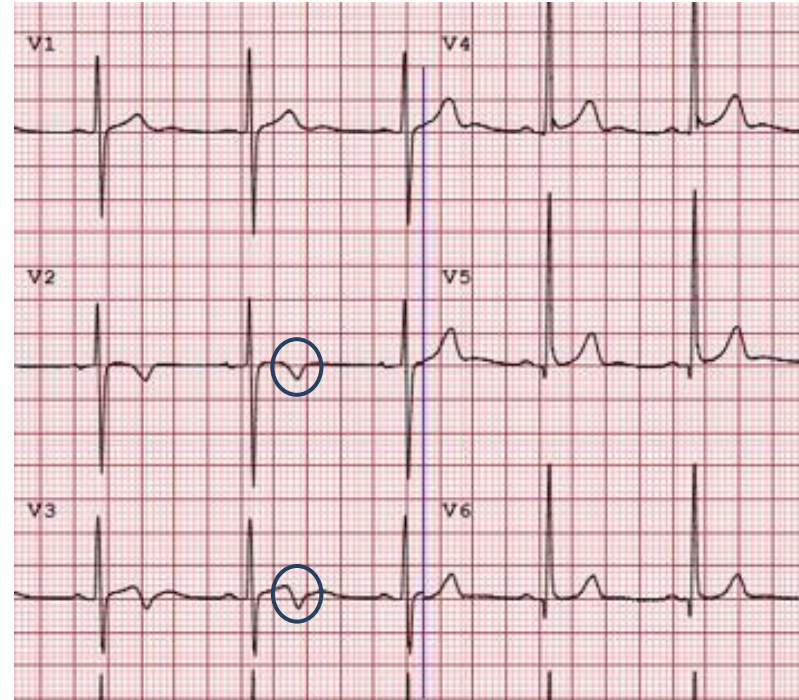


Juvenile T Wave Inversion

Age <16 yo; Independent of race; TWI in V1-V3; Does not extend to V4



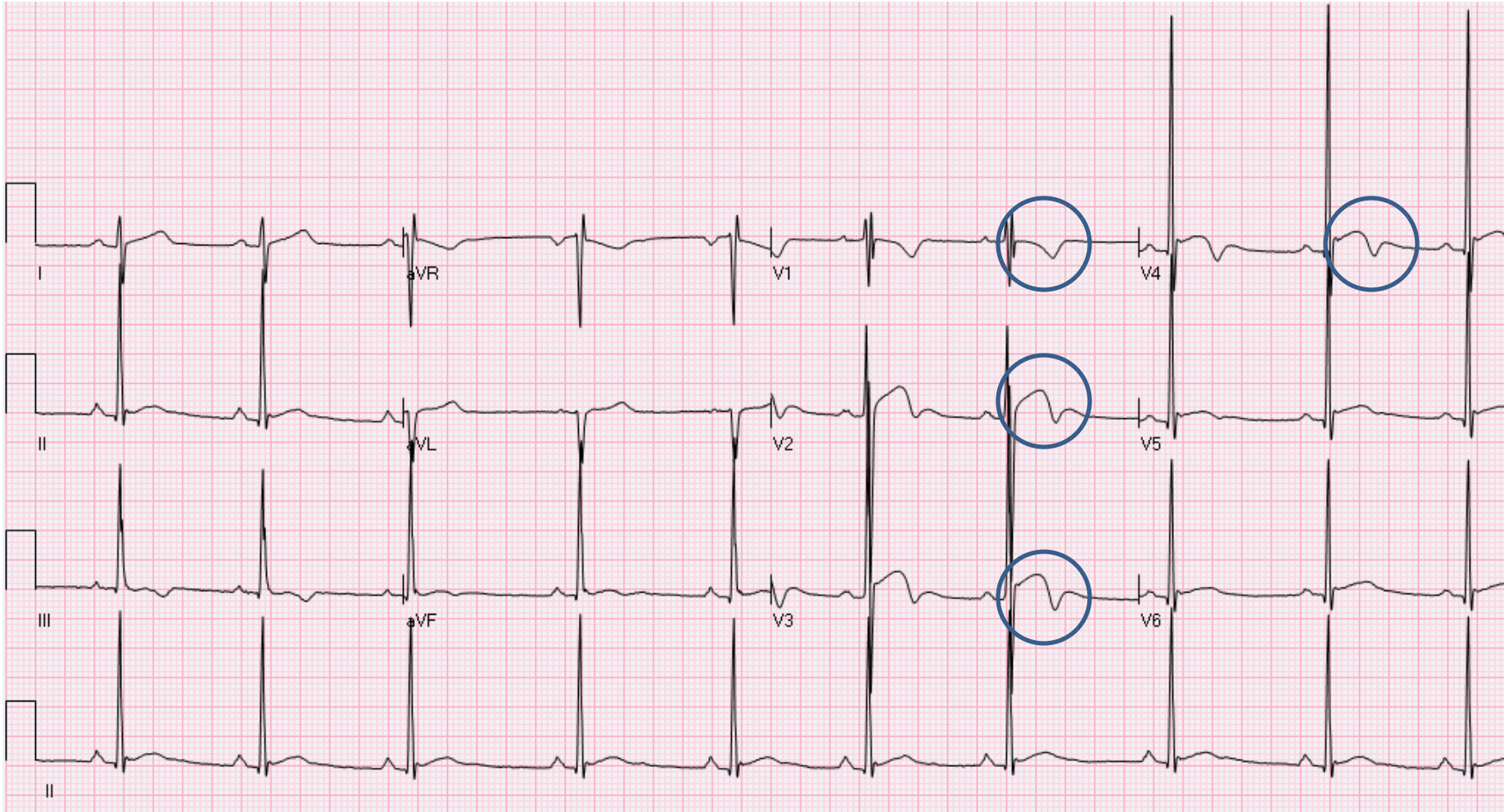
13 yo Caucasian female



15 yo Asian female

No further evaluation needed

~~Black~~ Athlete Repolarization Variant



ECG from a 24 year old asymptomatic black/African soccer player demonstrating **J-point elevation, convex ('domed') ST elevation followed by T wave inversion in leads V1-V4** (circles). This is a normal repolarization pattern in black/African athletes.



Electrocardiographic anterior T-wave inversion in athletes of different ethnicities: differential diagnosis between athlete's heart and cardiomyopathy

Chiara Calore^{1†}, Alessandro Zorzi^{1†}, Nabeel Sheikh^{2†}, Alberto Nese¹,
Monica Facci¹, Aneil Malhotra², Abbas Zaidi², Maurizio Schiavon³,
Antonio Pelliccia⁴, Sanjay Sharma^{2‡}, and Domenico Corrado^{1‡*}

- **Background:**

- Anterior TWI is a recognized variant in athletes of African/Afro Caribbean origin

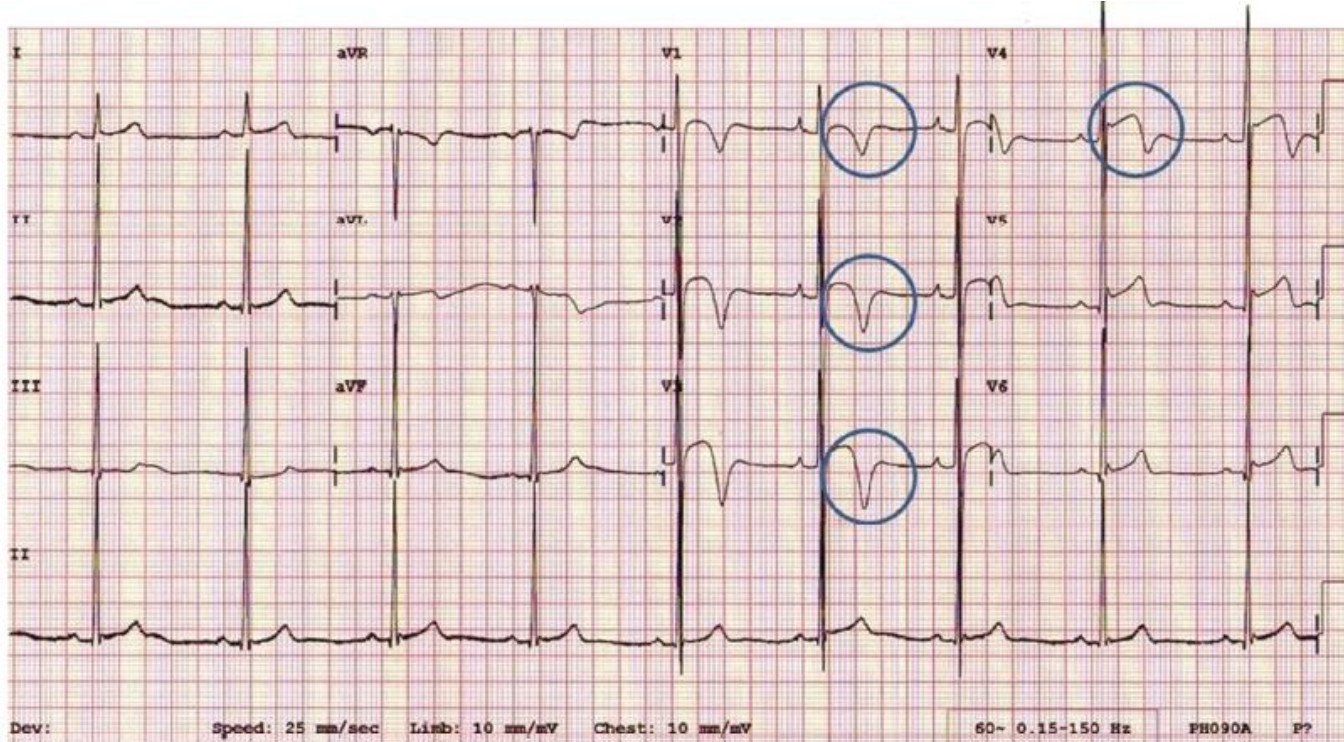
- **Study population:**

- 80 healthy athletes (median age 21 years, 75% males, 66% black)
- 95 patients with HCM (median age 46 years, 75% males, 56% white)
- 58 patients with ARVC (median age 32 years, 71% males, 95% white)

- **Results:**

- **In athletes with anterior TWI, the combination of J-point elevation ≥ 1 mm and TWI not extending beyond V4 excluded a cardiomyopathy, with 100% sensitivity and 55% specificity**
- J-point elevation < 1 mm in anterior leads with TWI was an independent predictor of disease: ARVC (OR=569, $P < 0.001$); HCM OR=227, $P < 0.001$)
- TWI extending beyond V4 was an independent predictor of disease: ARVC (OR=6.0, $P < 0.03$), HCM (OR=331, $P = 0.001$)

Anterior repolarisation variants in athletes: new data from Qatar



International criteria for electrocardiographic interpretation in athletes. Drezner 2017

Anterior TWI V2-4 with
upsloping STE
(isolated or with normal ECG findings):

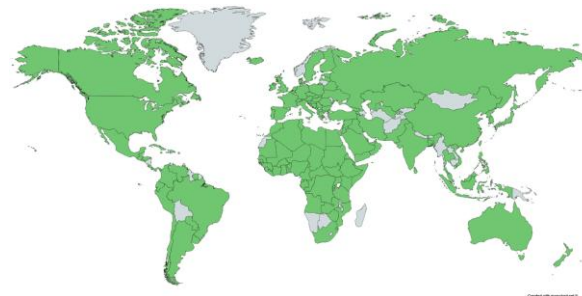65* / 7,712 [0.9%]
(*visit one)

No cardiac pathology
identified

Athletes from 151 countries



Mathew
Wilson



	History		Exam	STE aTWI	ECG Other	Follow up examination	Time of diagnosis
	Syp	FH					
Cardiomyopathy	-ve	-ve	-ve	V2-4	Q wave, Lateral TWI	cMRI: borderline	1 year FU
Cardiomyopathy	-ve	+ve	-ve	V3-4	Inferolateral TWI, STd	cMRI: borderline	4 year FU
Cardiomyopathy	-ve	-ve	+ve	V2-4	Inferolateral TWI, STd	cMRI: Abnormal	1 st screen
Cardiomyopathy	-ve	-ve	+ve	V2-4	Inferolateral TWI, STd, long QTc	cMRI: Abnormal	1 st screen
Cardiomyopathy (Known)	-ve	+ve	-ve	V2-4	Inferolateral TWI, STd	Known HCM	1 st screen
Channelopathy	-ve	-ve	-ve	V2-3	Long QTc	Provocation	1 st screen
Myocarditis	-ve	-ve	-ve	V2-3	Inferior TWI	cMRI: Abnormal	1 st screen
Myocarditis	-ve	-ve	-ve	V2-4	Inferolateral TWI	cMRI: Abnormal	7 year FU
Myocarditis	-ve	-ve	+ve	V3-4	Inferolateral TWI	cMRI: Abnormal	5 year FU
Valvular Disease	-ve	+ve	+ve	V3-4	N/A	Echo: Abnormal	1 st screen
Non-diagnostic but suspicious of cardiomyopathy	+ve	+ve	-ve	V2-4	Inferolateral TWI	cMRI: borderline	1 st screen
Non-diagnostic but suspicious of cardiomyopathy	-ve	-ve	-ve	V2-4	Inferolateral TWI, STd	cMRI: borderline	2 year FU
Non-diagnostic but suspicious of cardiomyopathy	-ve	-ve	-ve	V2-4	Inferolateral TWI, STd	cMRI: Abnormal	1 st screen
Non-diagnostic but suspicious of cardiomyopathy	-ve	-ve	-ve	V2-4	Inferolateral TWI	cMRI: borderline	3 year FU
Non diagnostic but suspicious of cardiomyopathy	-ve	-ve	-ve	V3-4	Inferolateral TWI, STd	cMRI: borderline	1 year FU

Anterior Repolarization Variants: New Data From Brazil



82 clubs

6,125 male football players (aged 15-35)



2,496 White



2,004 Mixed-race

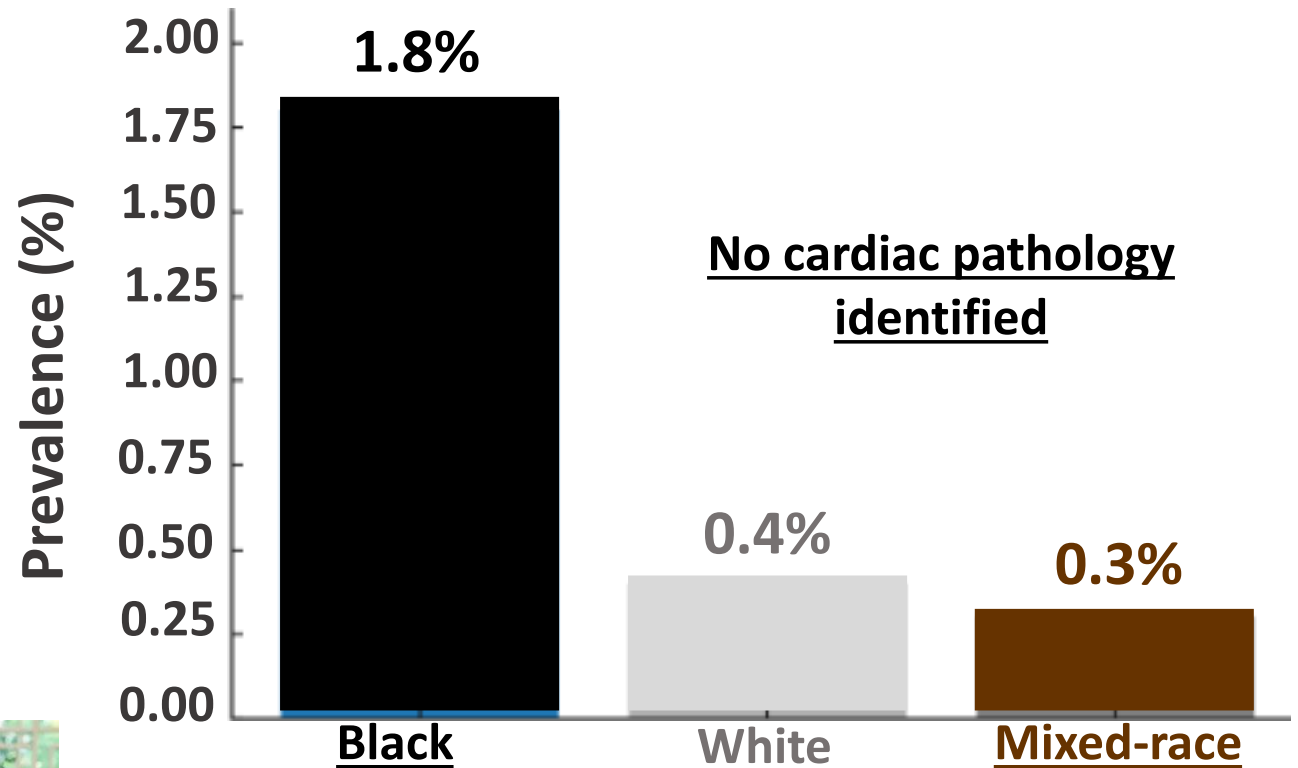


1,625 Black

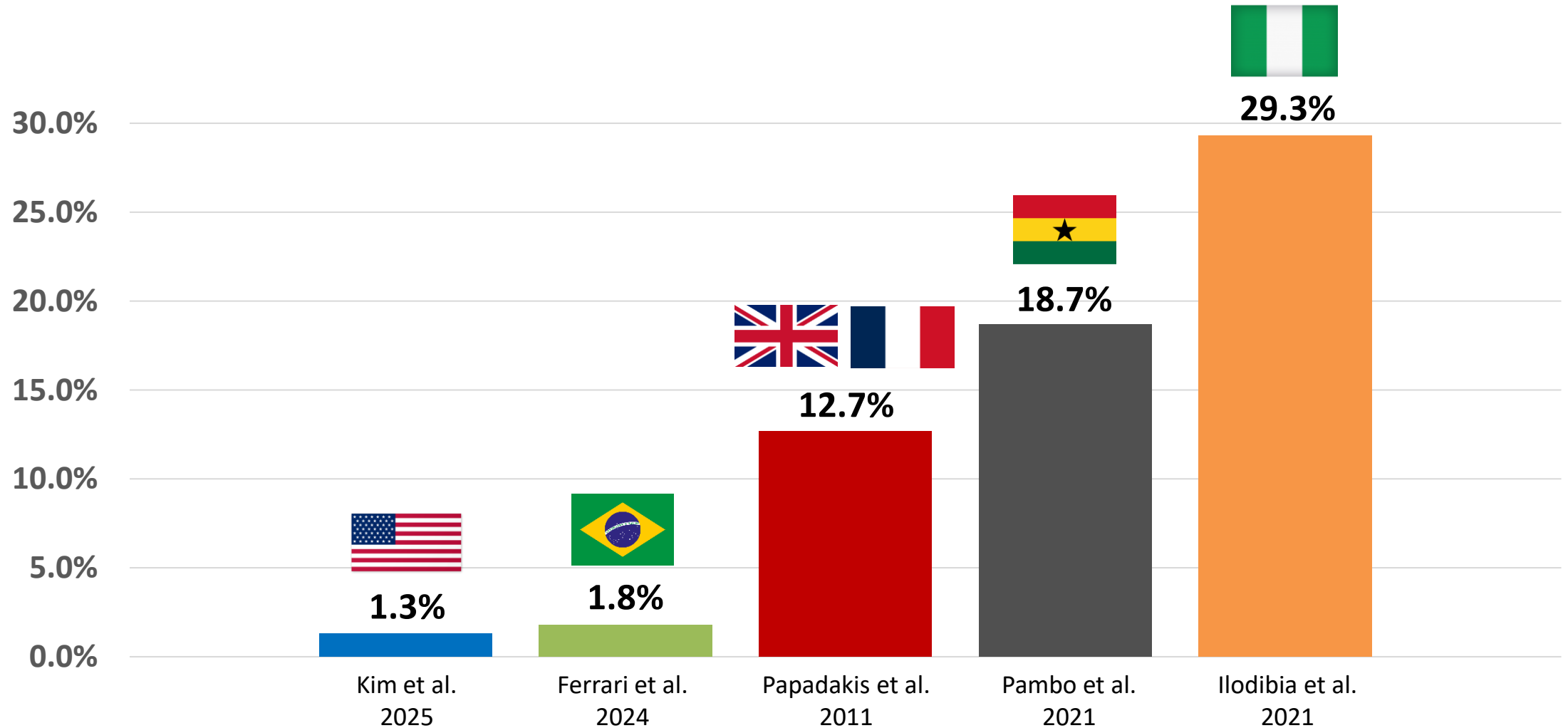
Ricardo
Stein



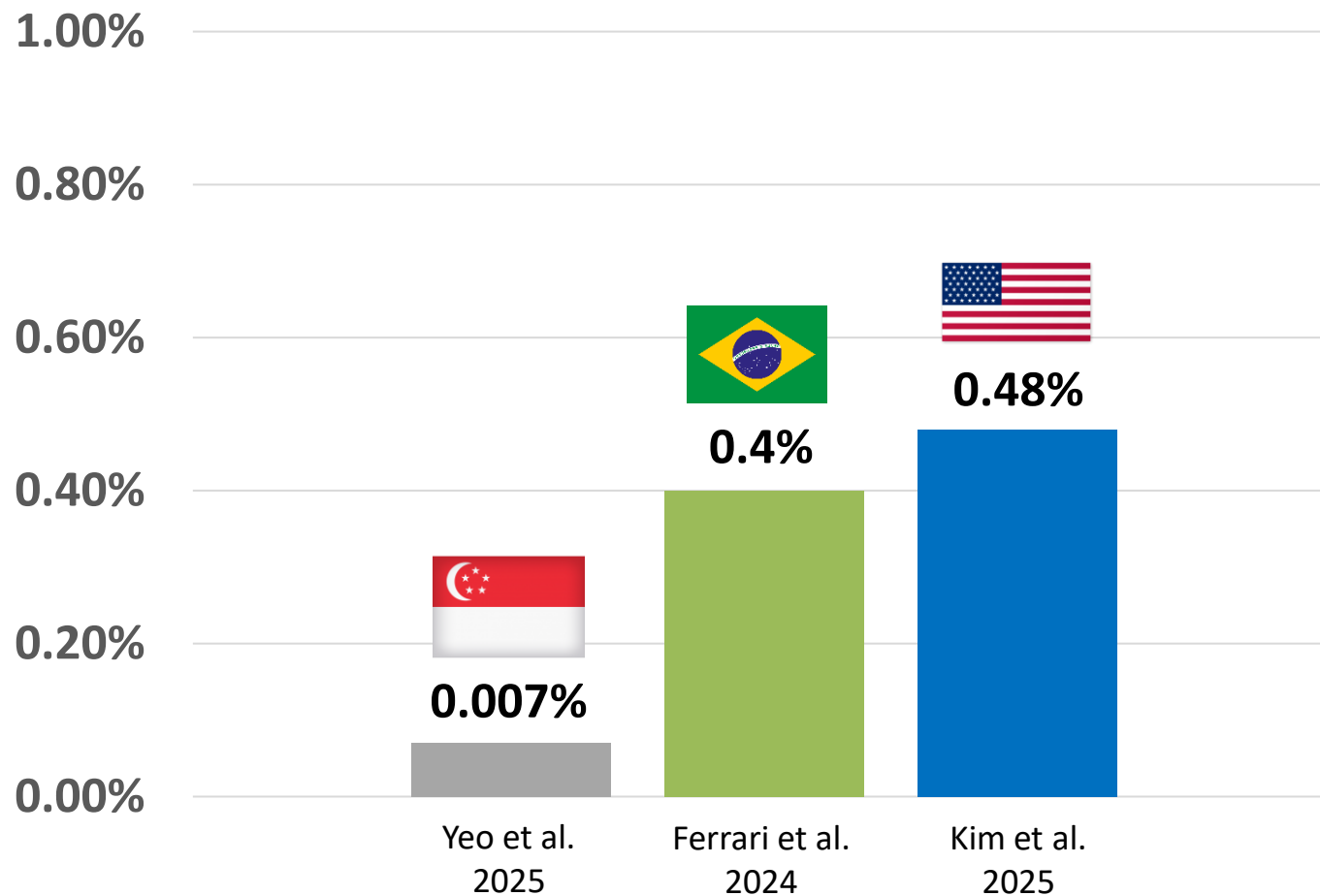
Prevalence of TWI in Leads V1–V4



Prevalence of Anterior TWI in Black Athletes from Different Regions



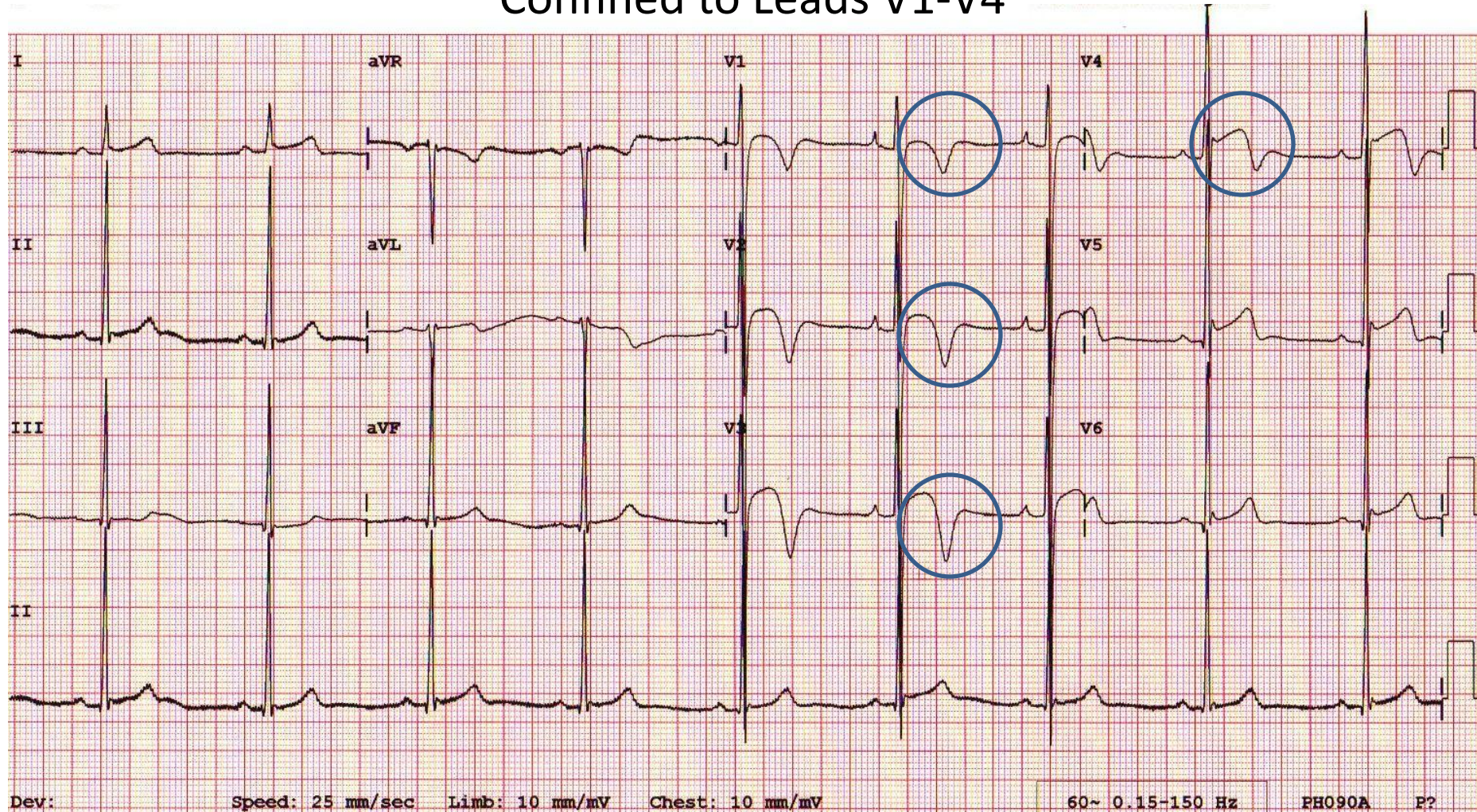
Prevalence of Anterior TWI in Non-Black Athletes from Different Regions



No cardiac pathology

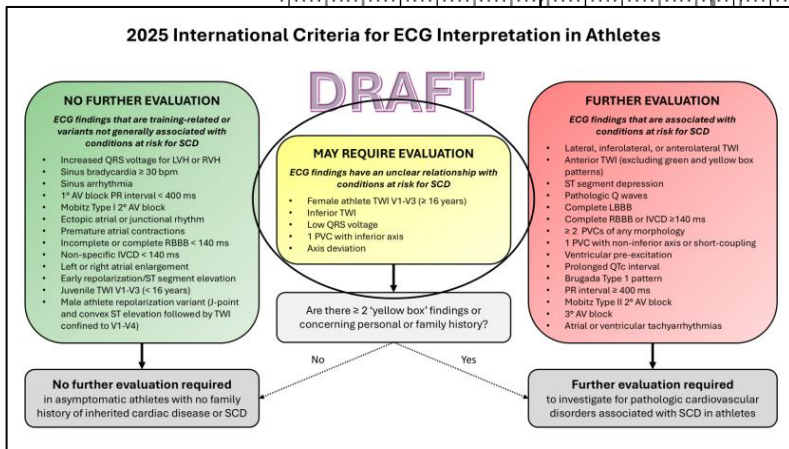
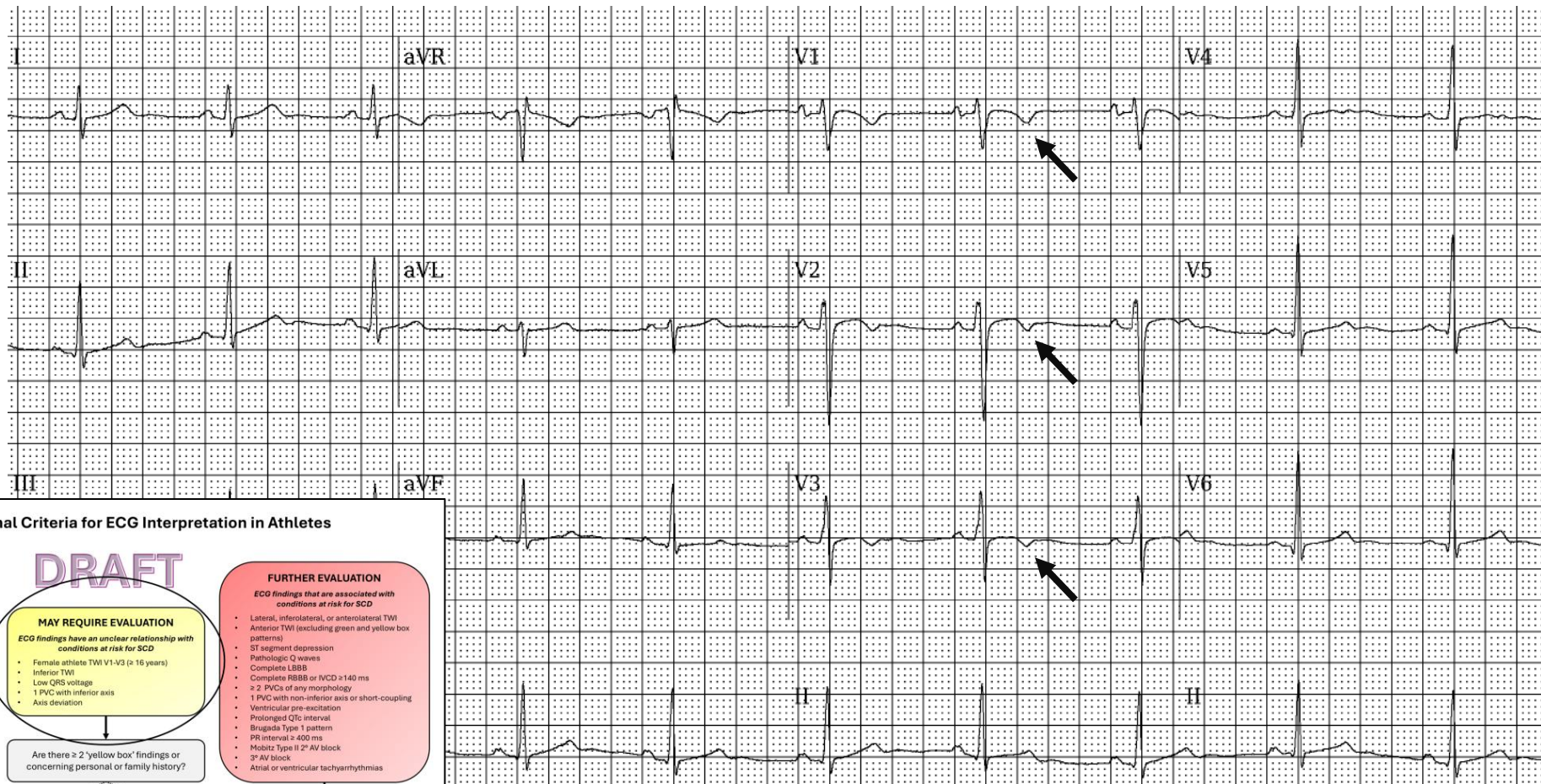
“Male Athlete Repolarization Variant”

Confined to Leads V1-V4

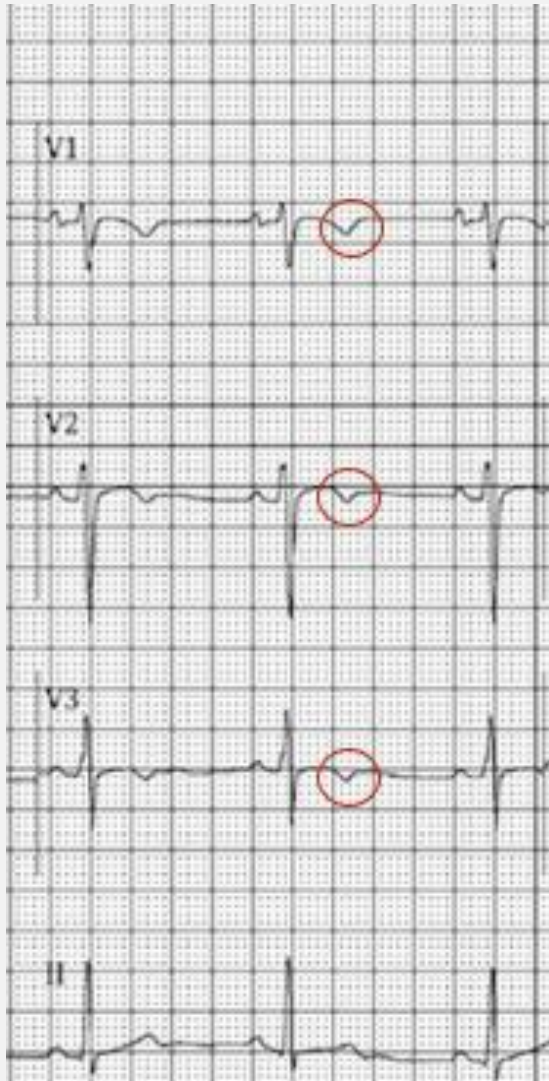


ECG demonstrating J-point elevation and convex (‘domed’) ST segment elevation followed by T wave inversion in V1-V4 (circles). **This is a normal repolarization pattern in male athletes regardless of race/ethnicity.**

Female Athlete TWI V1-V3



Results



ORIGINAL RESEARCH

Isolated Anterior T-Wave Inversion in Elite Athletes: Prevalence and Clinical Relevance by Sex and Sporting Discipline

Jessica J. Orchard, PhD, MPH ; Jonathan A. Drezner, MD ; Hariharan Raju, PhD ; Rajesh Puranik, PhD; Belinda Gray, PhD ; Maria Brosnan, PhD; Robert N. Doughty, MD ; Bruce Hamilton, MD ; Tim Driscoll, PhD ; Angus J. Davis, RN ; Emma Buckthorpe, MD ; Simon Eggleton, MBBS (Hons) ; Aaron Baggish, MD ; Andre La Gerche, PhD ; John W. Orchard, MD, PhD

JAHA

Journal of the American Heart Association

2025

4423 athletes (40% female; mean age, 19.7 years)

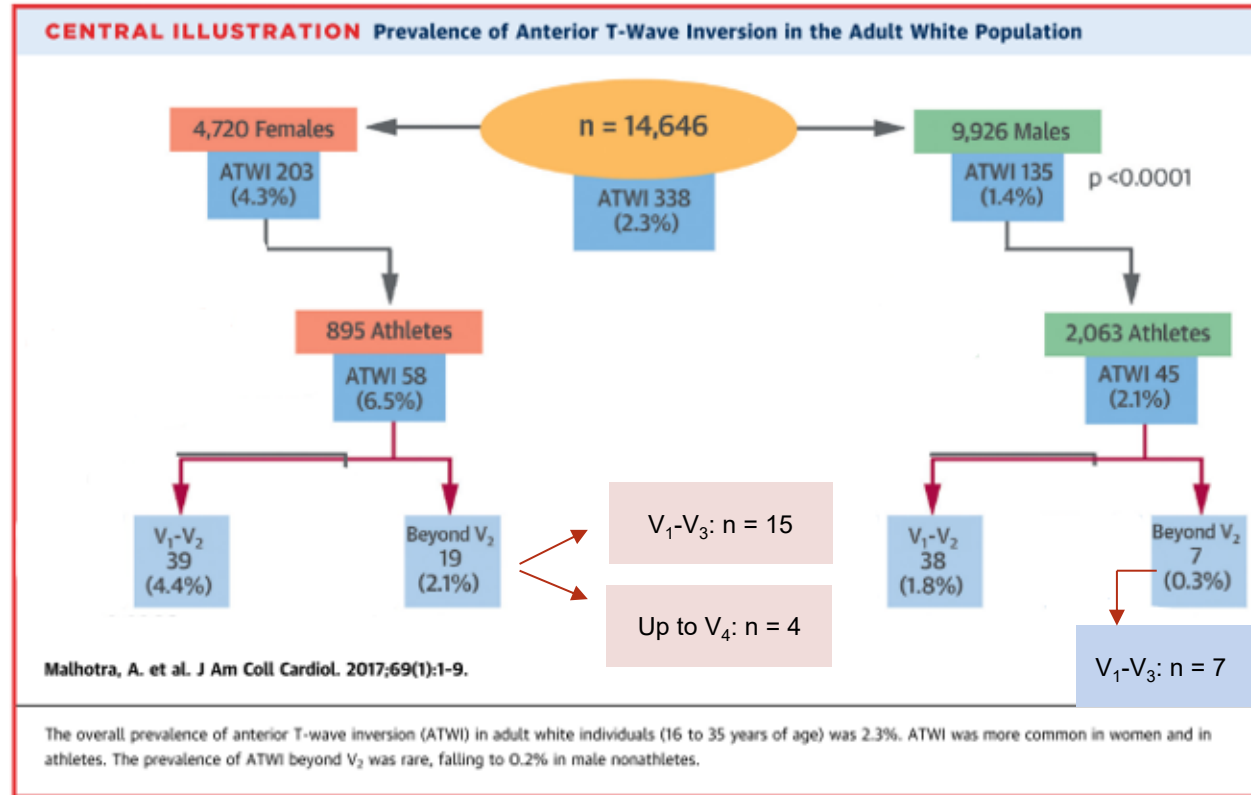
	Female (n,%)	Male (n,%)	Total	P-value
Athletes with an abnormal ECG	74 (4.2%)	69 (2.6%)	143 (3.2%)	0.004
Isolated TWI_{V2-3}	27 (1.5%)	9 (0.3%)	36 (0.8%)	<0.0001
- Deep TWI_{V2-3}	4 (15%)	3 (33%)	7 (19%)	0.22
Other abnormalities	47 (2.6%)	60 (2.3%)	107 (2.4%)	0.43

Isolated TWI_{V2-3} was the most common abnormal ECG finding in female athlete screening ECGs.

No athletes with isolated TWI_{V2-3} were diagnosed with cardiac disease, nor had a major cardiac event.

Malhotra 2017

- 14,000 young people (3,000 athletes) screened with H&P, resting 12 lead ECG
- Anterior TWI more common in women; athletes
- **Athletes with *isolated* TWI_{V1-3}**
 - **1.7% female vs 0.3% male, p=0.0001**
- **Comprehensive clinical evaluation, no diagnoses of cardiomyopathy**
- Mean follow-up 2 years



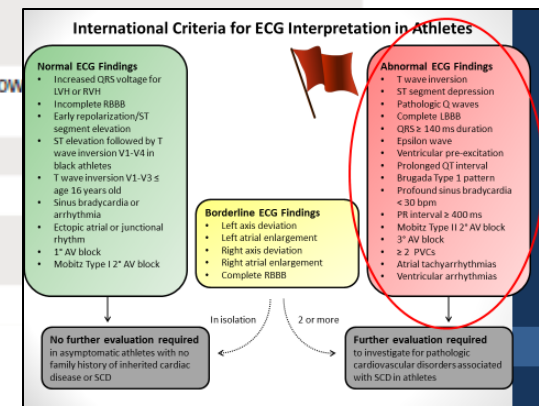
Definitions: Abnormal ECG Findings

Table 1 International consensus standards for ECG interpretation in athletes: definitions of ECG criteria

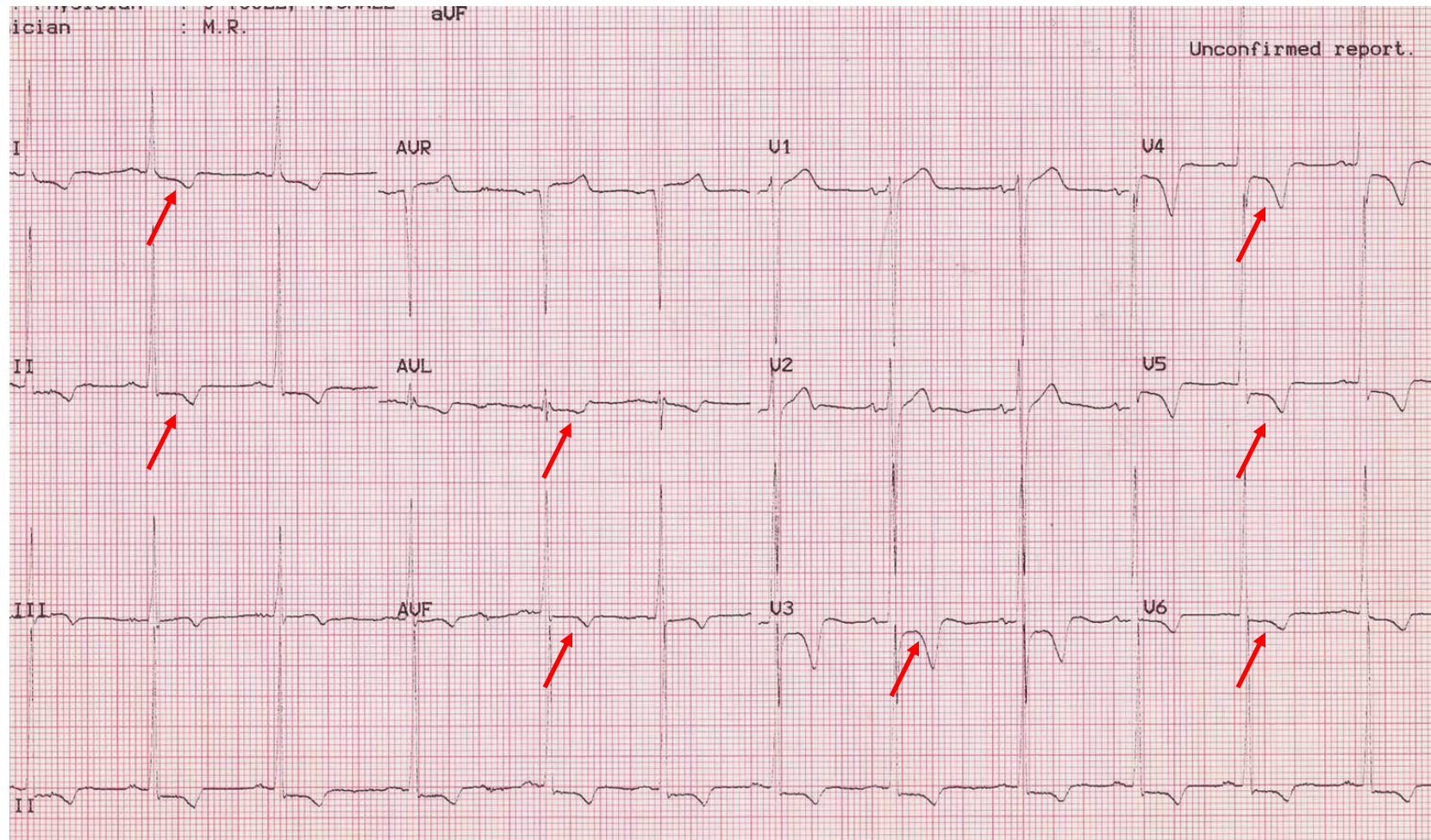
Abnormal ECG findings in athletes

These ECG findings are unrelated to regular training or expected physiological adaptation to exercise, may suggest the presence of pathological cardiovascular disease and require further diagnostic investigation.

ECG abnormality	Definition
T wave inversion	≥1 mm in depth in two or more contiguous leads; excludes leads aVR, III and V1
▶ Anterior	▶ V2-V4 – excludes: black athletes with J-point elevation and convex ST segment elevation followed by TWI in V2-V4; athletes < age 16 with TWI in V1-V3; and biphasic T waves in only V3
▶ Lateral	▶ I and aVL, V5 and/or V6 (only one lead of TWI required in V5 or V6)
▶ Inferolateral	▶ II and aVF, V5-V6, I and aVL
▶ Inferior	▶ II and aVF
ST segment depression	≥0.5 mm in depth in two or more contiguous leads
Pathological Q waves	Q/R ratio ≥0.25 or ≥40 ms in duration in two or more leads (excluding III and aVR)
Complete left bundle branch block	QRS ≥120 ms, predominantly negative QRS complex in lead V1 (QS or rS) and upright notched or slurred R wave in leads I and V6
Profound non-specific intraventricular conduction delay	Any QRS duration ≥140 ms
Epsilon wave	Distinct low amplitude signal (small positive deflection or notch) between the end of the QRS complex and onset of the T wave in leads V1-V3
Ventricular pre-excitation	PR interval <120 ms with a delta wave (slurred upstroke in the QRS complex) and wide QRS (≥120 ms)
Prolonged QT interval*	QTc ≥470 ms (male) QTc ≥480 ms (female) QTc ≥500 ms (marked QT prolongation)
Brugada type 1 pattern	Coved pattern: initial ST elevation ≥2 mm (high take-off) with downsloping ST segment elevation followed by ST depression in ≥1 leads in V1-V3
Profound sinus bradycardia	<30 beats per minute or sinus pauses ≥3s
Profound 1° atrioventricular block	≥400 ms
Mobitz type II 2° atrioventricular block	Intermittently non-conducted P waves with a fixed PR interval
3° atrioventricular block	Complete heart block

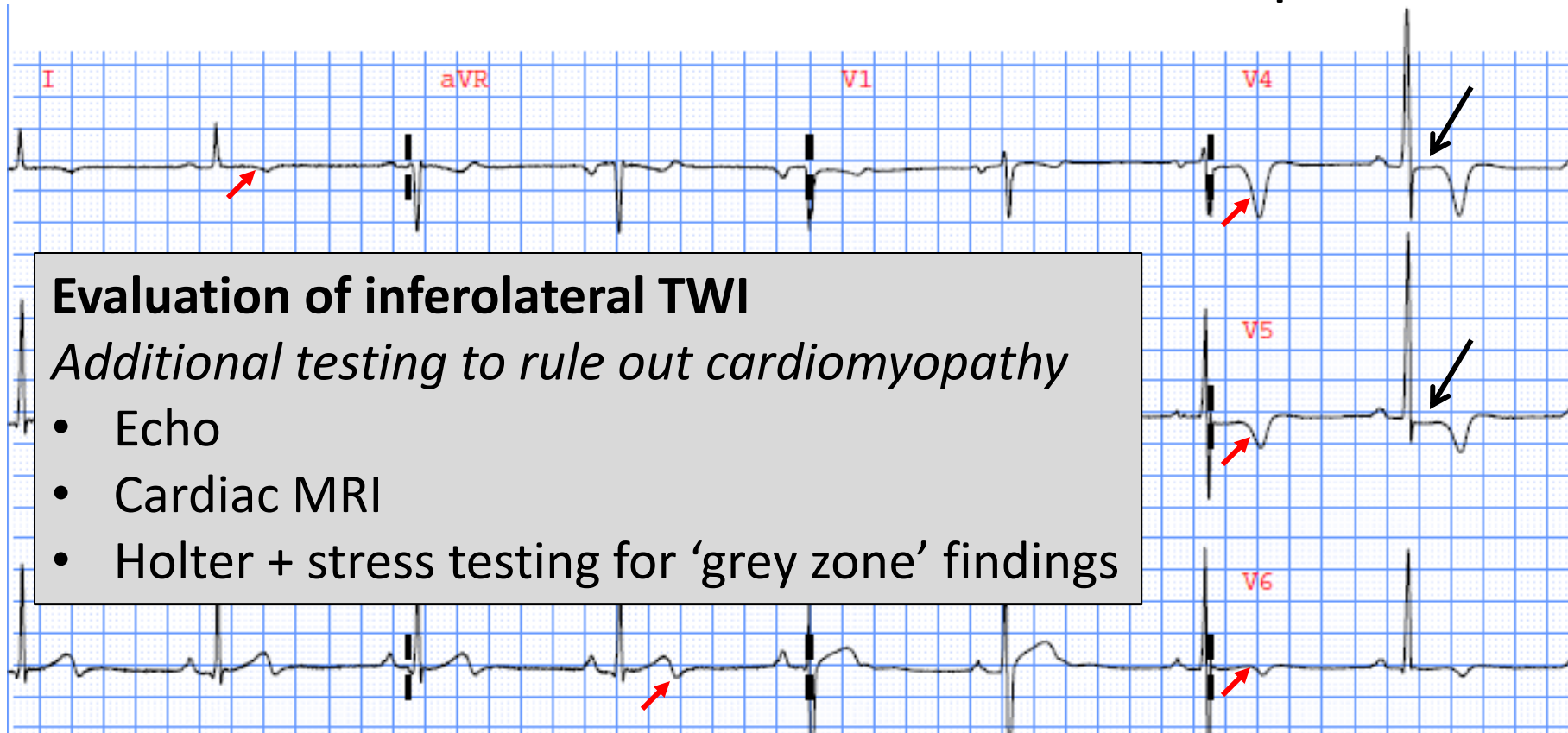


Inferolateral T Wave Inversion and ST Depression



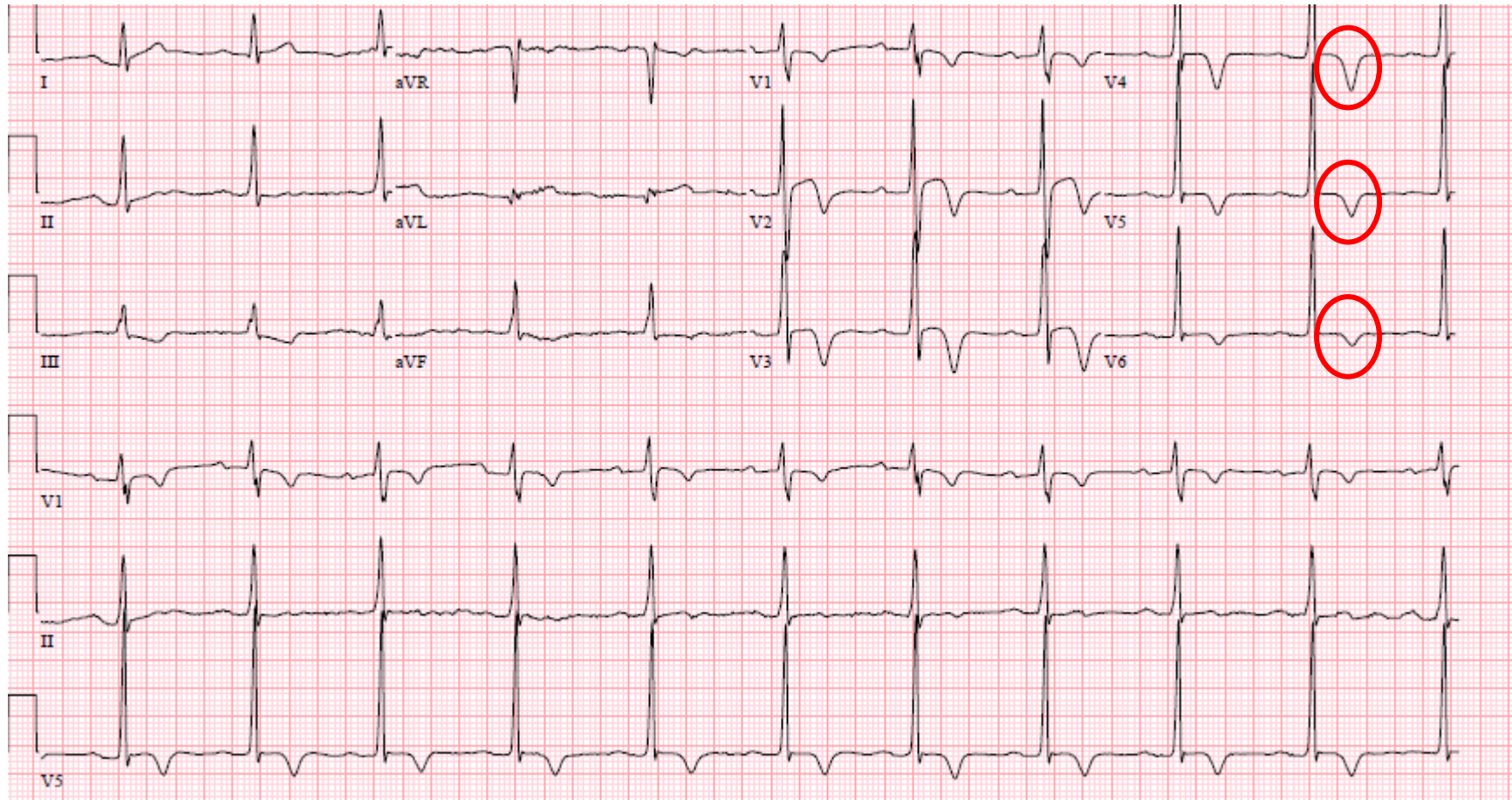
Abnormal ECG in a patient with hypertrophic cardiomyopathy. Note T wave inversion and ST segment depression in the inferolateral leads (arrows).

Inferolateral T Wave Inversion and ST Depression



Abnormal ECG from a patient with hypertrophic cardiomyopathy. Note T wave inversions in I, aVL, V4-V6, II and aVF (red arrows), as well as ST segment depression in V4-V5 (black arrows).

Lateral T Wave Inversion



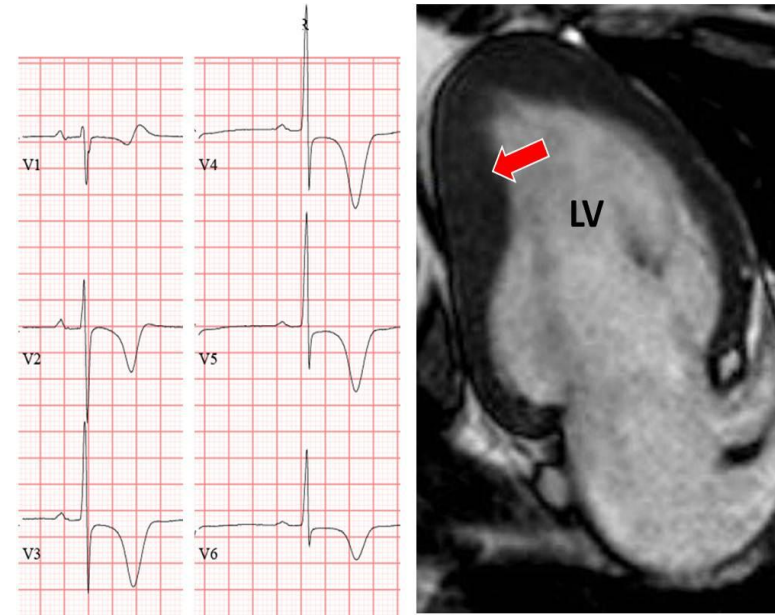
Markedly abnormal ECG showing TWI ≥ 2 mm in V4-V6. Note that the ST segment preceding TWI in V4-6 is flat or downsloping.

Table 2 Evaluation of ECG abnormalities in athletes

ECG abnormality	Potential cardiac disease*	Recommended evaluation†	Considerations
T wave inversion in the lateral or inferolateral leads	HCM DCM LVNC ARVC (with predominant left ventricular involvement) Myocarditis	Echocardiogram Cardiac MRI Exercise ECG test Minimum 24 hours ECG monitor	Lateral or inferolateral T wave inversion is common in primary myocardial disease. Cardiac MRI should be a routine diagnostic test for this ECG phenotype and is superior to echocardiography for detecting apical HCM, left ventricular hypertrophy localised to the free lateral wall, ARVC with predominant left ventricular involvement and myocarditis. If cardiac MRI is not available, echocardiography with contrast should be considered as an alternative investigation for apical HCM in patients with deep T wave inversion in leads V5-V6. Consider family evaluation if available and genetic screening. Annual follow-up testing is recommended throughout athletic career in athletes with normal results.
T wave inversion isolated to the inferior leads	HCM DCM LVNC Myocarditis	Echocardiogram	Consider cardiac MRI based on echocardiogram findings or clinical suspicion.
T wave inversion in the anterior leads‡	ARVC DCM	Echocardiogram Cardiac MRI Exercise ECG test Minimum 24 hours ECG monitor Signal averaged ECG	The extent of investigations may vary based on clinical suspicion for ARVC and results from initial testing.
ST segment depression	HCM DCM LVNC ARVC Myocarditis	Echocardiogram	Consider cardiac MRI and additional testing based on echocardiogram findings or clinical suspicion.
Pathological Q waves	HCM DCM LVNC Myocarditis Prior myocardial infarction	Echocardiogram Coronary artery disease risk factor assessment Repeat ECG for septal (V1-V2) QS pattern; above investigations recommended if septal Q waves are persistent	Consider cardiac MRI (with perfusion study if available) based on echocardiogram findings or clinical suspicion. In the absence of cardiac MRI, consider exercise stress testing, dobutamine stress echocardiogram or a myocardial perfusion scan for evaluation of coronary artery disease in athletes with suspicion of prior myocardial infarction or multiple risk factors for coronary artery disease.
Complete left bundle branch block	DCM HCM LVNC Sarcoidosis Myocarditis	Echocardiogram Cardiac MRI (with stress perfusion study)§	A comprehensive cardiac evaluation to rule out myocardial disease should be considered.

Evaluation of Lateral or Inferolateral TWI

- Comprehensive evaluation to r/o cardiomyopathy
- Echocardiogram
- **Cardiac MRI should be a routine diagnostic test for this ECG phenotype**
 - Apical HCM, DCM, LVNC, AC with LV involvement, non-ischemic LV scar
- 24 hour ECG monitor + stress testing for 'grey zone' findings

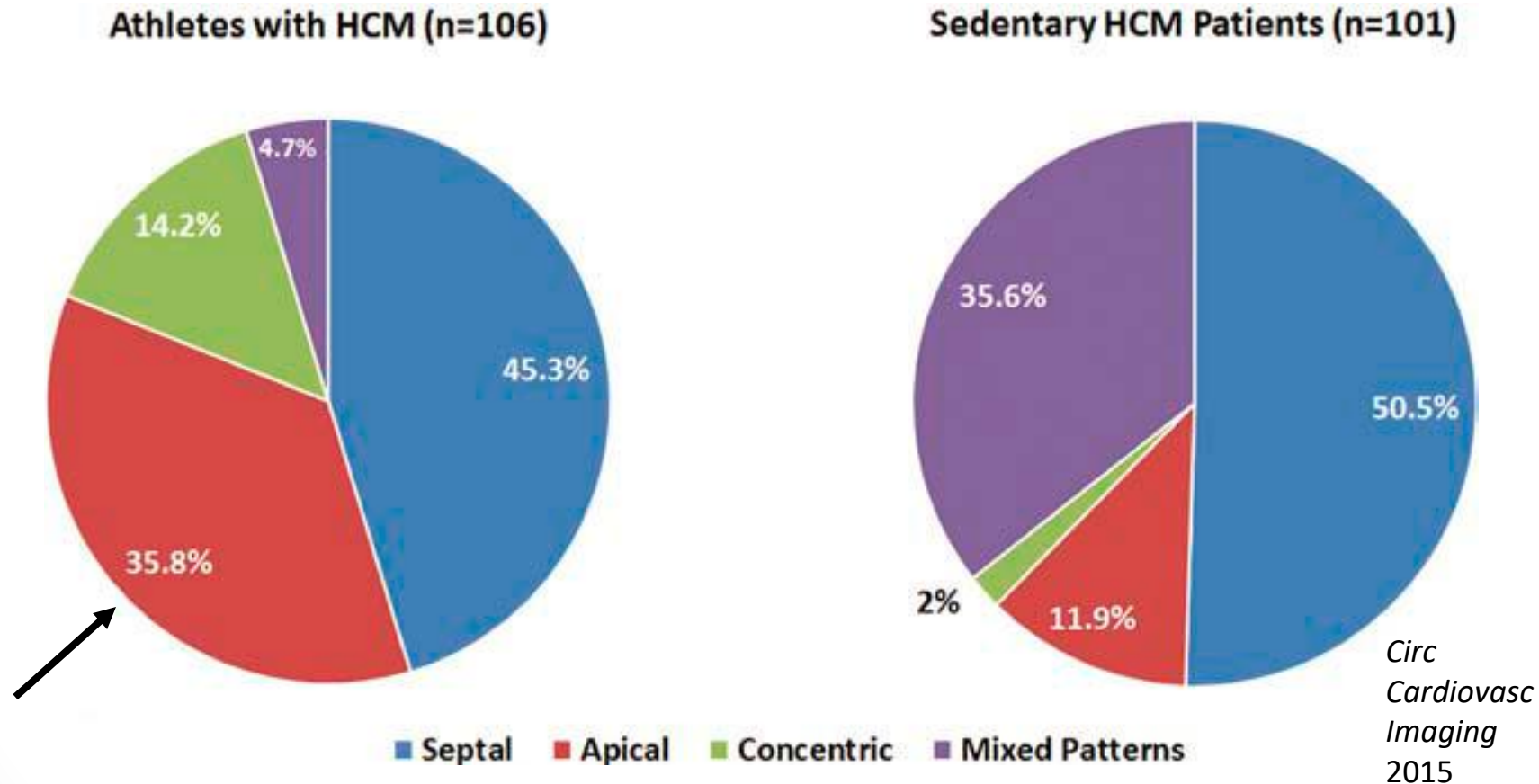


Apical HCM

Clinical Profile of Athletes With Hypertrophic Cardiomyopathy

Nabeel Sheikh, MRCP; Michael Papadakis, MD; Frédéric Schnell, PhD;
Vasileios Panoulas, MD, PhD; Aneil Malhotra, MRCP; Mathew Wilson, PhD;
François Carré, PhD; Sanjay Sharma, MD

Differences in LVH patterns between athletes with HCM and sedentary HCM patients.



Long-term Follow-up of Athletes with Markedly Abnormal ECGs

Pelliccia; *NEJM* 2008

Study Group;
Normal Cardiac Imaging

81

9-year Follow-up

No Symptoms;
No CV disease

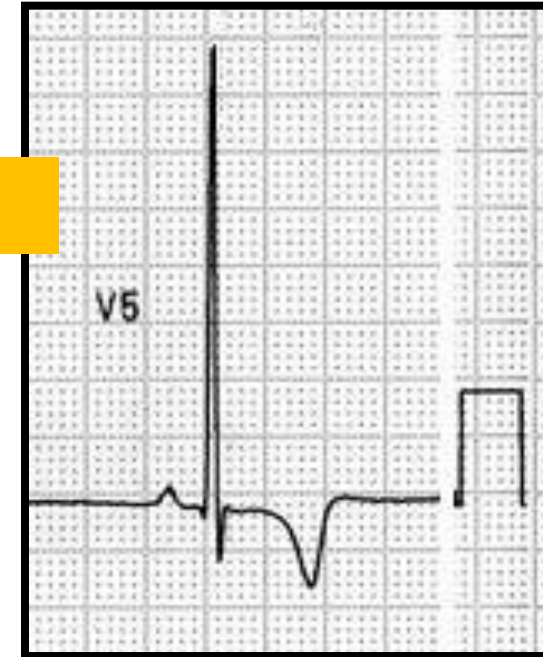
70

6

Other CV Disease

5

Cardiomyopathies
(HCM 3; ARVC 1; DCM 1)

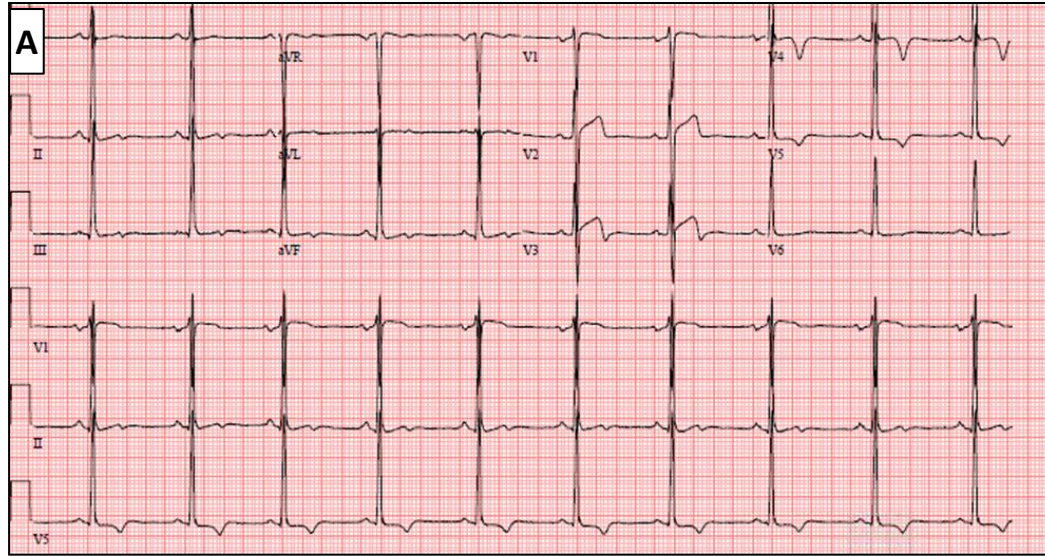


6%

1 Sudden Death,
1 Cardiac Arrest

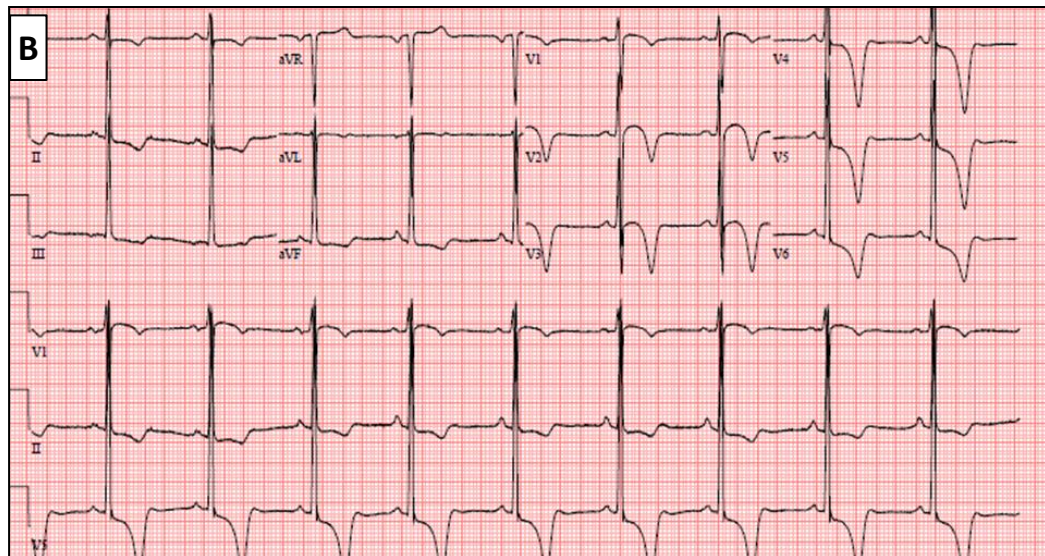
Serial Follow-up

19 yo African-American male, college basketball player



September 2008

Echo and CMR
non-diagnostic

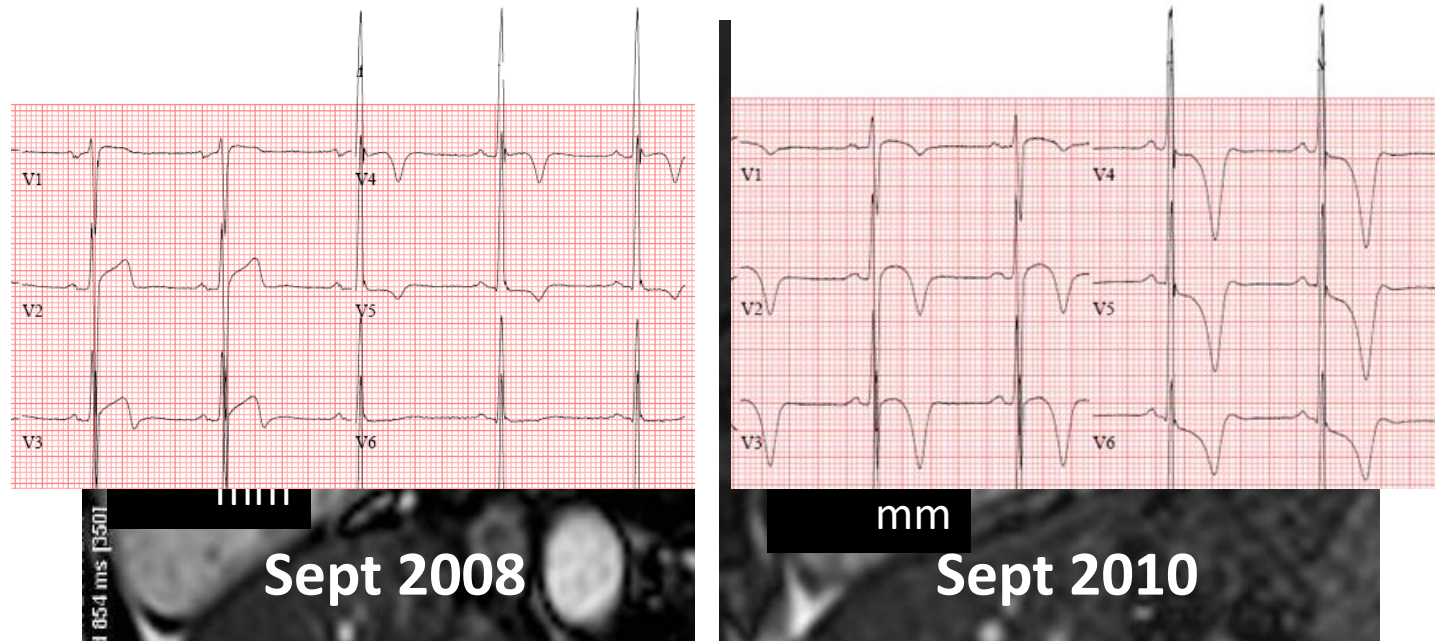


September 2010

CMR apical
hypertrophy 20 mm
with +LGE

Cardiac MRI Comparison

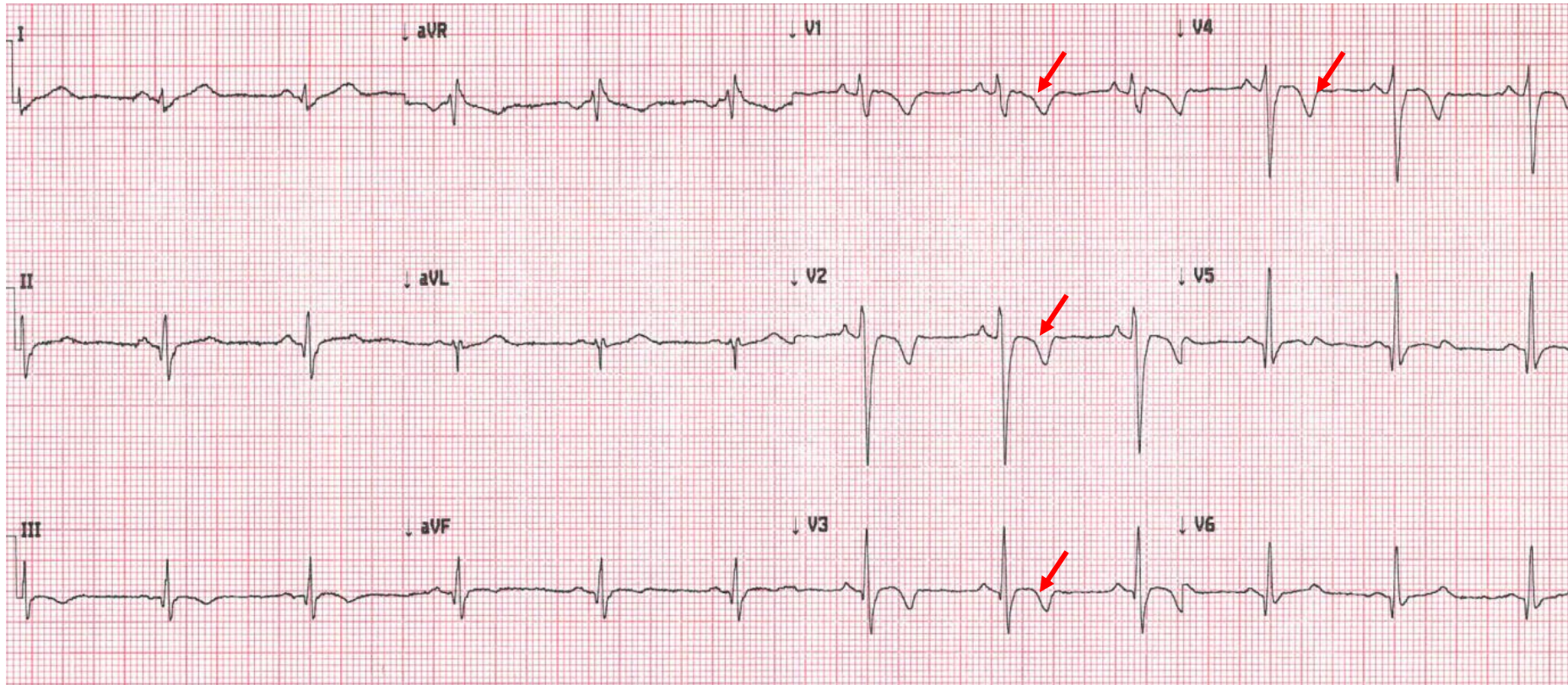
Midventricular Short Axis Views



Hypertrophy of interventricular septum over 2 years

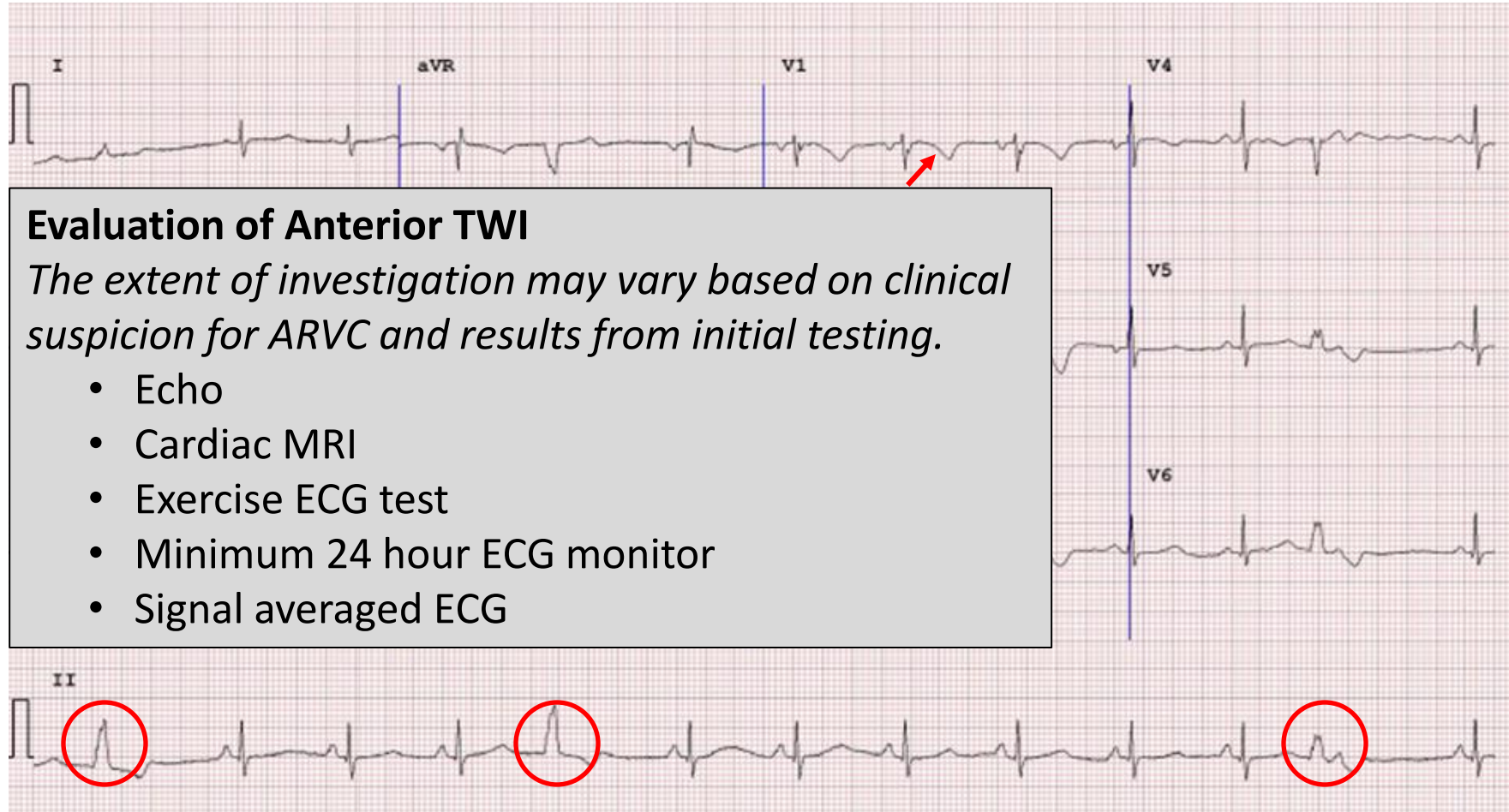
Yearly repeat of ECG and cardiac imaging indicated for athletes with pathological lateral or inferolateral TWI and initial normal imaging studies.

Anterior T Wave Inversion



21 yo Caucasian male with ECG demonstrating anterior T wave inversion (V1-V4) preceded by a **non-elevated J-point and ST segment**. Delayed S wave upstroke (≥ 55 ms) in V2 and low voltage (<5 mm) QRS complexes in limb leads I and aVL suggest possible ARVC.

Anterior T Wave Inversion



Evaluation of Anterior TWI

The extent of investigation may vary based on clinical suspicion for ARVC and results from initial testing.

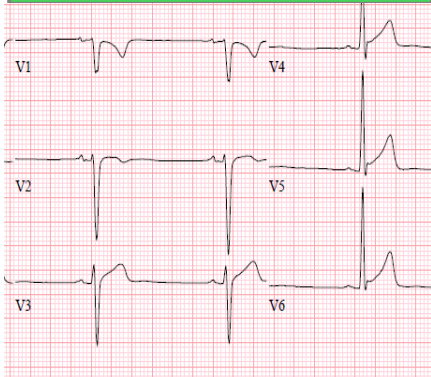
- Echo
- Cardiac MRI
- Exercise ECG test
- Minimum 24 hour ECG monitor
- Signal averaged ECG

ECG from a patient with ARVC. Note pathological TWI in V1-V3 (arrows) preceded by a flat or downsloping ST segment and without J-point elevation. PVCs also present (circles).

Approach to Anterior T Wave Inversion in Athletes

TWI in V1-V2

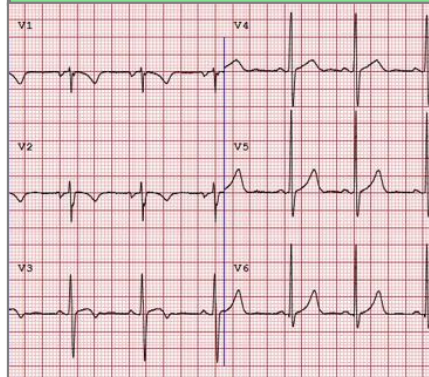
Normal in any athlete



No further evaluation needed

Juvenile (age <16) TWI V1-V3

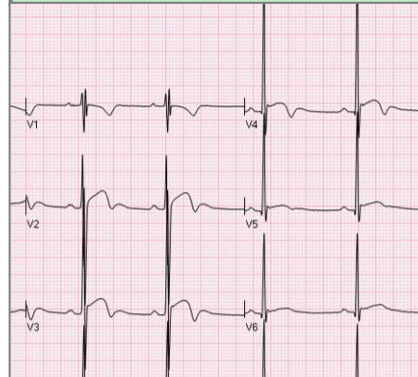
Flat or elevated ST segment followed by TWI confined to V1-V3



No further evaluation needed

Male Athlete Repolarization Variant V1-V4

J-point elevation (≥ 1 mm) and convex ST elevation followed by TWI confined to V1-V4

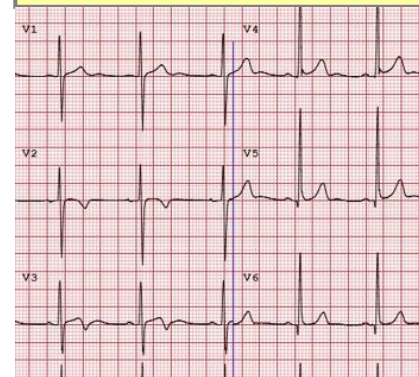


Normal regardless of race/ethnicity

No further evaluation needed

Female Athlete TWI V1-V3

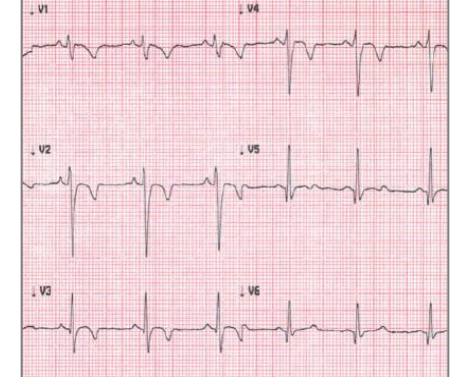
Flat or elevated ST segment followed by TWI confined to V1-V3



Two or more 'yellow box' findings, any 'red box' finding, or clinical concerns?

Abnormal TWI V1-V4

Minimally elevated J-point (< 1 mm) and flat ST segment followed by TWI in V1-V4

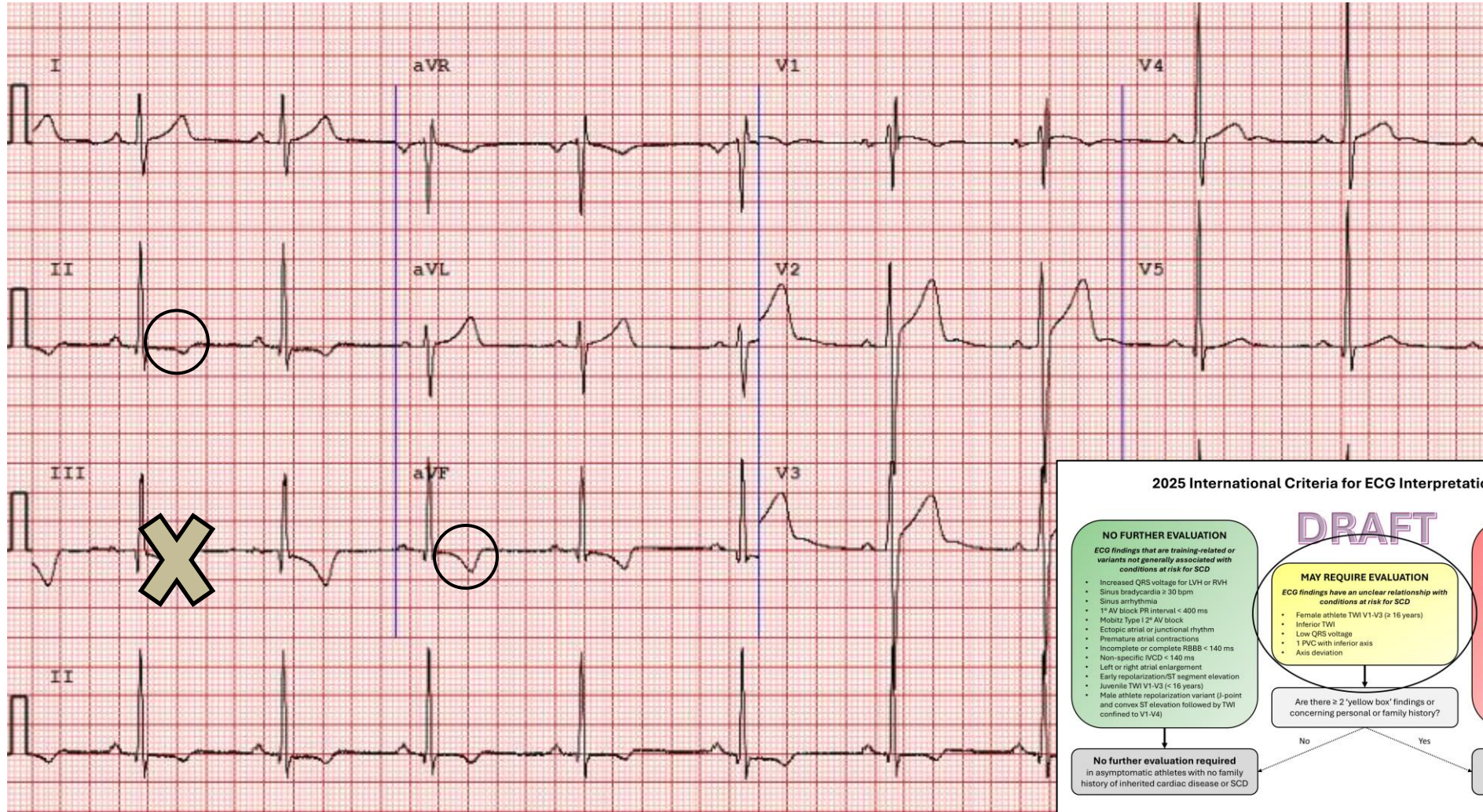


Co-existing ECG abnormalities?

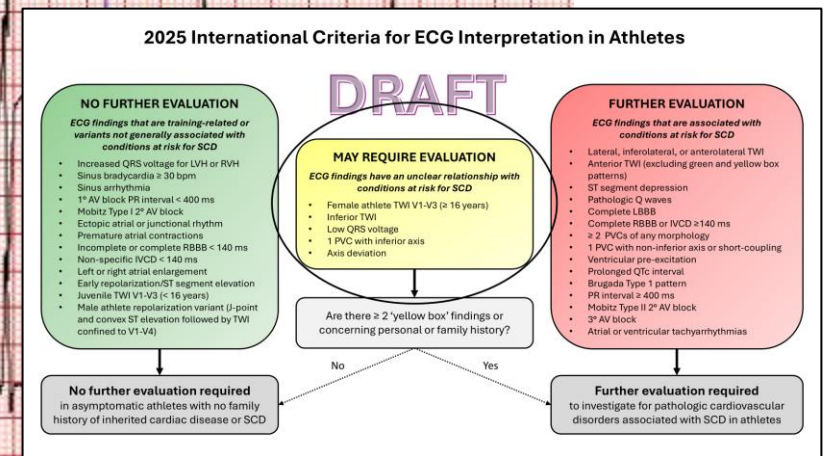
- S wave in V2 > 55 msec
- Epsilon wave
- PVCs
- LQRSV
- Inferior or lateral TWI

Further evaluation

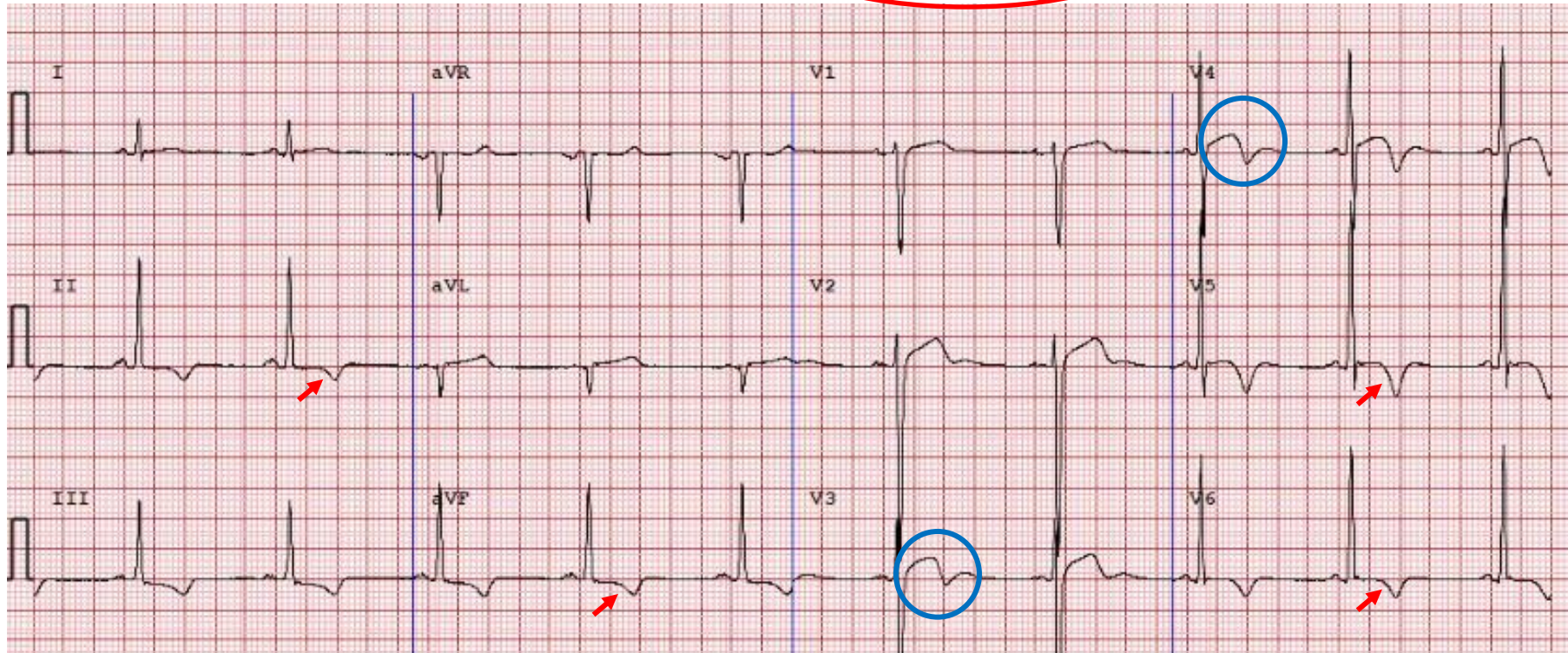
Inferior T Wave Inversion



ECG demonstrates TWI in the inferior leads II and aVF.



Normal or **Abnormal**?



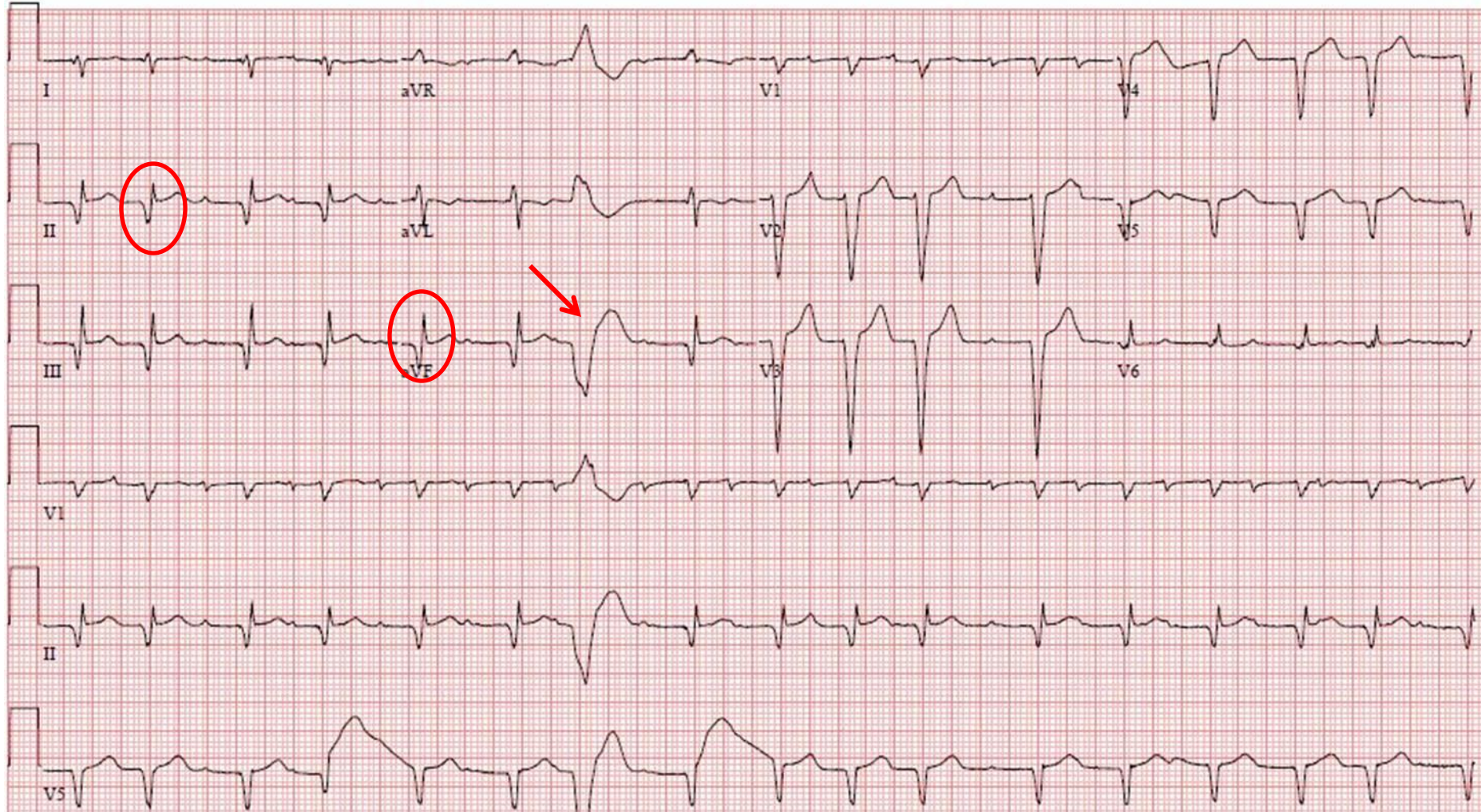
Evaluation of Inferolateral TWI

Additional testing to rule out cardiomyopathy

- Echo
- Cardiac MRI
- Holter + stress testing for 'grey zone' findings
- If initial studies are non-diagnostic → serial (annual) follow-up with ECG + Echo (at minimum); cardiac MRI for changes in ECG or Echo

Pathologic Q Waves

$Q/R \text{ ratio} \geq 0.25$ or $Q \text{ wave} \geq 40 \text{ ms}$ in duration

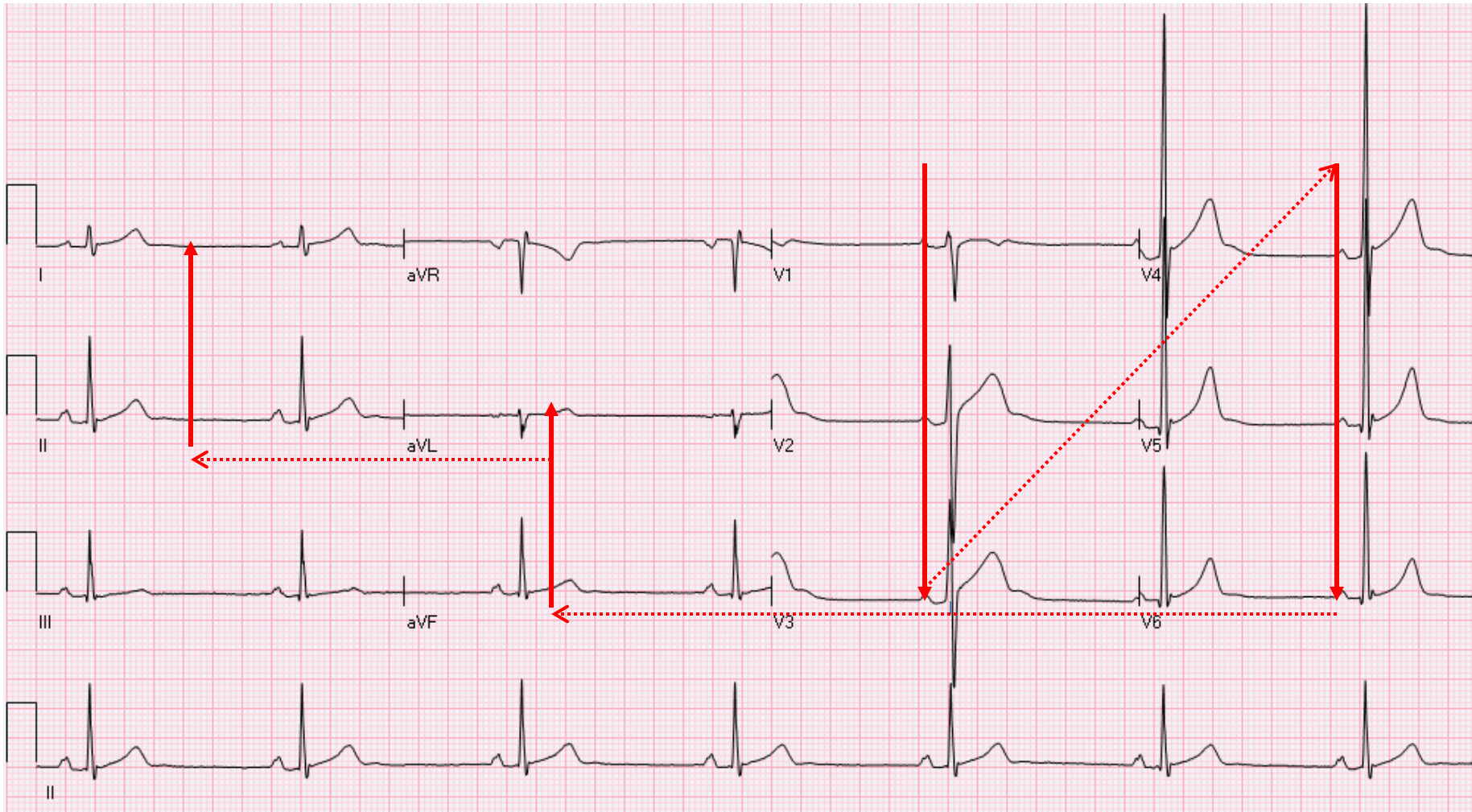


ECG of a young patient with dilated cardiomyopathy. Note inferior Q waves (II and aVF), poor R wave progression across the precordial leads with deep S waves in V1-V3, and a single premature ventricular complex (arrow). High degree AV block is also present.

5-Steps to ECG Interpretation in Athletes

Where to look?	What to look for?
1. Precordial (V1-V6) then limb leads (aVF, aVL, II, I)	Q waves, ST depression, T wave inversion
2. Precordial (V1-V6) then limb leads (aVF, aVL, II, I)	QRS morphology: <ul style="list-style-type: none">• Pre-excitation (delta wave; short PR)• Left bundle branch block• Conduction delay (QRS ≥ 140 ms)• Brugada type 1• Low QRS voltage (≤ 5 mm in all 6 limb leads)
3. Axis – limb leads I and II	QRS pos in I and II (leftward to -30°) QRS neg in I and aVR, pos in II (rightward to 120°) LAD, RAD, or Northwest axis
4. Rhythm strip – lead II or V5	QRS after every P wave PVCs (non-inferior axis or short-coupling)
5. QT interval – lead II or V5	QTc ≥ 470 ms males or ≥ 480 ms females

Step-2: ECG Interpretation in Athletes



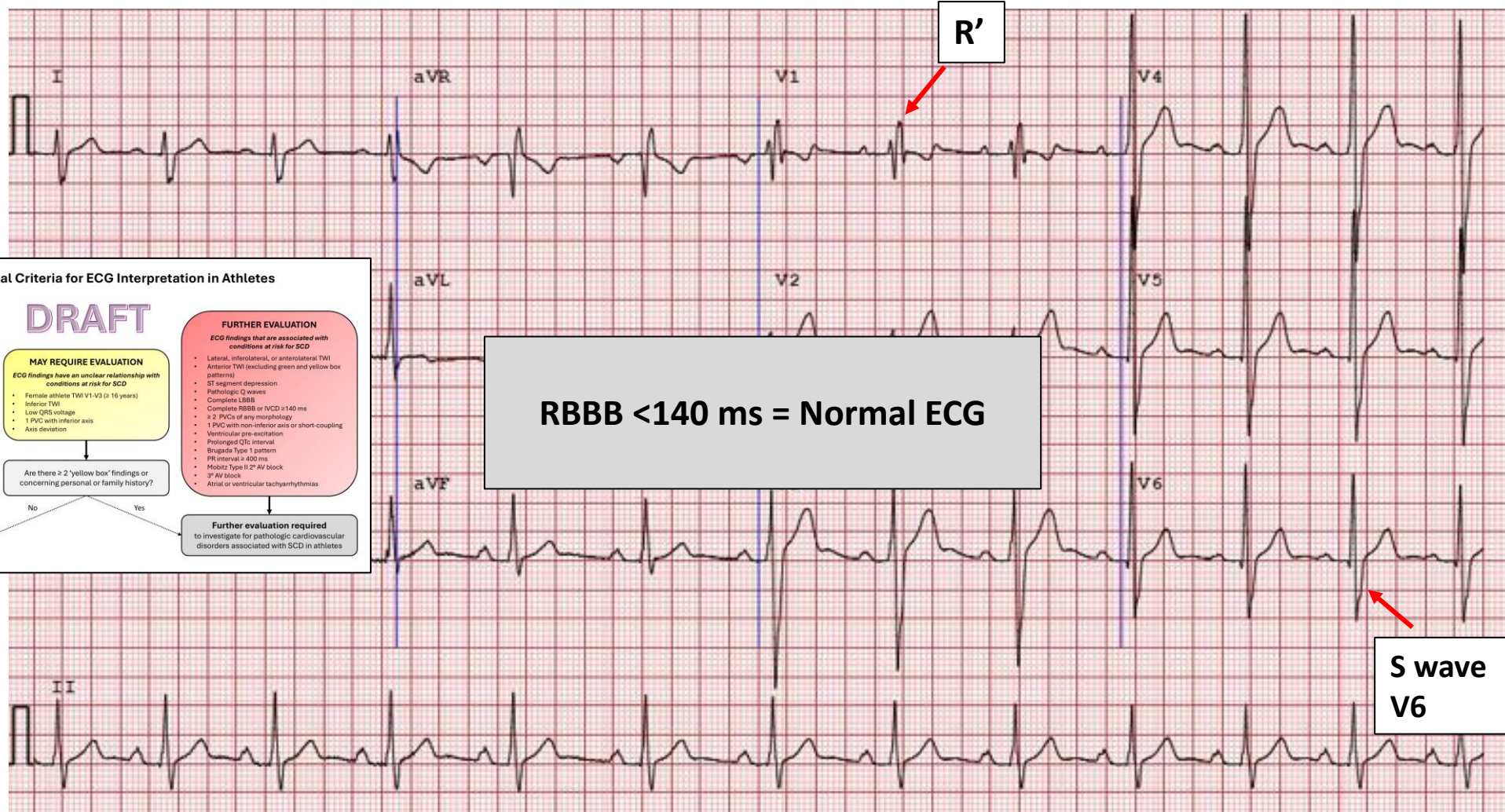
Where to look?

2. Precordial (V1-V6) then limb leads (aVF, aVL, II, I)

What to look for?

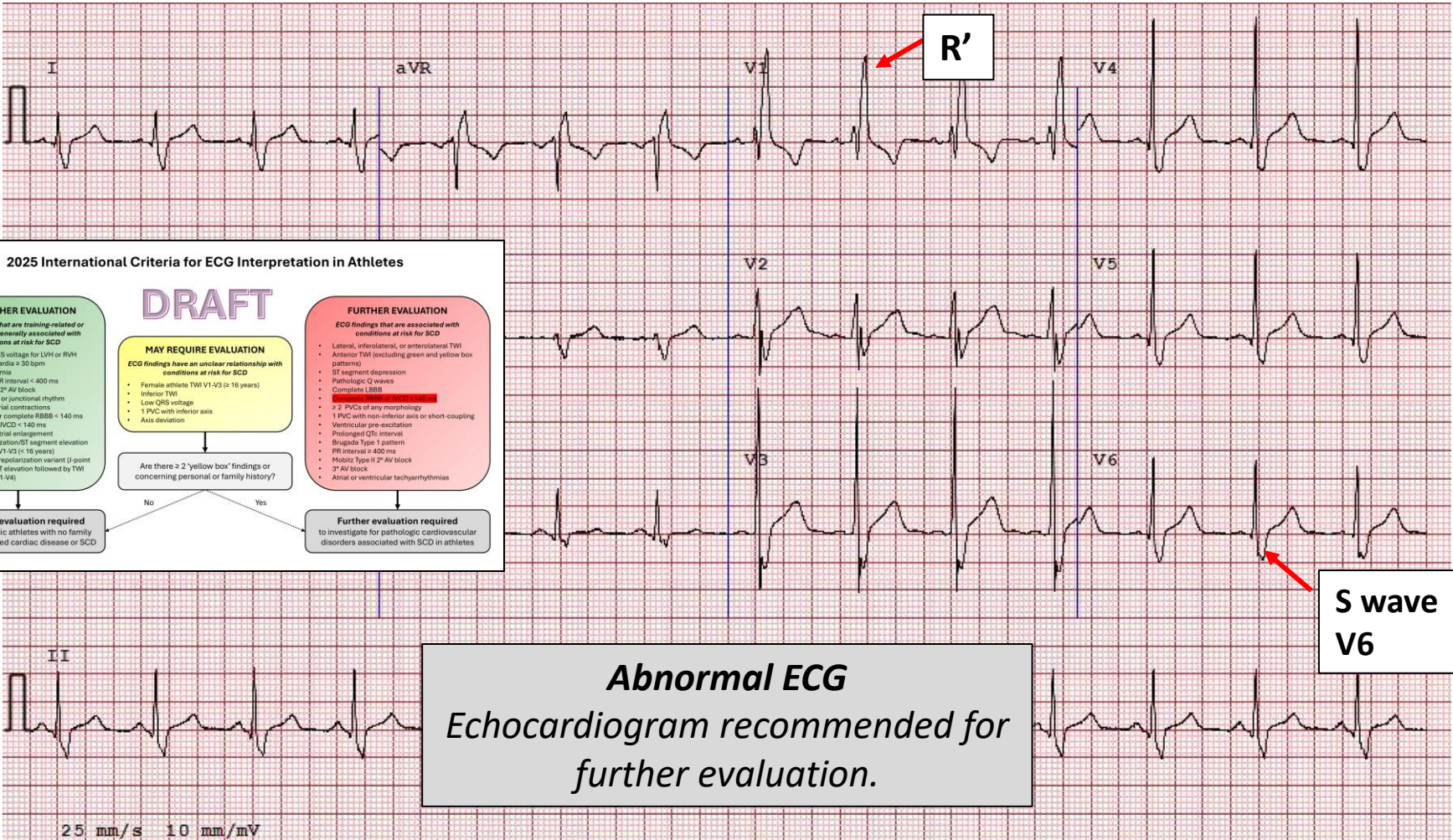
QRS morphology: pre-excitation, LBBB, conduction delay, Brugada type 1, LQSV

Complete Right Bundle Branch Block



- 19 yo Caucasian male athlete with complete RBBB. The QRS duration is ≥ 120 ms with rSR' pattern in V1 and S wave wider than R wave in V6.
- When found in isolation without other borderline or abnormal findings, and without other clinical markers of concern, complete RBBB does not require more investigation.

Complete RBBB with QRS Duration ≥ 140 ms = ABNORMAL



ECG showing complete RBBB with a **QRS duration of 144 ms**. Any conduction delay with QRS duration ≥ 140 ms requires further evaluation.

2025 International Criteria for ECG Interpretation in Athletes

DRAFT

NO FURTHER EVALUATION

ECG findings that are training-related or variants not generally associated with conditions at risk for SCD

- Increased QRS voltage for LVH or RVH
- Sinus bradycardia ≥ 30 bpm
- Sinus arrhythmia
- 1° AV block PR interval < 400 ms
- Mobitz Type I 2° AV block
- Ectopic atrial or junctional rhythm
- Premature atrial contractions
- Incomplete or complete RBBB < 140 ms
- Non-specific IVCD < 140 ms
- Left or right atrial enlargement
- Early repolarization/ST segment elevation
- Juvenile TWI V1-V3 (< 16 years)
- Male athlete repolarization variant (J-point and convex ST elevation followed by TWI confined to V1-V4)

MAY REQUIRE EVALUATION

ECG findings have an unclear relationship with conditions at risk for SCD

- Female athlete TWI V1-V3 (≥ 16 years)
- Inferior TWI
- **Low QRS voltage**
- 1 PVC with inferior axis
- Axis deviation

FURTHER EVALUATION

ECG findings that are associated with conditions at risk for SCD

- Lateral, inferolateral, or anterolateral TWI
- Anterior TWI (excluding green and yellow box patterns)
- ST segment depression
- Pathologic Q waves
- Complete LBBB
- Complete RBBB or IVCD ≥ 140 ms
- ≥ 2 PVCs of any morphology
- 1 PVC with non-inferior axis or short-coupling
- Ventricular pre-excitation
- Prolonged QTc interval
- Brugada Type 1 pattern
- PR interval ≥ 400 ms
- Mobitz Type II 2° AV block
- 3° AV block
- Atrial or ventricular tachyarrhythmias

Are there ≥ 2 'yellow box' findings or concerning personal or family history?

No

Yes

No further evaluation required

in asymptomatic athletes with no family history of inherited cardiac disease or SCD

Further evaluation required

to investigate for pathologic cardiovascular disorders associated with SCD in athletes



ESC

European Society
of Cardiology

European Journal of Preventive Cardiology (2024) **00**, 1–9

<https://doi.org/10.1093/eurjpc/zwae027>

REVIEW

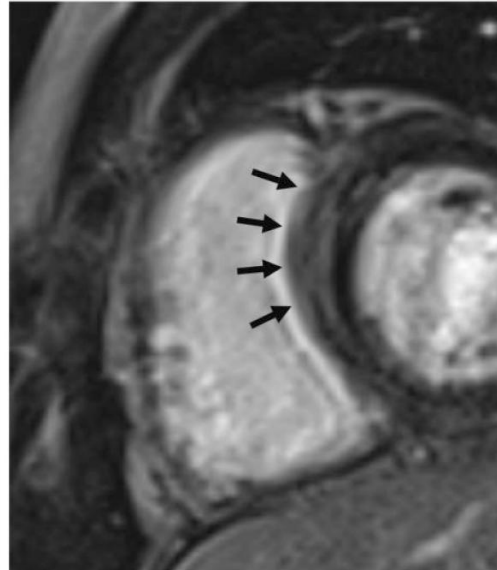
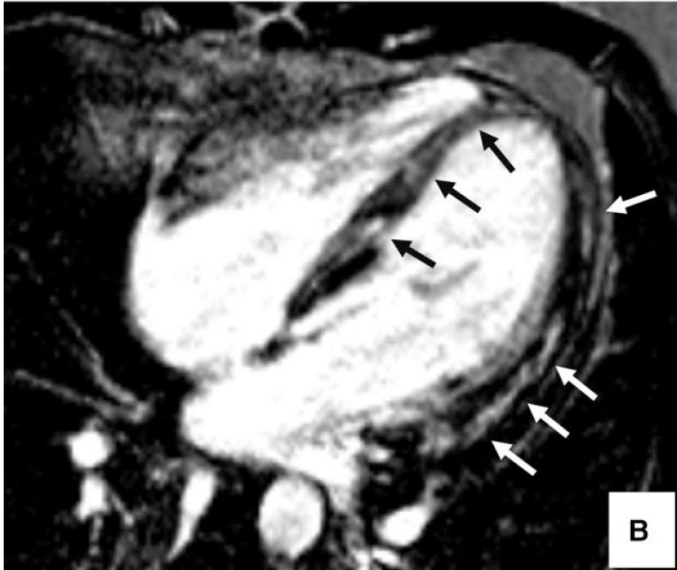
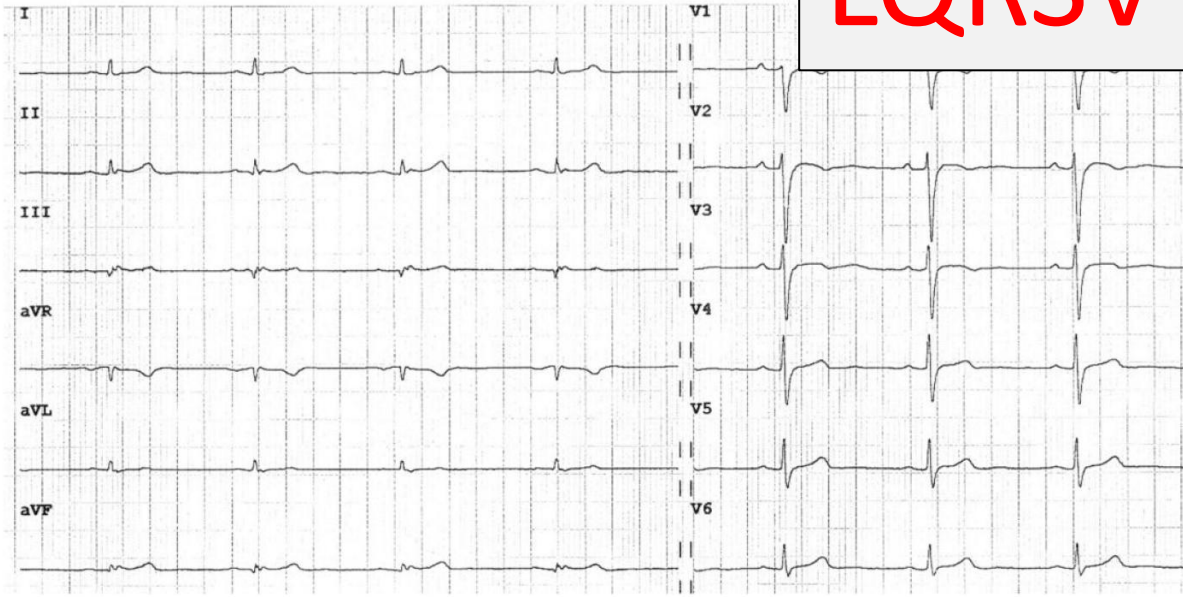
Sports cardiology

Prevalence and clinical significance of low QRS voltages in healthy individuals, athletes, and patients with cardiomyopathy: implications for sports pre-participation cardiovascular screening

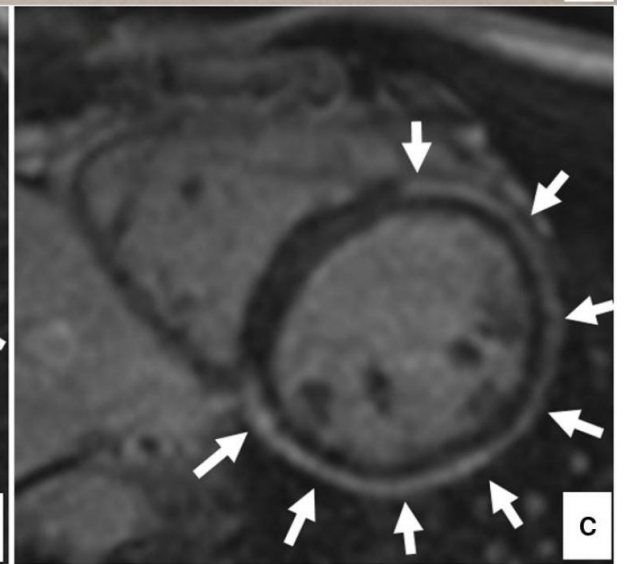
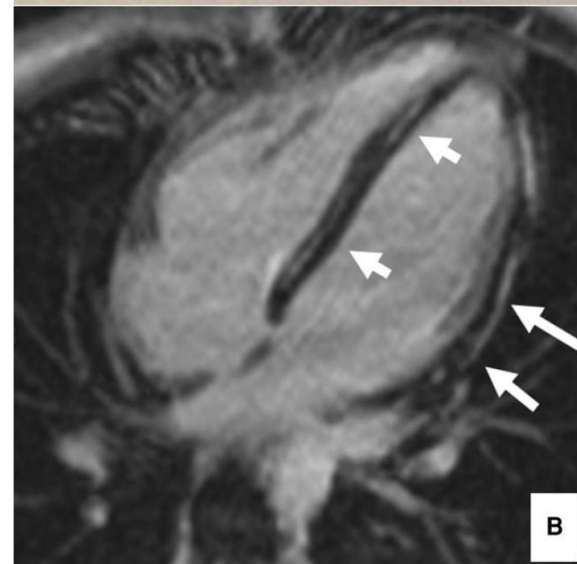
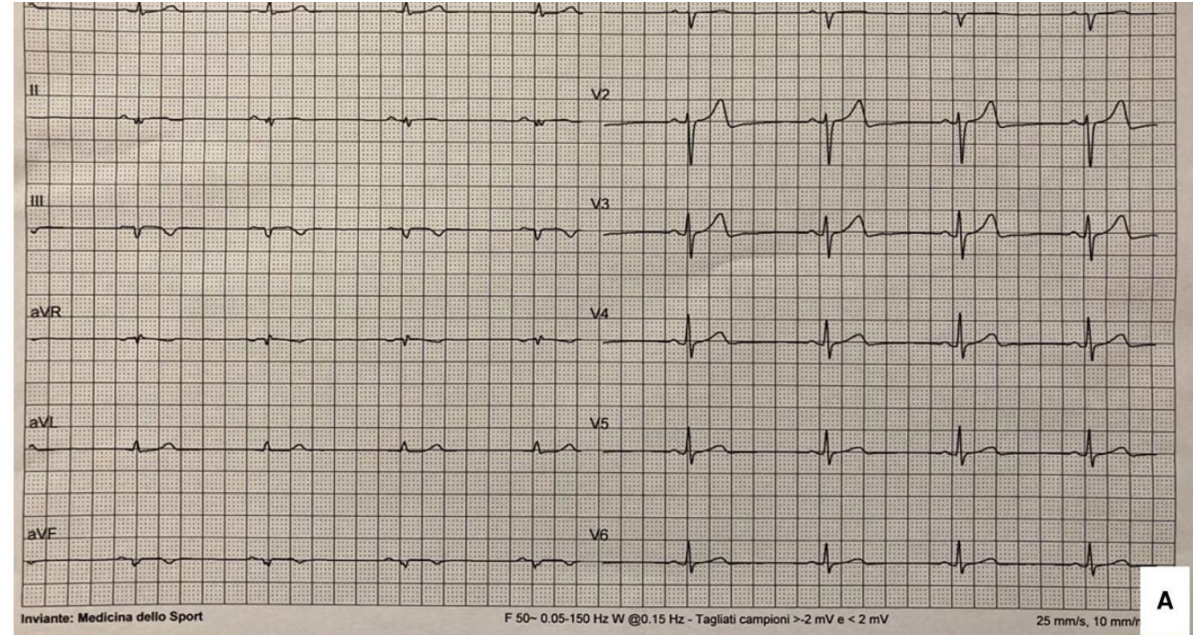
**Antonio Pelliccia  ^{1*}, Jonathan A. Drezner², Alessandro Zorzi³,
and Domenico Corrado  ³**

Non-ischemic LV scar

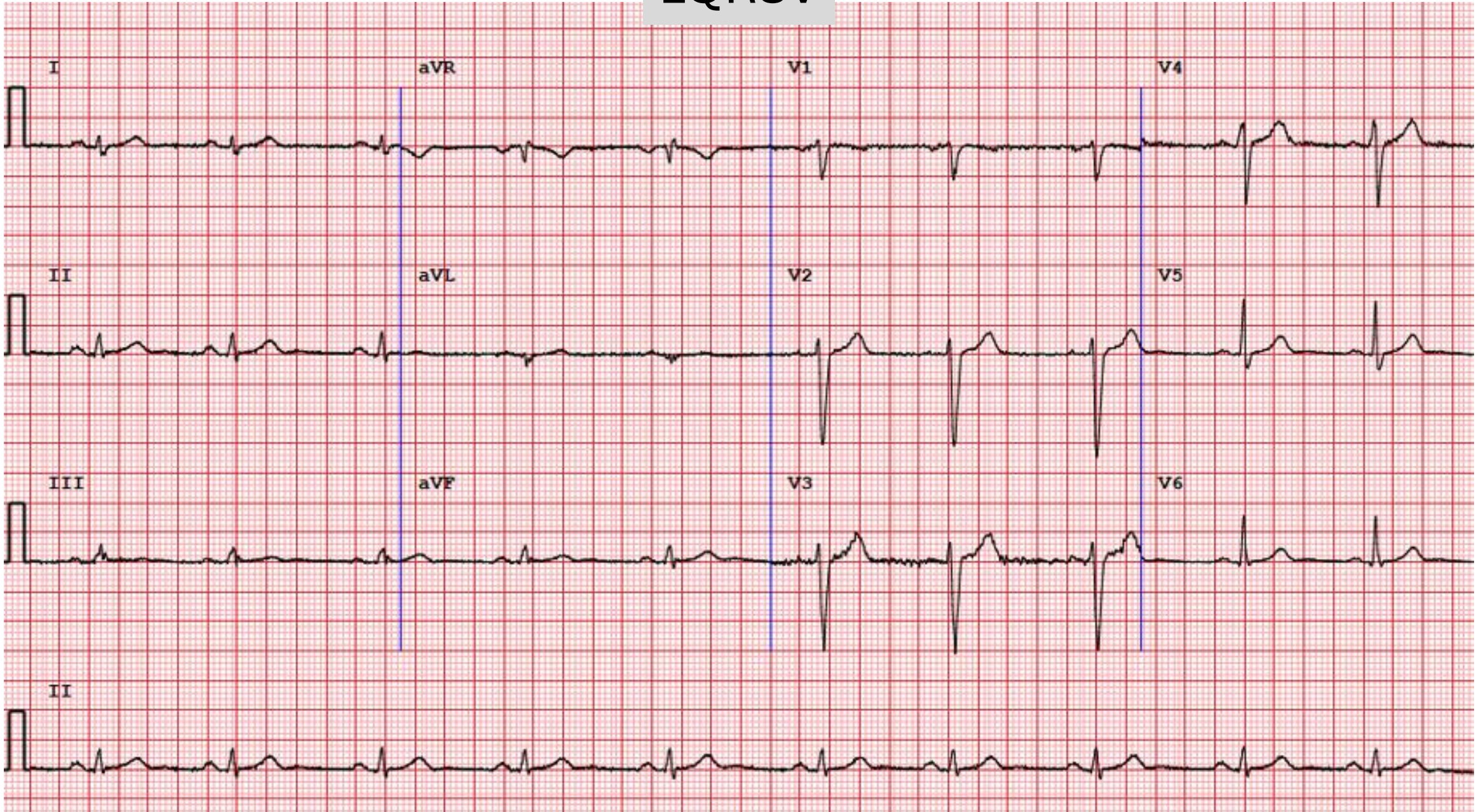
LQ RSV



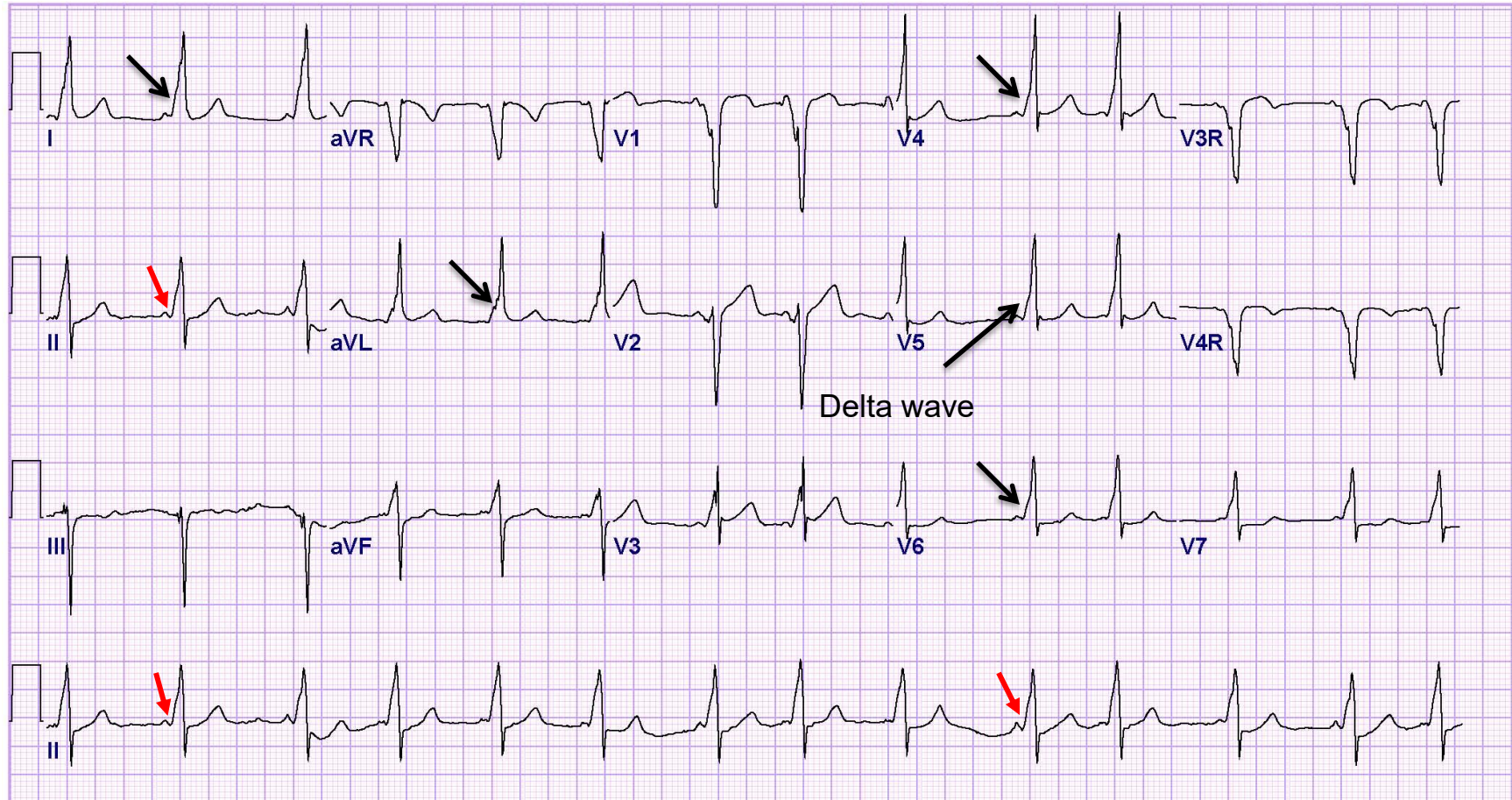
Arrhythmogenic Cardiomyopathy



LQRSV

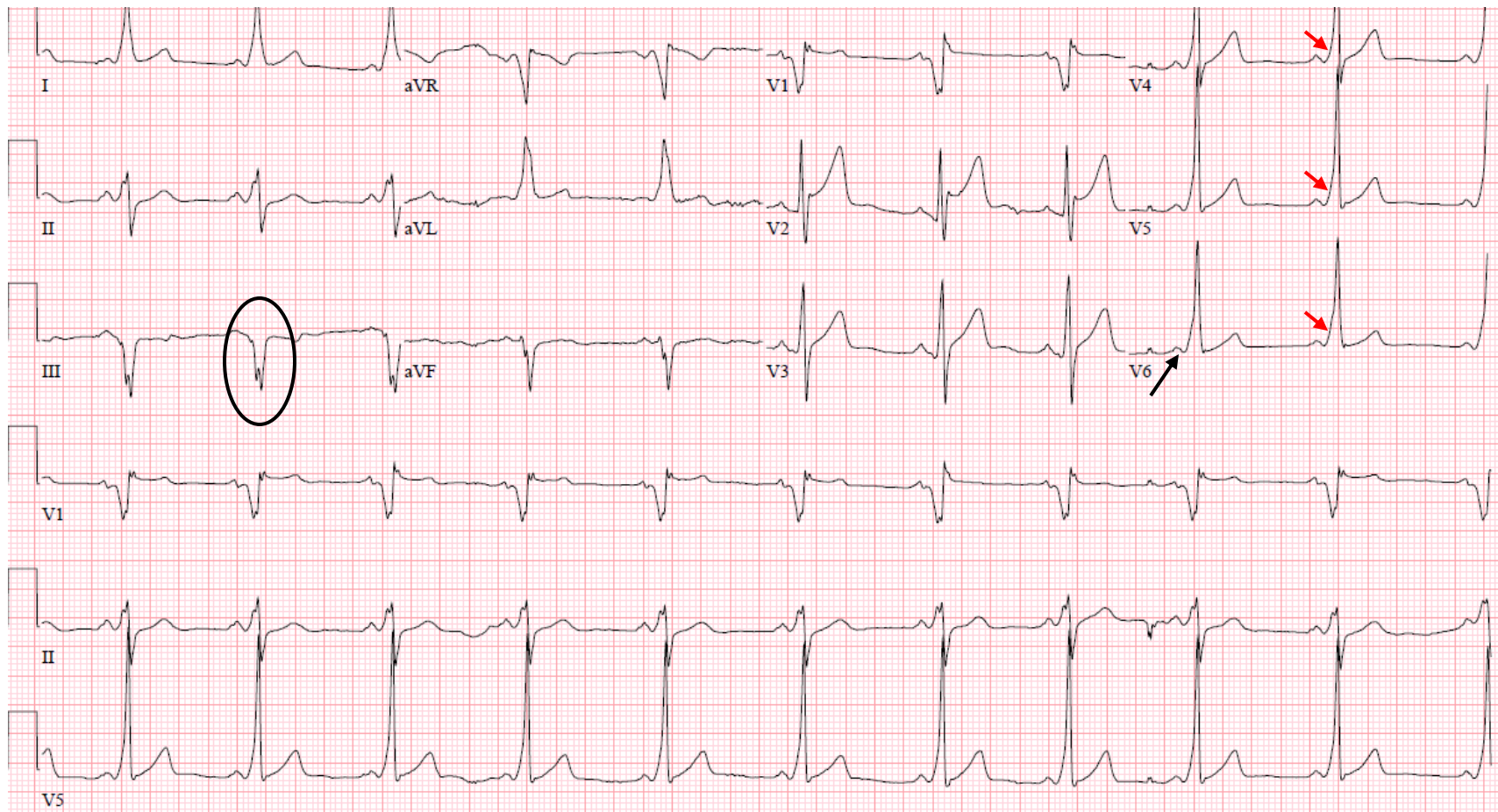


Pre-excitation / WPW



ECG demonstrating the classic findings of Wolff-Parkinson-White pattern with a short PR interval (< 120 ms), delta wave (slurred QRS upstroke), and prolonged QRS (> 120 ms).

Ventricular Pre-excitation / Wolff Parkinson White



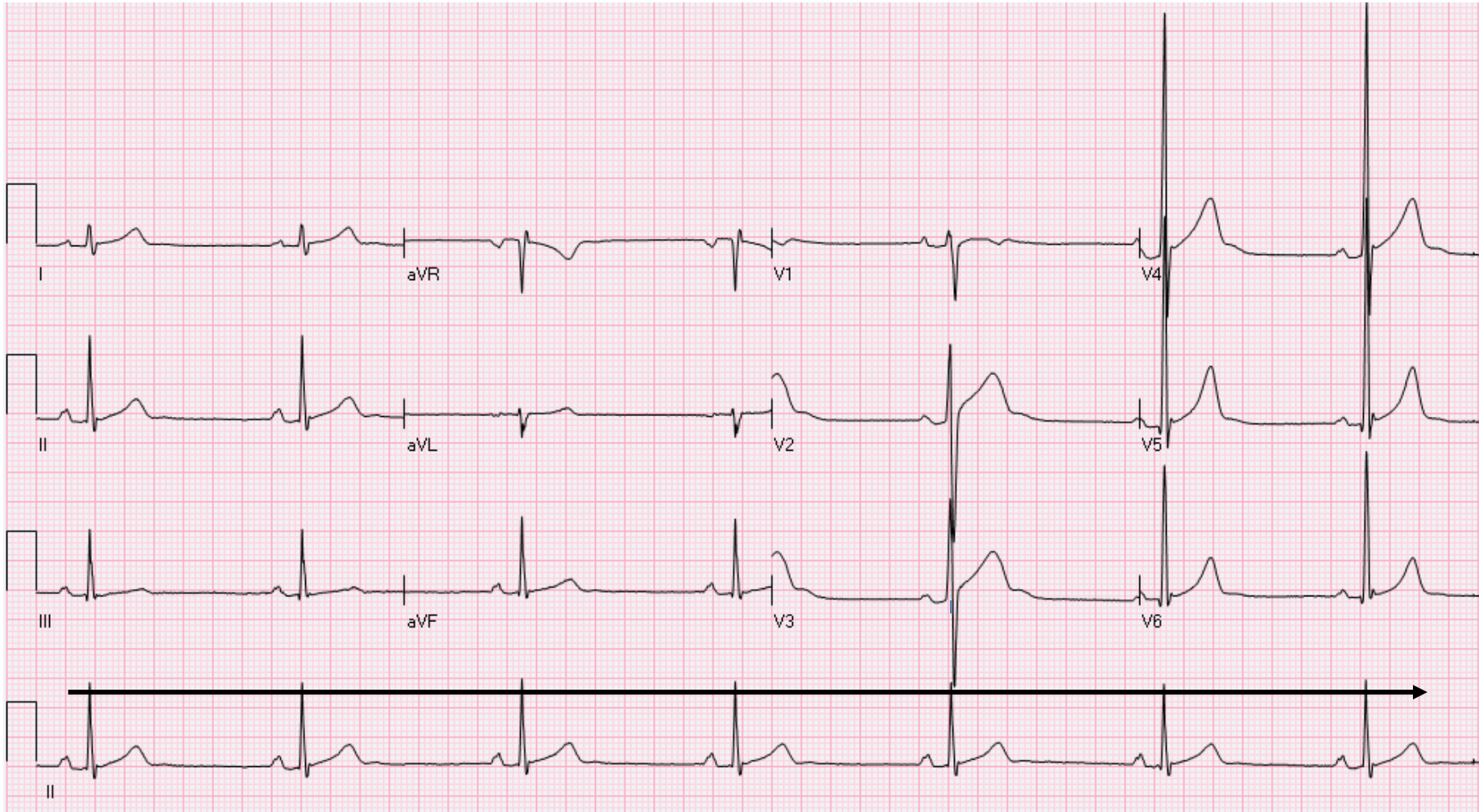
WPW classic findings:

- Short PR <120 ms
- Delta wave
- Wide QRS >120 ms

WPW additional findings:

- Large Q wave lead III
- Lack of Q wave in V6
- ST segment depression (not shown)

Step-4: ECG Interpretation in Athletes



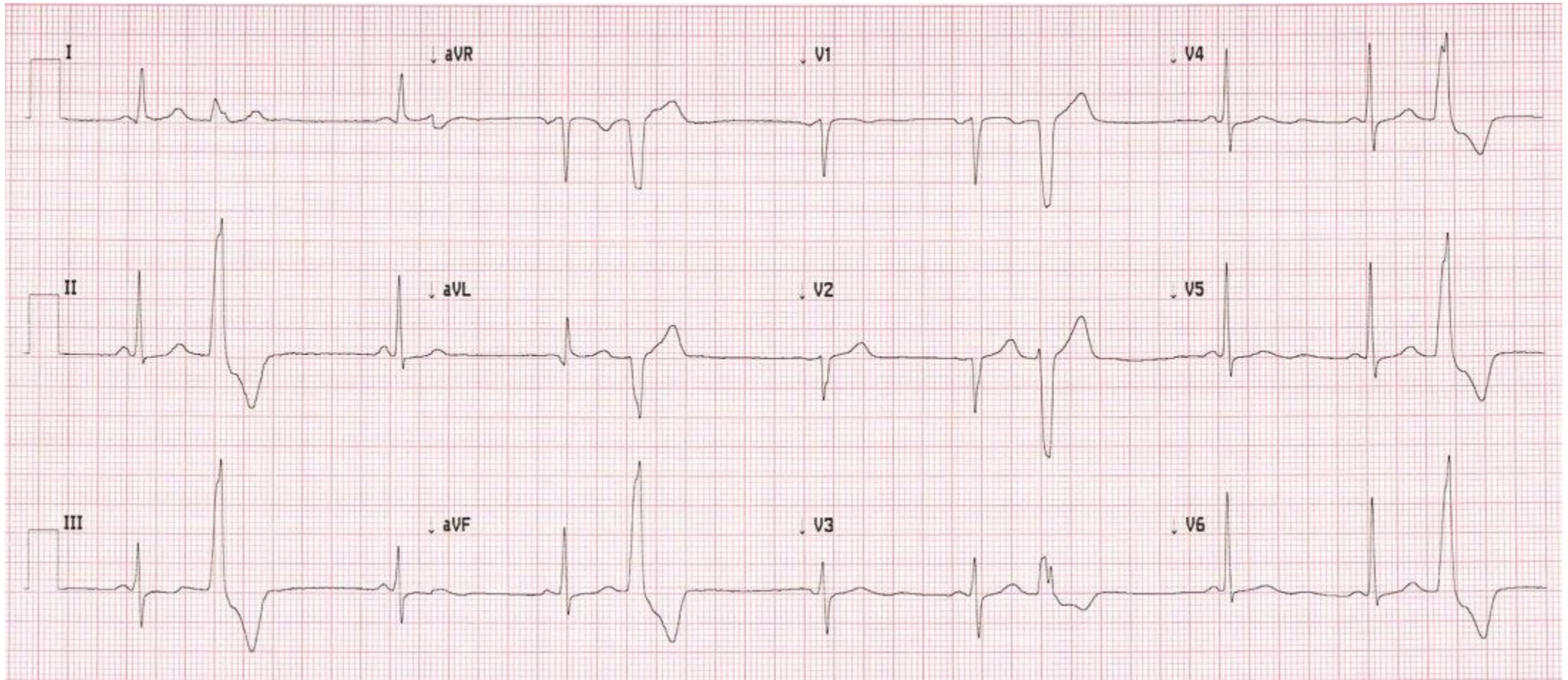
Where to look?

4. Rhythm strip

What to look for?

QRS after every P wave; PVCs

Premature Ventricular Contractions (PVCs)



How to evaluate premature ventricular beats in the athlete: critical review and proposal of a diagnostic algorithm

Domenico Corrado,¹ Jonathan A Drezner,² Flavio D'Ascenzi,³ Alessandro Zorzi¹

BJSM 2019

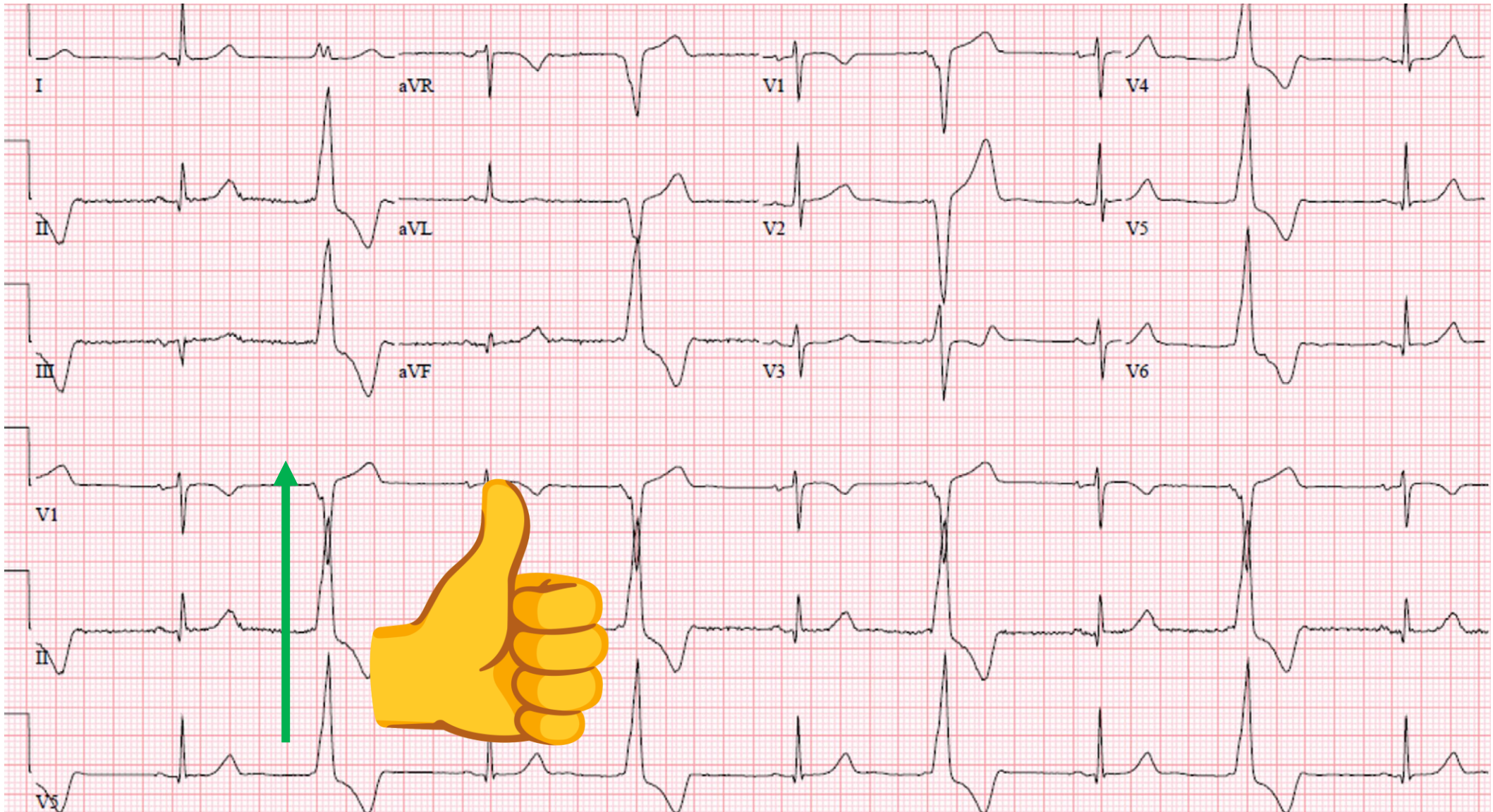
Table 3 Classification and risk stratification of premature ventricular beats in the athlete

	Common	Uncommon
PVB characteristics		
Ectopic QRS morphology	LBBB/inferior axis, typical RBBB and narrow QRS (<130 ms)	LBBB/intermediate or superior axis, atypical RBBB and wide QRS (≥130 ms)
Response to exercise testing	Decrease/suppression	Persistence/increase
Complexity of PVBs	Isolated, monomorphic	Repetitive‡, polymorphic

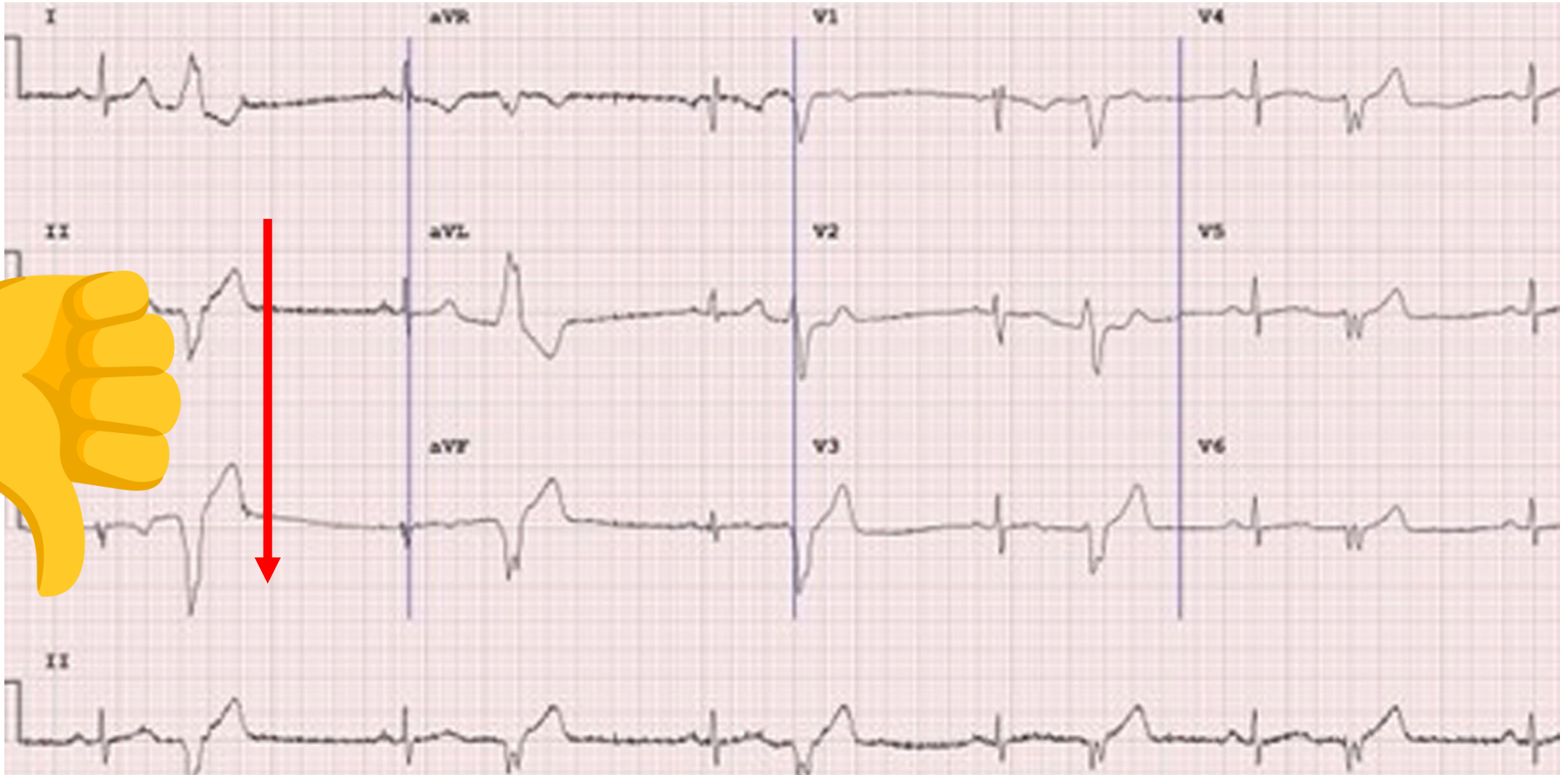
Table 2 Morphology and characteristics of premature ventricular beats that may be encountered in clinical practice

Pattern	QRS morphology	Origin of ectopic beat	Comment
Common patterns in athletes			
Infundibular	LBBB with late precordial transition (R/S=1 after V3) and inferior axis.	Right ventricular outflow tract.	Usually benign.
	LBBB and inferior axis but with small R-waves in V1 and early precordial transition (R/S=1 by V2 or V3).	Left ventricular outflow tract.	Usually benign.
Fascicular	Typical RBBB with superior axis and QRS <130 ms.	Left posterior fascicle of the left bundle branch.	Usually benign.
	Typical RBBB with inferior axis and QRS <130 ms.	Left anterior fascicle of the left bundle branch.	Usually benign.
Uncommon patterns in athletes			
	Atypical RBBB and QRS ≥130 ms.	Mitral valve annulus, papillary muscles or left ventricle.	May be associated with myocardial disease.
	LBBB with superior or intermediate axis.	Right ventricular free wall or interventricular septum.	May be associated with myocardial disease.

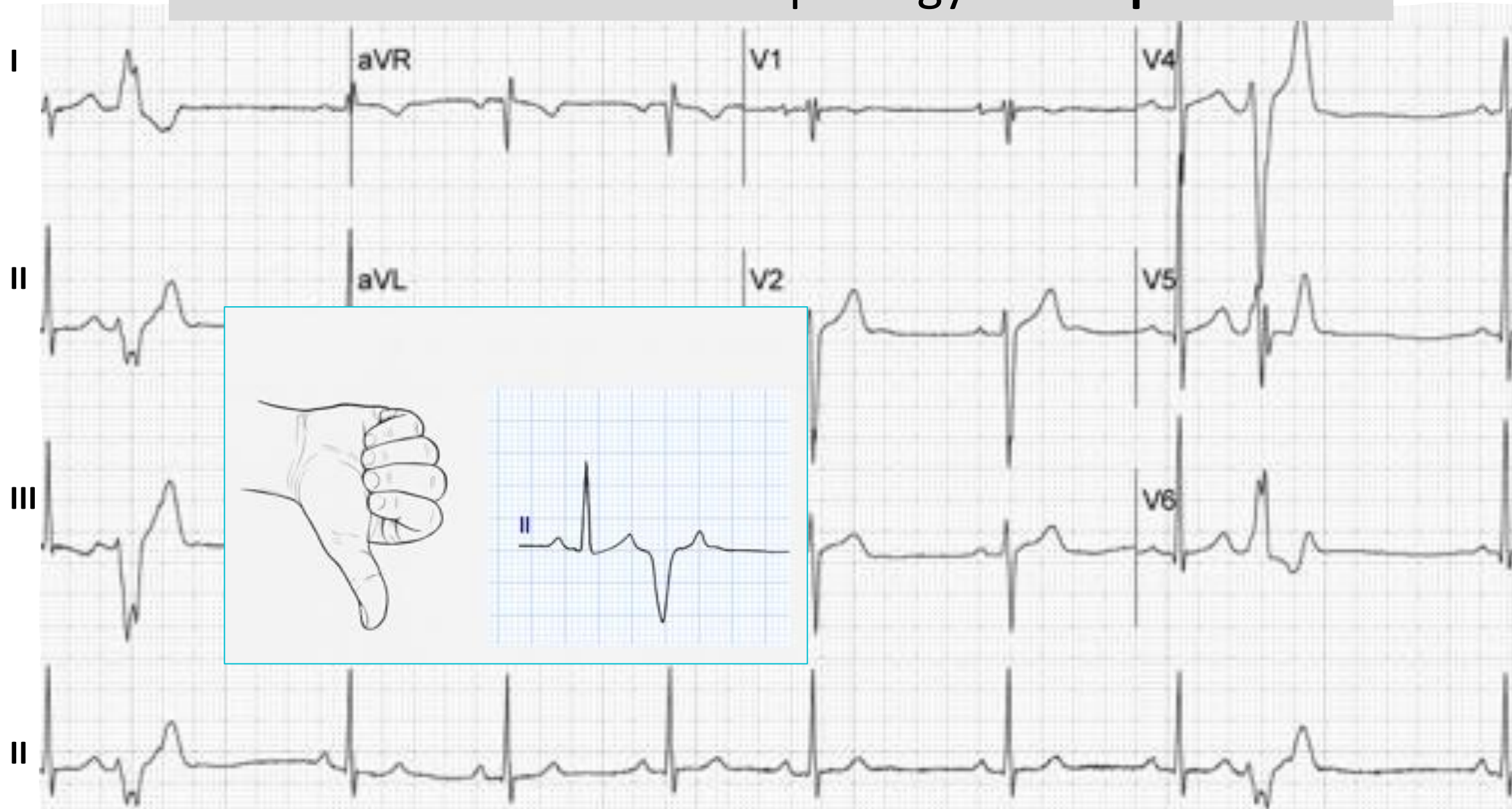
PVCs: LBBB with inferior axis (RVOT)



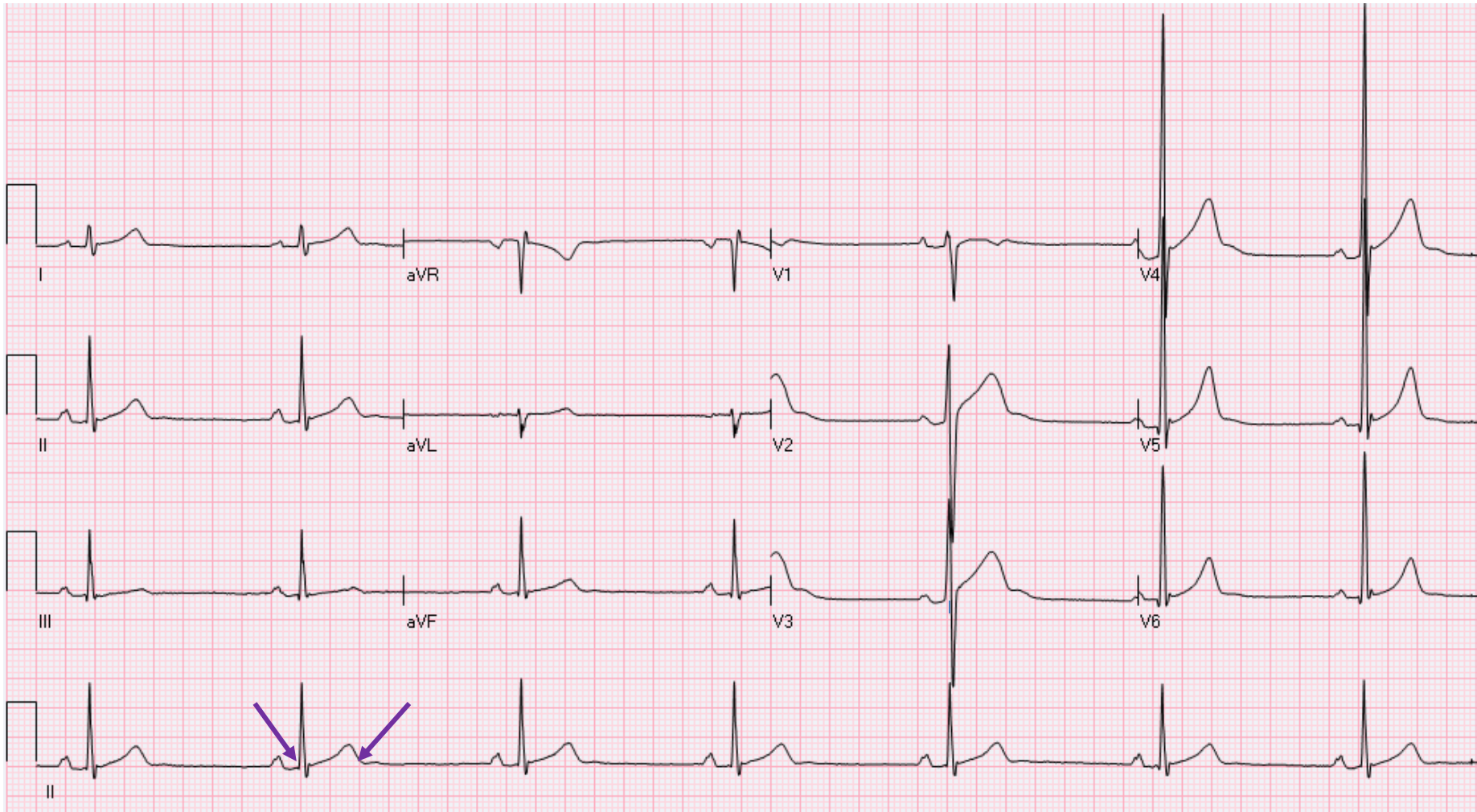
PVCs: LBBB with superior axis (RV free wall?)



PVCs with broad LBBB morphology and superior axis



Step-5: ECG Interpretation in Athletes



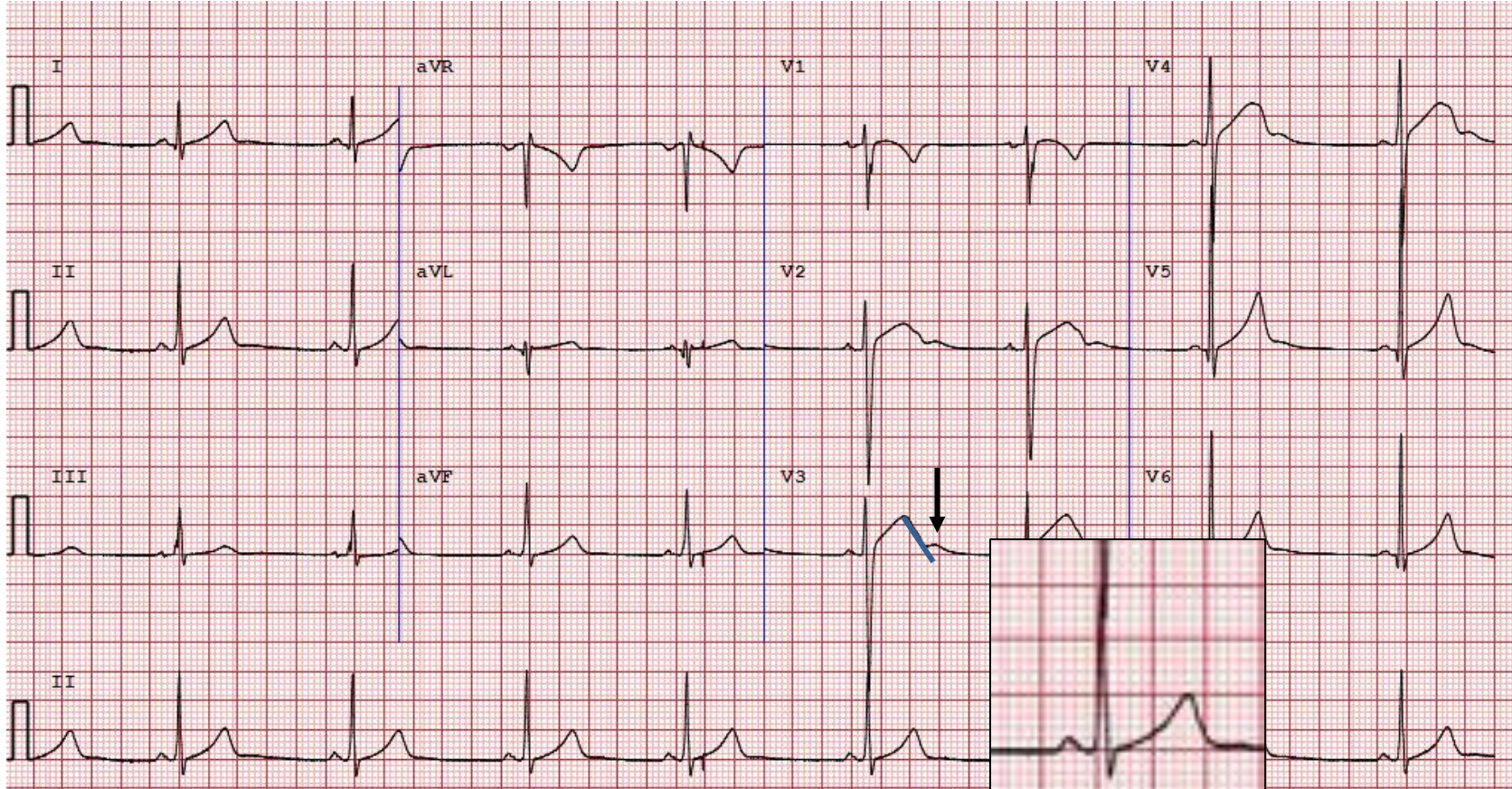
Where to look?

5. QT interval – lead II or V5

What to look for?

QTc \geq 470 ms males or \geq 480 ms females

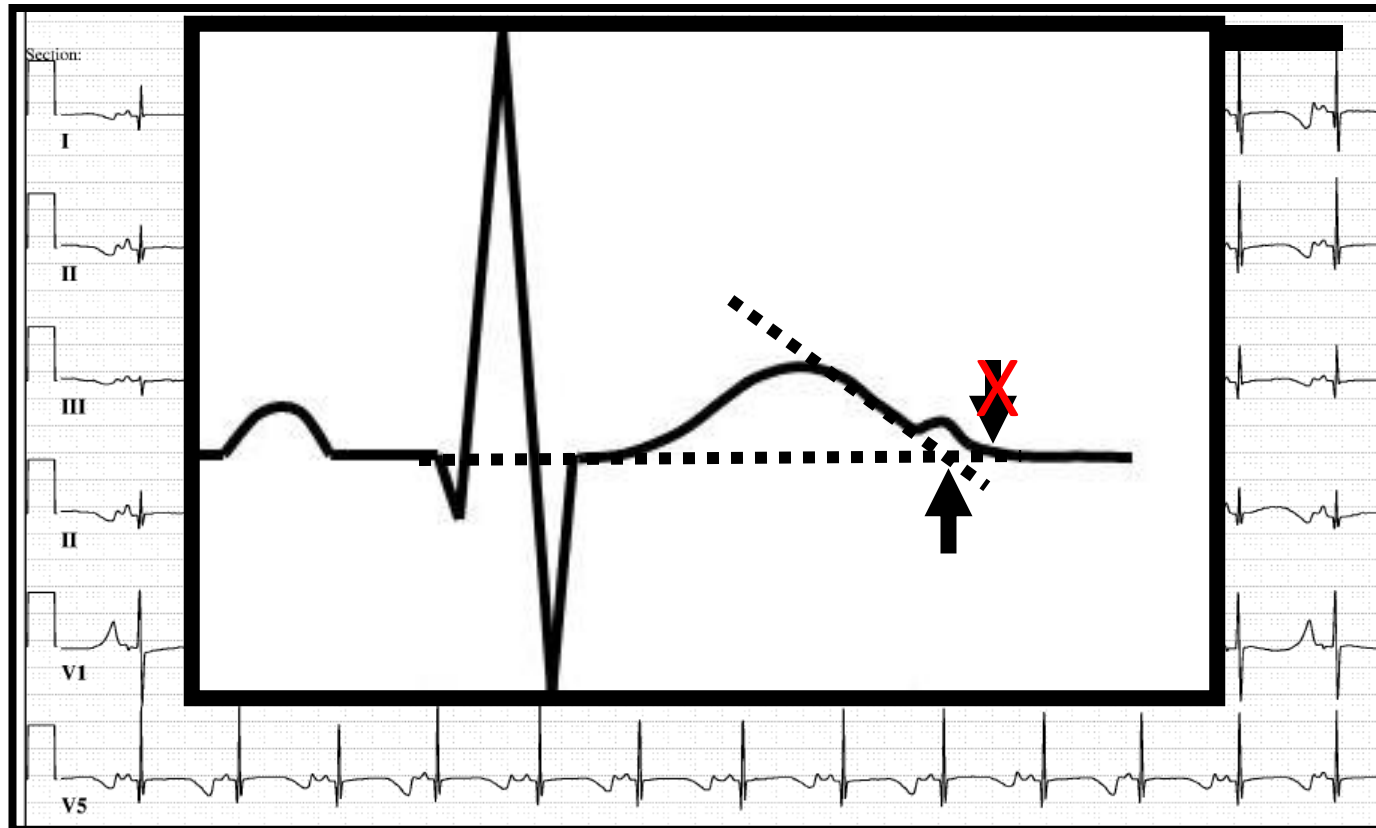
Long QT Syndrome?



Normal ECG

- QTc is normal
- Don't include the U wave in anterior precordial leads!
 - "Teach-the-tangent" or "Avoid-the-tail" method for manual measurement of the QT interval

*No further
evaluation
needed*

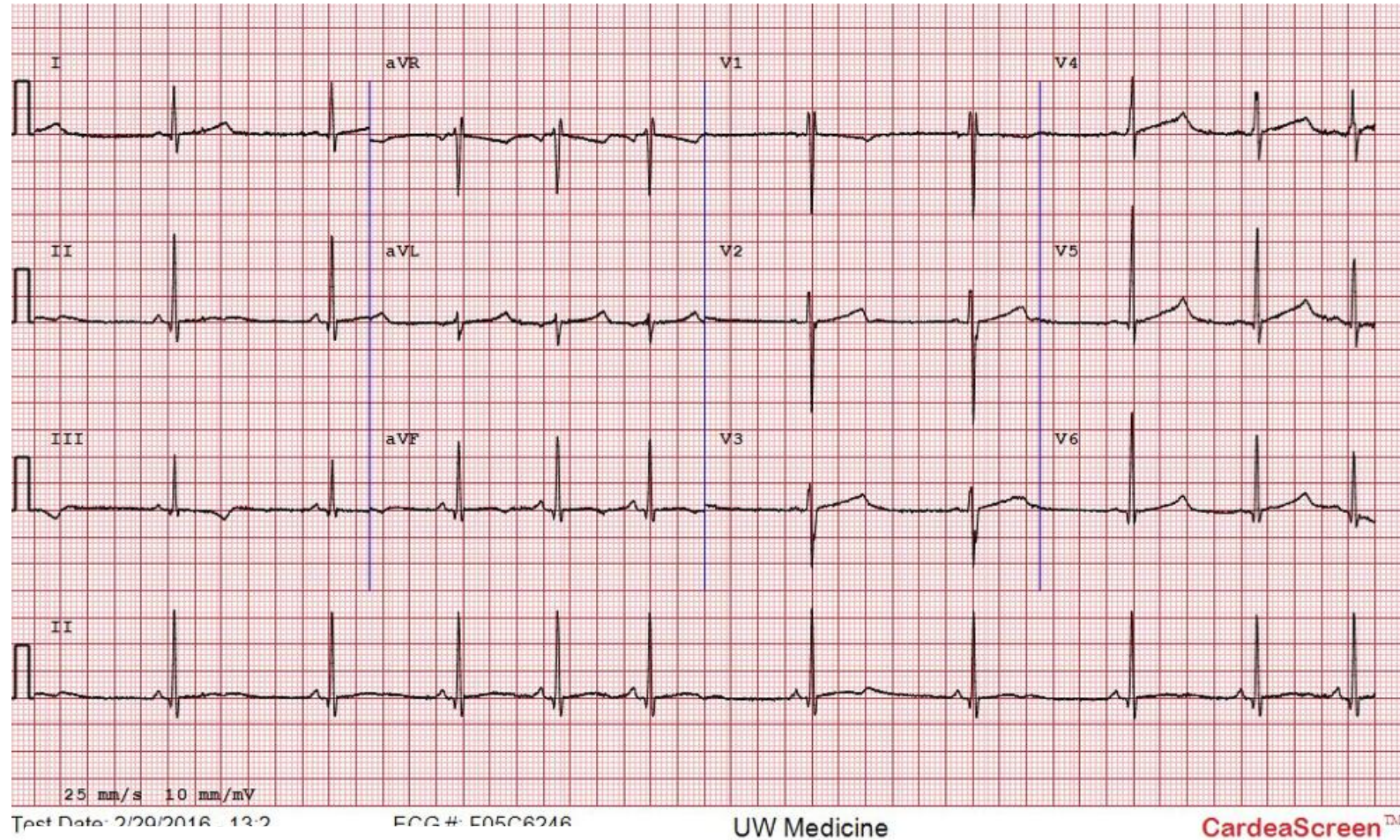


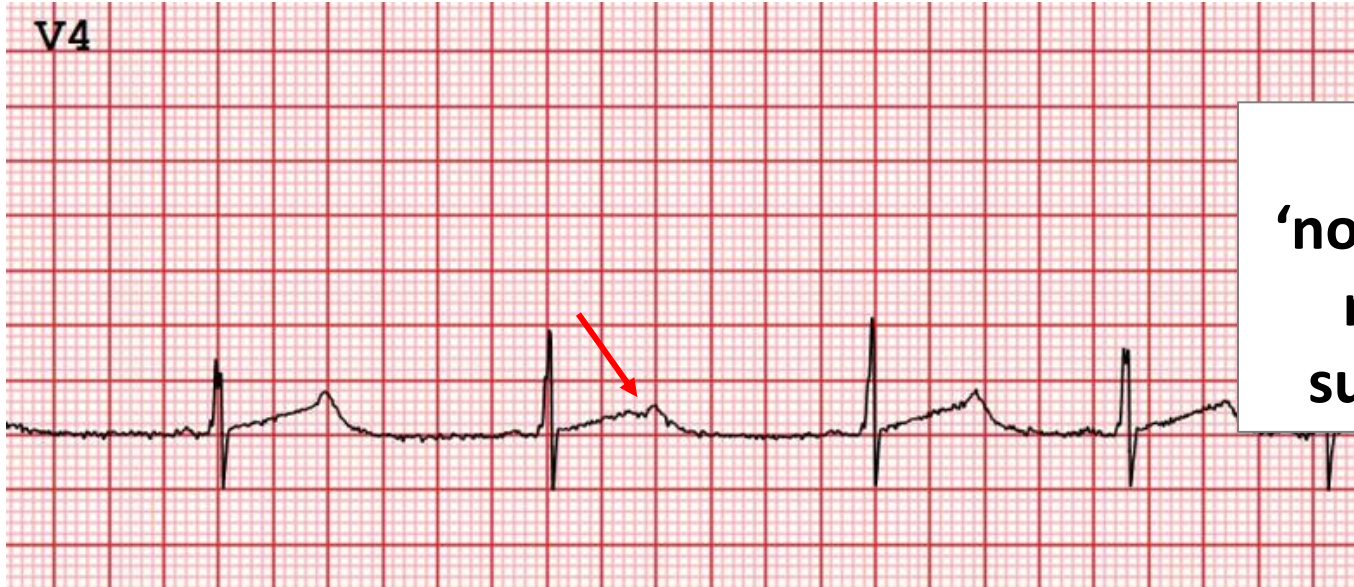This figure illustrates the “Teach-the-Tangent” or “Avoid-the-Tail” method for manual measurement of the QT interval. A straight line is drawn on the downslope of the T wave to the point of intersection with the isoelectric line. The U wave is not included.

- **Bazett’s formula:** $QTc = QT/\sqrt{RR}$
 - Inaccurate at heart rates < 50 or > 90 bpm
 - QT interval will equal the QTc at a heart rate of 60 bpm
- Use **lead II or V5** where the end of the T wave is readily delineated
- Abnormal QTc is considered ≥ 470 ms in males and ≥ 480 ms in females

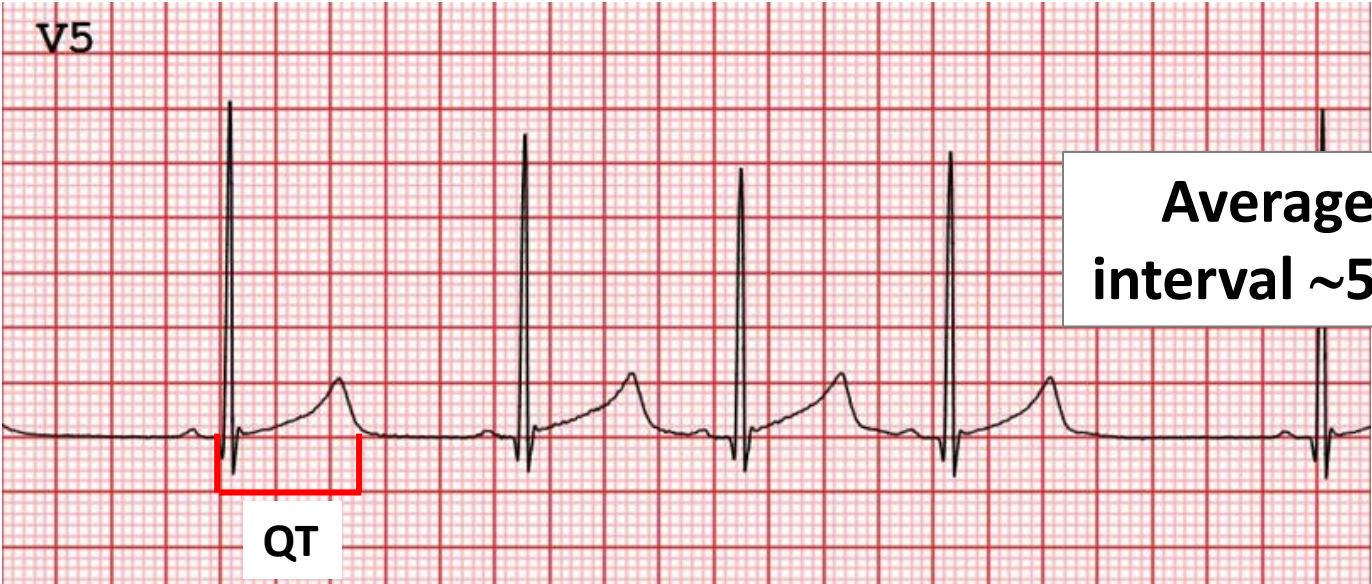Normal or Abnormal?

14 yo Caucasian female elite soccer player





**Abnormal
'notched' T Wave
morphology
suggests LQT-2**



**Average QT
interval ~500 ms**

QT



AUSTRALASIAN COLLEGE OF
SPORT AND EXERCISE PHYSICIANS

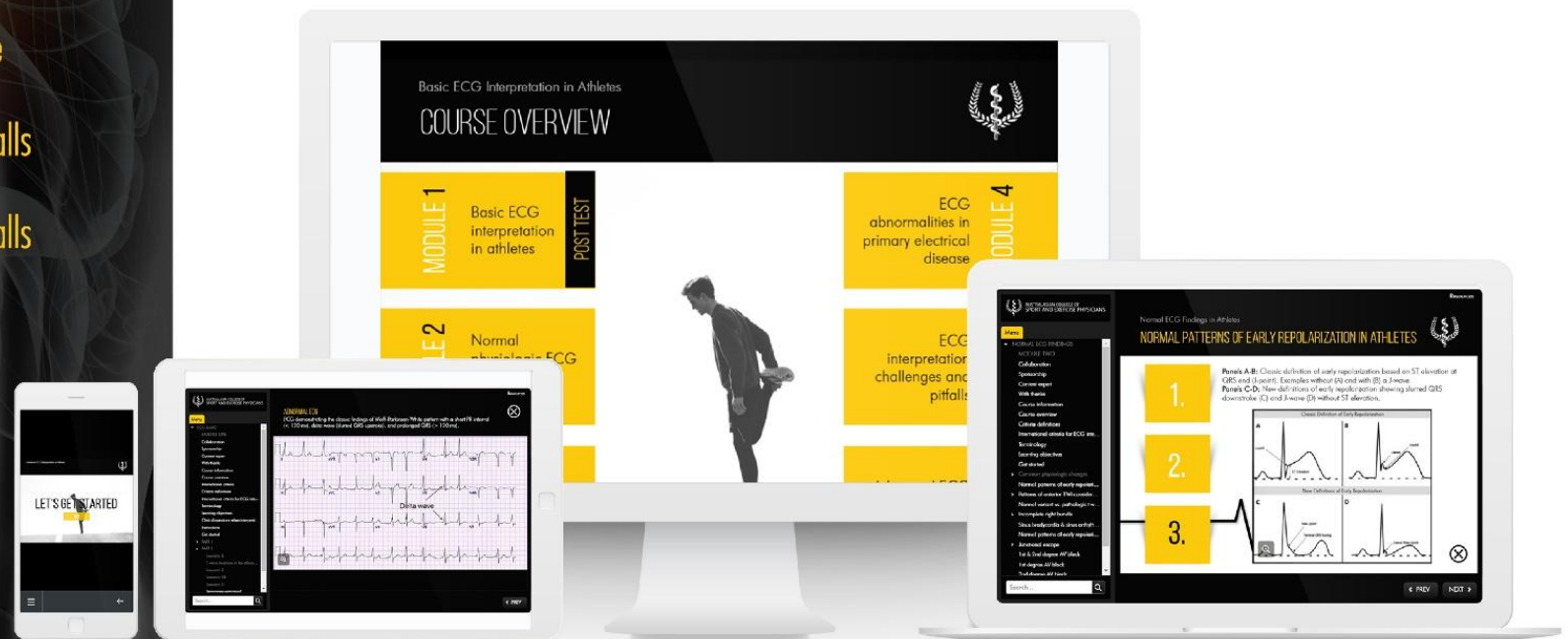UW Medicine
Center For Sports Cardiology

1. Basic ECG Interpretation in Athletes
2. Normal ECG Findings in Athletes
3. ECG Abnormalities in Cardiomyopathy
4. ECG Abnormalities in Primary Electrical Disease
5. ECG Interpretation Challenges & Common Pitfalls
6. ECG Interpretation Challenges & Common Pitfalls

To access the free ECG training modules, go to:
www.uwsportscardiology.org/E-Academy

ECG INTERPRETATION IN ATHLETES

The Center for Sports Cardiology at the University of Washington in collaboration with the Australasian College of Sport and Exercise Physicians are extremely excited to offer open access worldwide to a new collection of six online ECG training modules. These are based on the 'International criteria' and the latest consensus recommendations for ECG interpretation in athletes.



www.uwsportscardiology.org/e-academy/

ECG INTERPRETATION IN ATHLETES

uwsportscardiology.org/e-academy



MODULE 1

Basic ECG interpretation in athletes

POST TEST

MODULE 2

Normal physiologic ECG findings in athletes

MODULE 3

ECG abnormalities in cardiomyopathy



ECG abnormalities in primary electrical disease

MODULE 4

ECG interpretation challenges and pitfalls

MODULE 5

Advanced ECG interpretation in athletes

MODULE 6

POST TEST



INTERNATIONAL SUMMIT ON
ECG INTERPRETATION IN ATHLETES

September 25-26, 2025

www.ECGSummit.org

2025 International Criteria for ECG Interpretation in Athletes

DRAFT

NO FURTHER EVALUATION

ECG findings that are training-related or variants not generally associated with conditions at risk for SCD

- Increased QRS voltage for LVH or RVH
- Sinus bradycardia ≥ 30 bpm
- Sinus arrhythmia
- 1° AV block PR interval < 400 ms
- Mobitz Type I 2° AV block
- Ectopic atrial or junctional rhythm
- Premature atrial contractions
- Incomplete or complete RBBB < 140 ms
- Non-specific IVCD < 140 ms
- Left or right atrial enlargement
- Early repolarization/ST segment elevation
- Juvenile TWI V1-V3 (< 16 years)
- Male athlete repolarization variant (J-point and convex ST elevation followed by TWI confined to V1-V4)

MAY REQUIRE EVALUATION

ECG findings have an unclear relationship with conditions at risk for SCD

- Female athlete TWI V1-V3 (≥ 16 years)
- Inferior TWI
- Low QRS voltage
- 1 PVC with inferior axis
- Axis deviation

FURTHER EVALUATION

ECG findings that are associated with conditions at risk for SCD

- Lateral, inferolateral, or anterolateral TWI
- Anterior TWI (excluding green and yellow box patterns)
- ST segment depression
- Pathologic Q waves
- Complete LBBB
- Complete RBBB or IVCD ≥ 140 ms
- ≥ 2 PVCs of any morphology
- 1 PVC with non-inferior axis or short-coupling
- Ventricular pre-excitation
- Prolonged QTc interval
- Brugada Type 1 pattern
- PR interval ≥ 400 ms
- Mobitz Type II 2° AV block
- 3° AV block
- Atrial or ventricular tachyarrhythmias

Are there ≥ 2 'yellow box' findings or concerning personal or family history?

No

Yes

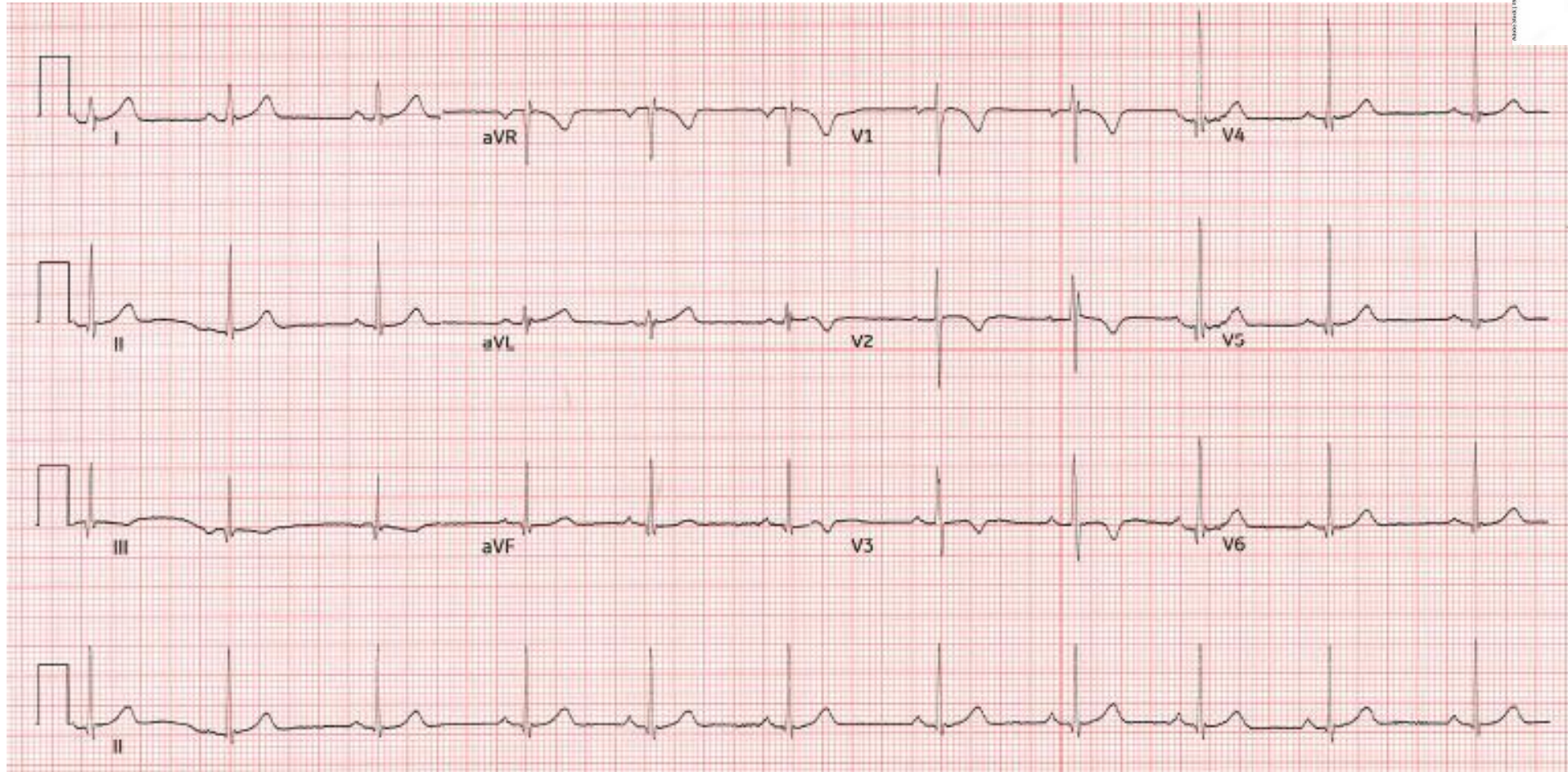
No further evaluation required

in asymptomatic athletes with no family history of inherited cardiac disease or SCD

Further evaluation required

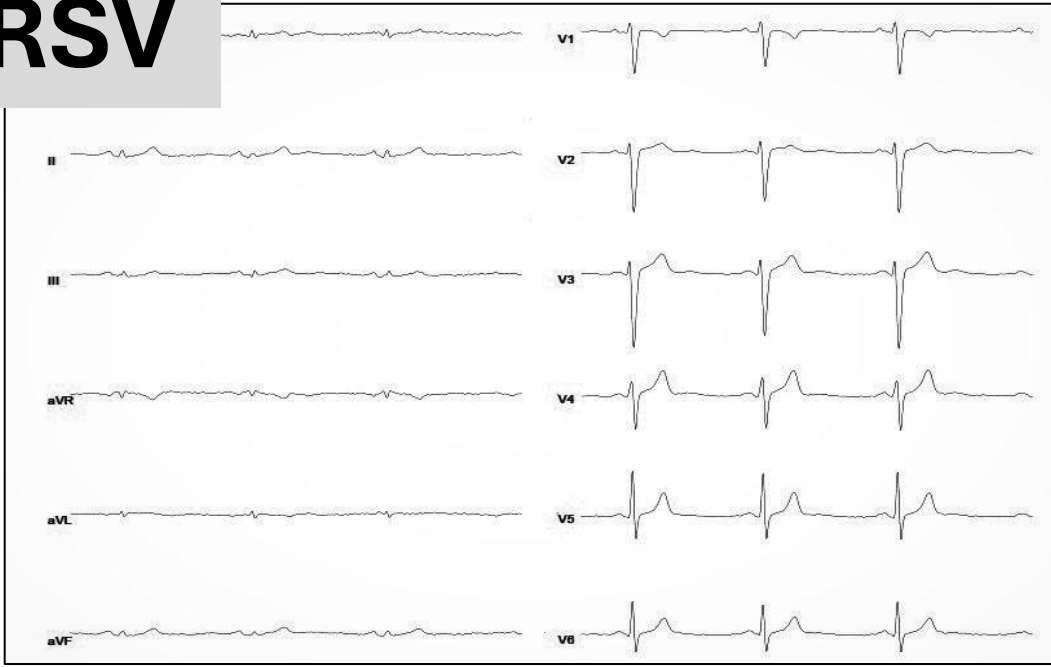
to investigate for pathologic cardiovascular disorders associated with SCD in athletes

18 y.o. F Elite Football Player – Screening ECG (Echo / CMR normal)

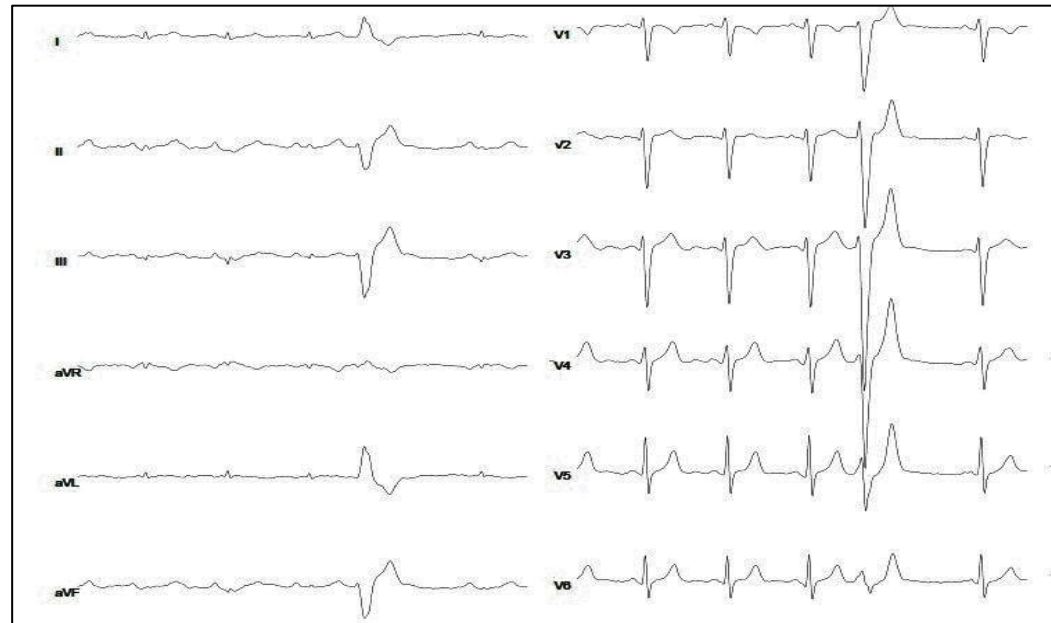


LQ RSV

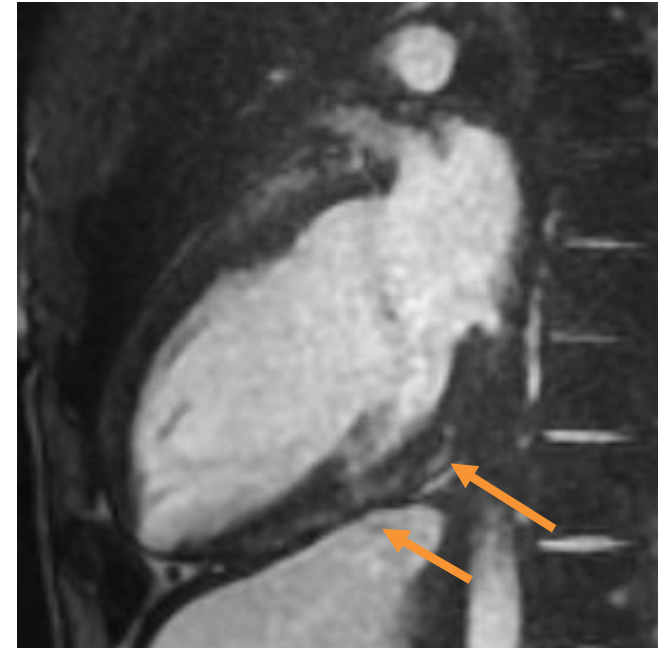
A



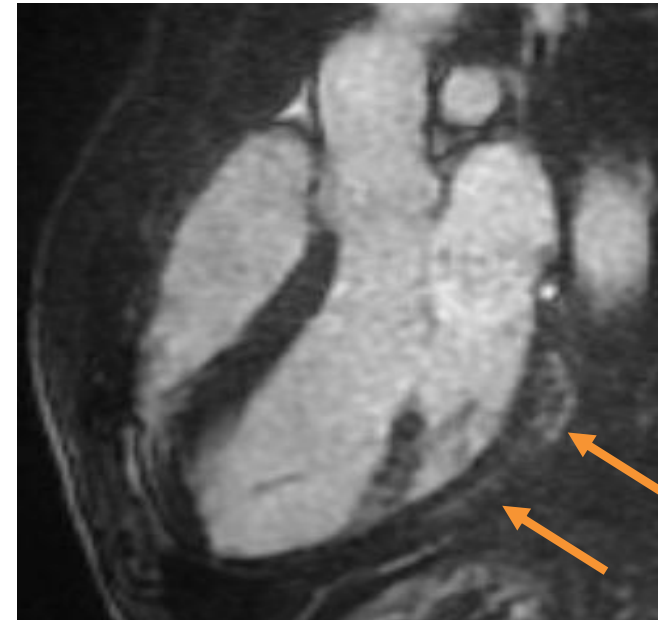
B



C



D



ANNO 2015 12/15/2015



2025 International Criteria for ECG Interpretation in Athletes

DRAFT

NO FURTHER EVALUATION

ECG findings that are training-related or variants not generally associated with conditions at risk for SCD

- Increased QRS voltage for LVH or RVH
- Sinus bradycardia ≥ 30 bpm
- Sinus arrhythmia
- 1° AV block PR interval < 400 ms
- Mobitz Type I 2° AV block
- Ectopic atrial or junctional rhythm
- Premature atrial contractions
- Incomplete or complete RBBB < 140 ms
- Non-specific IVCD < 140 ms
- Left or right atrial enlargement
- Early repolarization/ST segment elevation
- Juvenile TWI V1-V3 (< 16 years)
- Male athlete repolarization variant (J-point and convex ST elevation followed by TWI confined to V1-V4)

MAY REQUIRE EVALUATION

ECG findings have an unclear relationship with conditions at risk for SCD

- Female athlete TWI V1-V3 (≥ 16 years)
- Inferior TWI
- Low QRS voltage
- 1 PVC with inferior axis
- Axis deviation

FURTHER EVALUATION

ECG findings that are associated with conditions at risk for SCD

- Lateral, inferolateral, or anterolateral TWI
- Anterior TWI (excluding green and yellow box patterns)
- ST segment depression
- Pathologic Q waves
- Complete LBBB
- Complete RBBB or IVCD ≥ 140 ms
- ≥ 2 PVCs of any morphology
- 1 PVC with non-inferior axis or short-coupling
- Ventricular pre-excitation
- Prolonged QTc interval
- Brugada Type 1 pattern
- PR interval ≥ 400 ms
- Mobitz Type II 2° AV block
- 3° AV block
- Atrial or ventricular tachyarrhythmias

Are there ≥ 2 'yellow box' findings or concerning personal or family history?

No

Yes

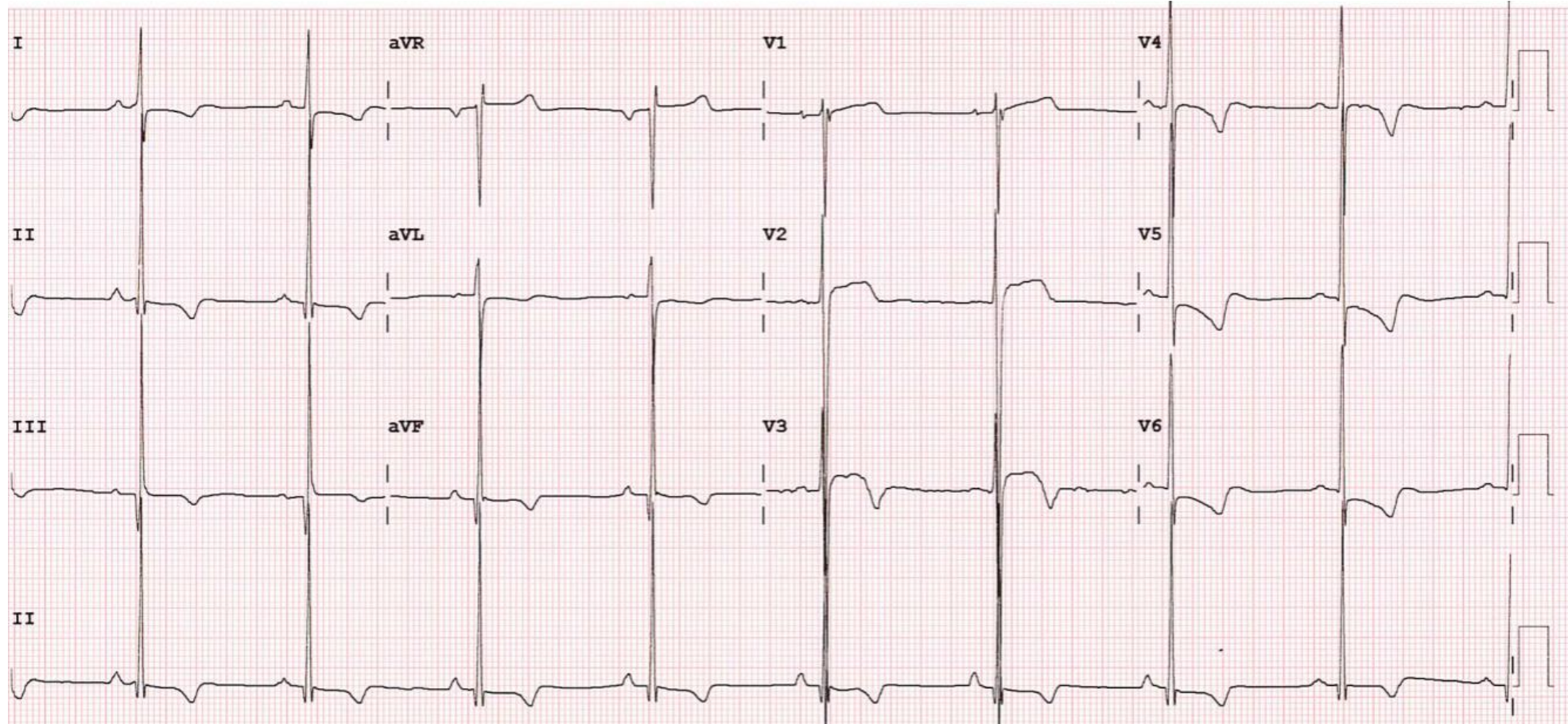
No further evaluation required

in asymptomatic athletes with no family history of inherited cardiac disease or SCD

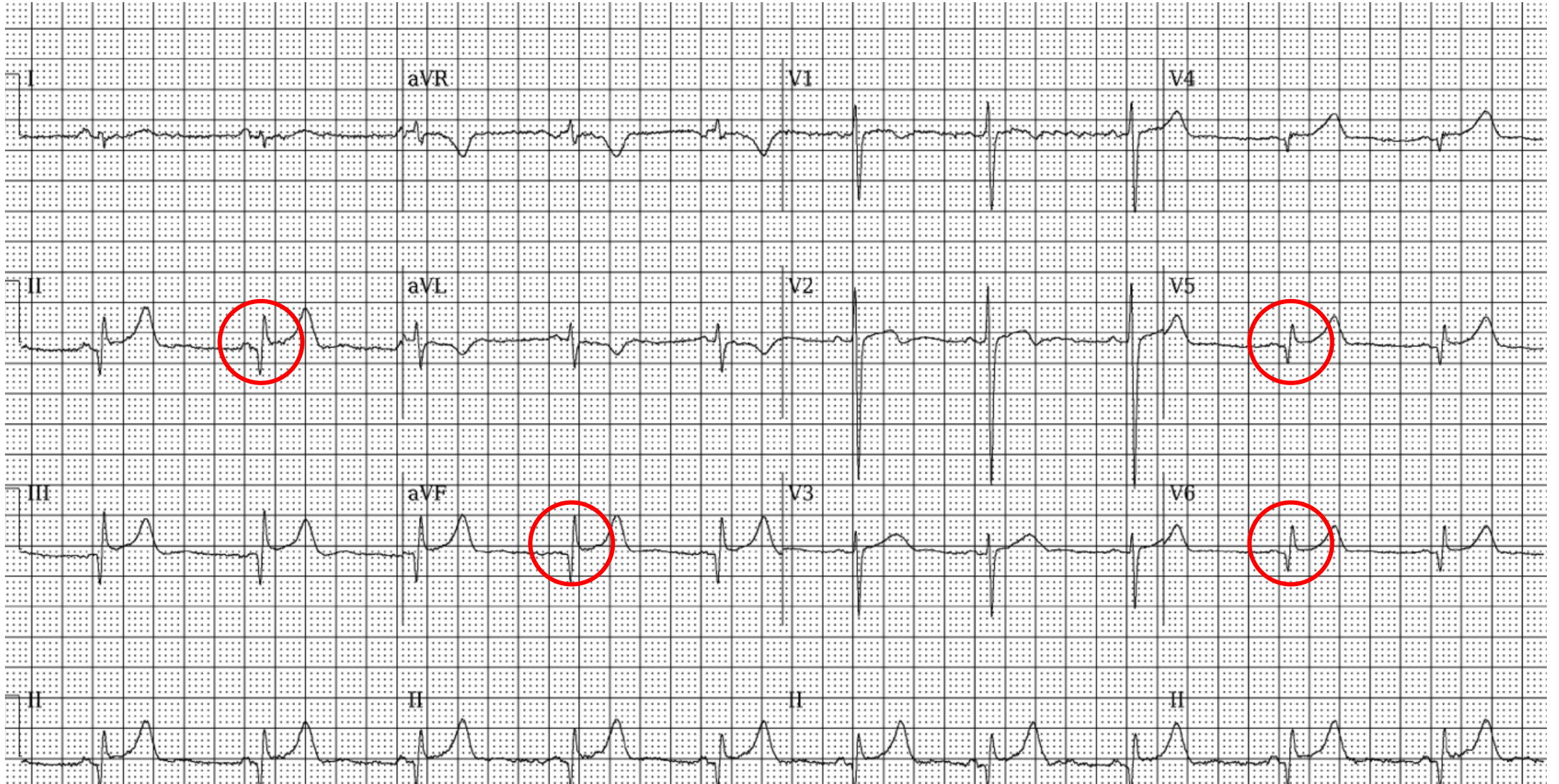
Further evaluation required

to investigate for pathologic cardiovascular disorders associated with SCD in athletes

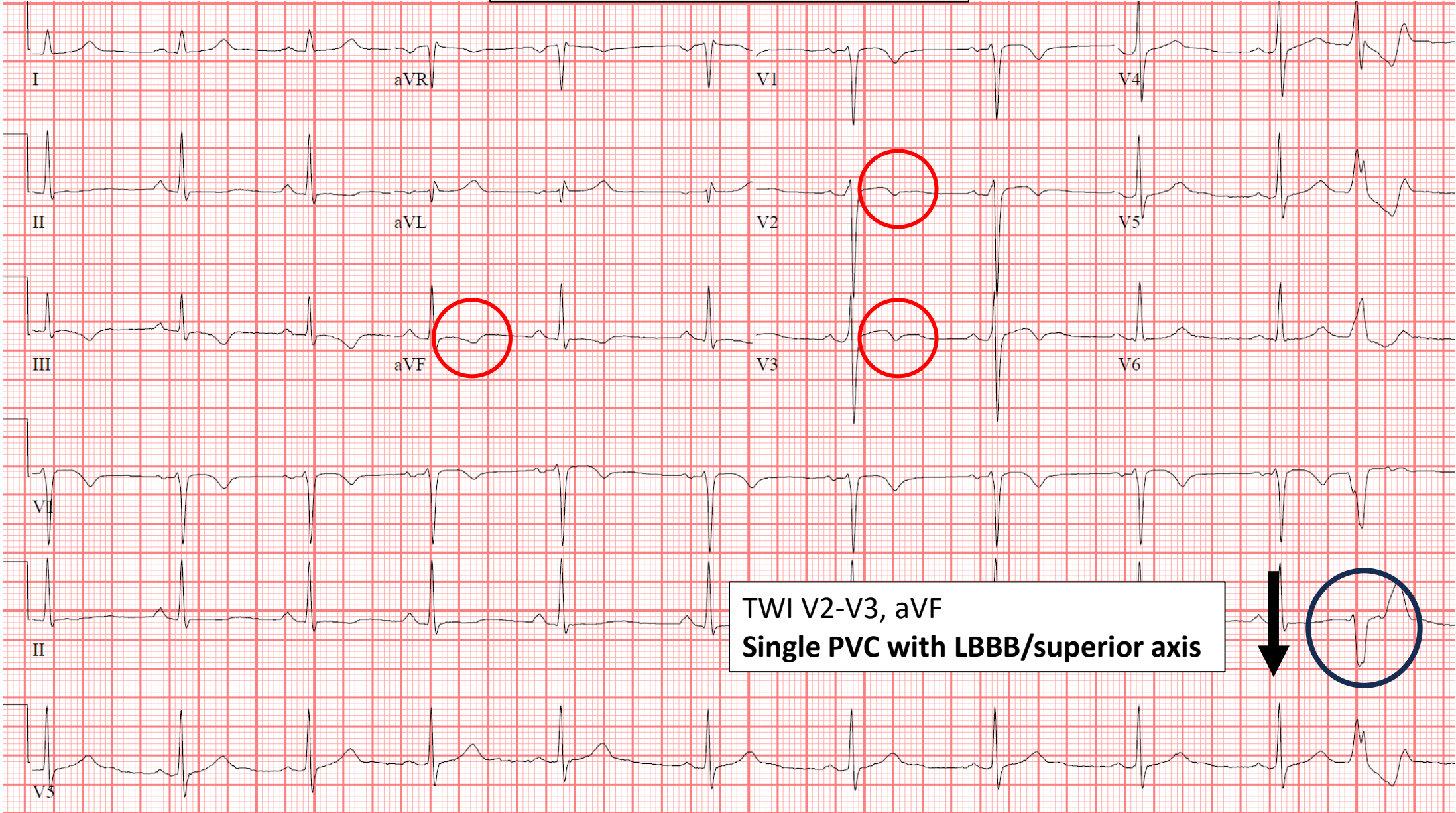
Inferolateral TWI and ST depression



Pathological Q waves



23 yo M with ARVC





Comparing the 2017 and 2025 International Criteria for ECG interpretation in athletes: Performance in over 32,000 young individuals

M. Jake Petersen MD

UNIVERSITY *of* WASHINGTON



RESULTS – Total Abnormal Rate

Total Abnormal Rate 2017	Total Abnormal Rate 2025	Absolute Reduction	95% Confidence Interval	P-value
2.1%	1.6%	- 0.5%	- 0.35% to -0.65%	<0.0001

IC25 resulted in a 24% relative reduction in the abnormal rate compared to IC17



ORCCA

OUTCOMES REGISTRY FOR
CARDIAC CONDITIONS IN ATHLETES



DO YOU KNOW A HIGH SCHOOL, COLLEGE,
SEMI-PROFESSIONAL, PROFESSIONAL, ELITE OR
NATIONAL ATHLETE DIAGNOSED WITH A
CARDIAC CONDITION?

**HELP US LEARN MORE.
REGISTER WITH ORCCA.**



ORCCASTUDY.ORG

SUMMARY



- **Updates to the International Criteria** followed a rigorous scientific process aimed to carefully improve detection of conditions at risk of SCA and lower the false-positive rate
- **Key changes:**

cRBBB
Atrial enlargement
Male athlete repol variant

Female athlete TWI V1-V3
Inferior TWI
LQRSV

PVC with superior axis

TAKE HOME POINTS



1. Follow the **International Criteria** and consider “**5-steps**” for accurate ECG interpretation and the secondary evaluation of ECG abnormalities
2. **Lateral or inferolateral TWI** requires a contrast-enhanced cardiac MRI
3. **Serial cardiac imaging** is required for athletes with markedly abnormal ECGs and normal cardiac imaging
4. **ECG interpretation is a core skill** for sports medicine physicians



CENTER FOR
SPORTS CARDIOLOGY

UW Medicine

Thank You

jdrezner@uw.edu